This is a digital copy of a book that was preserved for generations on library shelves before it was carefully scanned by Google as part of a project to make the world's books discoverable online.

It has survived long enough for the copyright to expire and the book to enter the public domain. A public domain book is one that was never subject to copyright or whose legal copyright term has expired. Whether a book is in the public domain may vary country to country. Public domain books are our gateways to the past, representing a wealth of history, culture and knowledge that's often difficult to discover.

Marks, notations and other marginalia present in the original volume will appear in this file - a reminder of this book's long journey from the publisher to a library and finally to you.

Usage guidelines

Google is proud to partner with libraries to digitize public domain materials and make them widely accessible. Public domain books belong to the public and we are merely their custodians. Nevertheless, this work is expensive, so in order to keep providing this resource, we have taken steps to prevent abuse by commercial parties, including placing technical restrictions on automated querying.

We also ask that you:

+ *Make non-commercial use of the files* We designed Google Book Search for use by individuals, and we request that you use these files for personal, non-commercial purposes.

+ *Refrain from automated querying* Do not send automated queries of any sort to Google's system: If you are conducting research on machine translation, optical character recognition or other areas where access to a large amount of text is helpful, please contact us. We encourage the use of public domain materials for these purposes and may be able to help.

+ *Maintain attribution* The Google "watermark" you see on each file is essential for informing people about this project and helping them find additional materials through Google Book Search. Please do not remove it.

+ *Keep it legal* Whatever your use, remember that you are responsible for ensuring that what you are doing is legal. Do not assume that just because we believe a book is in the public domain for users in the United States, that the work is also in the public domain for users in other countries. Whether a book is still in copyright varies from country to country, and we can't offer guidance on whether any specific use of any specific book is allowed. Please do not assume that a book's appearance in Google Book Search means it can be used in any manner anywhere in the world. Copyright infringement liability can be quite severe.

About Google Book Search

Google's mission is to organize the world's information and to make it universally accessible and useful. Google Book Search helps readers discover the world's books while helping authors and publishers reach new audiences. You can search through the full text of this book on the web at `http://books.google.com/`

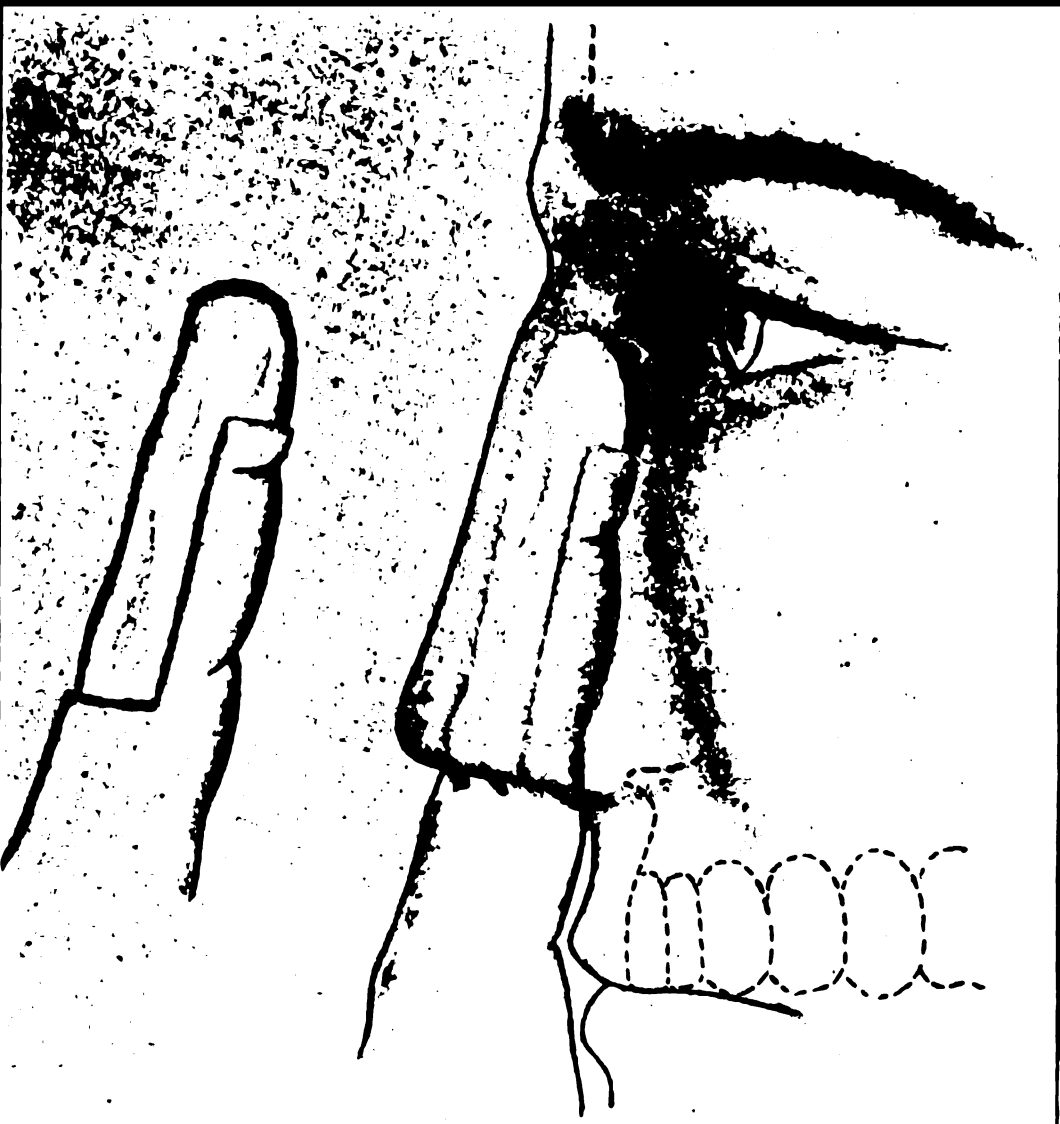

Transactions of the Meeting of the American Surgical ...

American Surgical Association

Digitized by Google

O'C

BOSTON
MEDICAL LIBRARY

IN THE
Francis A. Countway
Library of Medicine
BOSTON

Digitized by Google

Digitized by Google

Digitized by Google

Digitized by Google

Digitized by Google

TRANSACTIONS

OF THE

AMERICAN

SURGICAL ASSOCIATION.

VOLUME THE TWENTY-FIFTH.

EDITED BY

RICHARD H. HARTE, M.D.,
RECORDER OF THE ASSOCIATION.

PRINTED FOR THE ASSOCIATION

FOR SALE BY

WILLIAM J. DORNAN, PHILADELPHIA.

1907.

Digitized by Google

BOSTON MEDICAL
NOV 13 1907
LIBRARY.

6470

Copyright 1907, by RICHARD H. HARTE, M.D., Recorder of the Association.

CATALOGUED
NOV 15 1907

DORNAN, PRINTER,
701-709 ARCH STREET,
PHILADELPHIA.

Digitized by Google



CONTENTS.

Officers of the Association v
List of Presidents of the Association vii
Fellows of the Association ix
Honorary Fellows xviii
Report of the Committee on Necrology xxv

Address of the President. The Teaching of Surgery. By DUDLEY P. ALLEN, M.D. 1
On Spinal Anesthesia. By PROFESSOR KUSTER 15
Continuous Passive Hyperemia in Delayed Union of Fractures and in Hastening the Consolidation of Fractures. By JOHN B. ROBERTS, M.D. . . . 33
Resection of the Sound Femur in Gigantism and Asymmetry. A Proposition. By ROBERT W. JOHNSON, M.D. 40
A New Method of Rhinoplasty by Means of One of the Fingers. By J. M. T. FINNEY, M.D. 44
Treatment of the Posterior Capsule of the Gland in Thyroidectomy, Based on 375 Operations for Goitre. By C. H. MAYO, A.M., M.D. 52
The Results of Radical Operations for the Cure of Cancer of the Breast. By WILLIAM STEWART HALSTED, M.D. 61
The Results of Operations for Cancer of the Breast at the Massachusetts General Hospital from 1894 to 1904. By ROBERT B. GREENOUGH, M.D., CHANNING C. SIMMONS, M.D., and J. DELLINGER BARNEY, M.D. . . 80
Carcinoma of the Breast. A Study of the Pathological Conditions and their Relation to the Question of Recurrence. By ARTHUR TRACY CABOT, M.D. 103
Report on One Hundred Cases of Carcinoma of the Breast. By JOHN C. MUNRO, M.D. 112
Report of End Results Following Operations for Cancer of the Breast. By FREDERIC S. DENNIS, M.D. 116
End Results Following Operations for Carcinoma of the Breast. By WILLY MEYER, M.D. 126
End Results Following Operations for Carcinoma of the Breast. By LEWIS STEPHEN PILCHER, M.D. 133
End Results in Operation for Carcinoma of the Breast. By ALBERT VANDER VEER, M.D. 138
Final Results in 164 Cases of Carcinoma of the Breast Operated During the Past Fourteen Years at the Augustana Hospital. By A. J. OCHSNER, M.D. . 152

Digitized by Google

End Results Following Operations for Carcinoma of the Breast. By NATHAN JACOBSON, M.D. 166
The End Results in Operations for Carcinoma of the Breast. By JOHN CHADWICK OLIVER, M.D. 174
End Results in Operations for Cancer of the Breast. By A. F. JONAS . . 180
Very Late Recurrences After Operation for Carcinoma of the Breast. By JOSEPH RANSOHOFF, M.D., F.R.C.S. 187
Clinical Experience with the Law of Accelerating Risk in Cancer. By E. WYLLYS ANDREWS, M.D. 196
Primary Sarcoma of the Prostate. By CHARLES A. POWERS, M.D. . . . 213
Prostatectomy. By ARCHIBALD MACLAREN, M.D. 222
Further Consideration of the Surgical Treatment of Cancer of the Head and Neck. By GEORGE CRILE, M.D. 231
Acquired Diverticulitis of the Large Intestine. By WILLIAM J. MAYO, M.D. In Collaboration with LOUIS B. WILSON, M.D., and H. Z. GIFFIN, M.D. . 237
The Diverticulum Ilei as a Cause of Complete Intestinal Obstruction in a Manner Hitherto Undescribed. By FREDERIC HENRY GERRISH, M.D. . 255
A Consideration of the Etiology of Certain Cases of Left-sided Intra-abdominal Suppuration (Acute Diverticulitis). By GEORGE EMERSON BREWER, M.D. 258
Remarks on the Surgical Treatment of Facial Paralysis and of Trigeminal Neuralgia, with Exhibition of Patients. By HARVEY CUSHING, M.D. . . 275
The Desirability of Early Operations upon the Nerves in Ischemic Paralysis. By LEONARD FREEMAN, M.D. 284
Fibroid Tumor of the Nasopharynx Removed by Temporary Resection of Both Superior Maxillæ (Kocher). By FREDERICK KAMMERER, M.D. . . 293
Aneurysmal Varix. A Case of Pulsating Exophthalmos, Two Cases of Enormous Dilatation, and One Case of Moderate Dilatation on the Cardiac Side of the Wound. By GEORGE TULLY VAUGHAN, M.D. 300
Congenital Dislocation of the Hips. By OSCAR H. ALLIS, M.D. 311
Subcutaneous Rupture of the Spleen. By ELLSWORTH ELIOT, JR., M.D. . 336
Report of a Case of Non-parasitic Cyst of the Spleen. By THOMAS W. HUNTINGTON, M.D. 366
Four Cases of Rupture of the Kidney, with Remarks upon Conservative Operative Treatment. By THOMAS R. NEILSON, M.D. 371
A Case of Oidiomycosis (Blastomycosis) with Rapid Generalization, the Early Lesions Simulating Giant-celled Sarcoma; Death in Six Months. By WILLIAM B. COLEY, M.D., and MARTHA TRACY, M.D. 386
Some Considerations in Regard to Brain Surgery. By STEPHEN H. WEEKS, M.D. 400
A Case of Multiple Carcinomata Following Chronic X-ray Dermatitis. By C. A. PORTER, M.D., and C. J. WHITE, M.D. 418

Digitized by Google

OFFICERS OF THE ASSOCIATION,

ELECTED MAY, 1907.

PRESIDENT.

WILLIAM H. CARMALT, M.D.

VICE-PRESIDENTS.

WILLIS G. MACDONALD, M.D.
JOHN F. BINNIE, M.D.

SECRETARY.

ROBERT G. LE CONTE, M.D.,
1530 Locust St., Philadelphia.

TREASURER.

CHARLES A. POWERS, M.D.,
Fourteenth and Stout Sts., Denver, Colo.

RECORDER.

RICHARD H. HARTE, M.D.,
1503 Spruce St., Philadelphia.

COUNCIL.

GEORGE BEN JOHNSTON, M.D.,
ALBERT VANDER VEER, M.D.,
DUDLEY P. ALLEN, M.D.,
WILLIAM H. CARMALT, M.D.,
ROBERT G. LE CONTE, M.D.,
CHARLES A. POWERS, M.D.,
RICHARD H. HARTE, M.D.,
} *Ex-officio.*

Digitized by Google

PUBLICATION COMMITTEE.

RECORDER, SECRETARY AND TREASURER, *ex-officio.*

COMMITTEE ON ANNUAL MEETING

A. J. McCOSH, M.D., JOHN M. T. FINNEY, M.D.,
PRESIDENT, SECRETARY, RECORDER AND THE CHAIRMAN OF THE ADJUNCT LOCAL COMMITTEE OF ARRANGEMENTS, *ex-officio.*

COMMITTEE ON NECROLOGY, CREATED IN 1884.
(Report by Title.)

F. H. GERRISH, M.D.,
N. B. CARSON, M.D.,
WM. L. RODMAN, M.D.

Place of next meeting:

RICHMOND, VIRGINIA, MAY, 1908.

ADJUNCT LOCAL COMMITTEE OF ARRANGEMENTS.

GEORGE BEN JOHNSTON, M.D., *Chairman,*
GEO. TULLY VAUGHAN, M.D.,
LEWIS C. BOSHER, M.D.

Digitized by Google

LIST OF THE PRESIDENTS

OF THE

ASSOCIATION FROM THE TIME OF ITS INSTITUTION.

ELECTED

1880. †SAMUEL DAVID GROSS, M.D., LL.D., D.C.L. OXON., LL.D. CANTAB., LL.D. EDIN.—Founder of the Association.
1883. †EDWARD MOTT MOORE, M.D., LL.D.
1884. †WILLIAM THOMPSON BRIGGS, M.D.
1885. †MOSES GUNN, A.M., M.D., LL.D.
1886. †HUNTER McGUIRE, M.D., LL.D.
1887. †D. HAYES AGNEW, M.D., LL.D.
1888. DAVID WILLIAMS CHEEVER, M.D., LL.D.
1889. †DAVID W. YANDELL, M.D.
1890. †CLAUDIUS HENRY MASTIN, M.D., LL.D.
1891. PHINEAS SANBORN CONNER, M.D., LL.D.
1892. NICHOLAS SENN, M.D., PH.D., LL.D.
1893. J. EWING MEARS, A.M., M.D.
1894. FREDERIC SHEPARD DENNIS, M.D.
1895. LOUIS McLANE TIFFANY, A.M. CANTAB., M.D.
1896. JOHN COLLINS WARREN, M.D., LL.D. (JEFFERSON), HON. F.R.C.S. ENG.
1897. †THEODORE F. PREWITT, M.D.
1898. WILLIAM W. KEEN, A.M., M.D., LL.D., HON. F.R.C.S. ENG.
1899. ROBERT F. WEIR, A.M., M.D., F.R.C.S. ENG.
1900. ROSWELL PARK, M.D.
1901. DE FOREST WILLARD, A.M., M.D., PH.D.
1902. MAURICE H. RICHARDSON, A.B., M.D.
1903. NATHANIEL P. DANDRIDGE, M.D.
1904. GEORGE BEN JOHNSTON, M.D.
1905. ALBERT VANDER VEER, M.D.
1906. DUDLEY P. ALLEN, M.D.
1907. WILLIAM H. CARMALT, M.D.

† Deceased.

Digitized by Google

NOTICE.

THIS volume of TRANSACTIONS contains the papers read before the Association at the Meeting held May 7, 8 and 9, 1907.

The Association assumes no responsibility for the statements and opinions published in this volume.

Digitized by Google

FELLOWS

OF THE

AMERICAN SURGICAL ASSOCIATION.

MAY, 1907.

* Denotes Original Fellows.
† Denotes Senior Fellows.

ELECTED

1890. ABBE, ROBERT, M.D., 13 West Fiftieth Street, New York, Surgeon to St. Luke's Hospital. *Vice-President*, 1901.

1894. ALLEN, DUDLEY P., A.M., M.D., *President*, 1907; 1110 (old 260) Euclid Ave., Cleveland, Ohio. Professor of Surgery, Medical Department of Western Reserve University; Visiting Surgeon, Lakeside and Charity Hospitals; Consulting Surgeon to the Cleveland City Hospital.

†1890. ALLIS, OSCAR HUNTINGTON, A.M., M.D., 1604 Spruce Street, Philadelphia. Surgeon to the Presbyterian Hospital.

1902. ANDREWS, E. WYLLYS, A.M., M.D., 2525 Prairie Avenue, Chicago, Ill. Professor of Surgery, Northwestern University Medical School; Surgeon to Mercy Hospital and Michael Reese Hospital; Attending Surgeon to Cook County Hospital; Consulting Surgeon to the Provident Hospital.

1901. ARMSTRONG, GEORGE E., C.M., M.D., 320 Mountain Street, Montreal. Associate Professor of Clinical Surgery, McGill University; Surgeon to the Montreal General Hospital; Surgeon to the Western Hospital, Montreal.

1906. BARROW, DAVID, M.D., 148 Market Street, Lexington, Ky.

†1882. BARTON, JAMES M., A.M., M.D., 220 Railroad Ave., Atlantic City, N. J.

Digitized by Google

ELECTED

1901. BELL, JAMES, M.D., *Vice-President*, 873 Dorchester Street, Montreal. Professor of Clinical Surgery, McGill University; Surgeon to the Royal Victoria Hospital.

1900. BEVAN, ARTHUR DEAN, M.D., 100 State Street, Chicago. Associate Professor of Surgery, Rush Medical College, University of Chicago; Surgeon to Presbyterian Hospital.

1901. BINNIE, J. F., M.B., C.M. (Aberdeen), Argyle Bldg., Twelfth and McGee Sts., Kansas City, Mo. Professor of Surgical Pathology and Clinical Surgery, Kansas City Medical College.

1906. BLAKE, JOHN BAPST, A.M., M.D., 178 Beacon Street, Boston, Mass. Instructor in Surgery, Harvard Medical School; Assistant Surgeon to the Boston City Hospital; Surgeon to the Long Island Hospital and St. Elizabeth's Hospital, Boston, Mass.

1902. BLAKE, JOSEPH A., M.D., 601 Madison Avenue, New York. Instructor in Surgery, Columbia University; Attending Surgeon to St. Luke's Hospital; Junior Surgeon to the Roosevelt Hospital; Consulting Surgeon to the Northern Dispensary.

1901. BLOODGOOD, JOSEPH C., B.S., M.D., 904 North Charles Street, Baltimore, Md. Associate in Surgery in the Johns Hopkins University.

1882. BONTECOU, REED BROCKWAY, M.D., 82 Fourth Street, Troy, N. Y. Surgeon to the Marshall Infirmary.

1901. BOSHER, LEWIS C., M.D., 717 East Franklin Street, Richmond, Va. Professor of Surgery, Medical College of Virginia; Surgeon to the Old Dominion Hospital.

1890. BRADFORD, EDWARD HICKLING, A.B., M.D., 133 Newbury Street, Boston. Surgeon to the Children's and the Samaritan Hospitals; Assistant Professor of Orthopedic Surgery in the Harvard University.

1900. BREWER, GEORGE EMERSON, M.D., 61 West Forty-eighth Street, New York City. Professor of Clinical Surgery in College of Physicians and Surgeons, Columbia University; Junior Surgeon, Roosevelt Hospital; Attending Surgeon, City Hospital; Consulting Surgeon to the Ophthalmic and Aural Institute, and to the Perth Amboy Hospital.

1906. BRISTOW, A. T., A.B., M.D., 234 Clinton Street, Brooklyn, New York. Clinical Professor of Surgery at the Long Island College Hospital; Attending Surgeon to the Kings County Hospital, St. John's Hospital, and Long Island College Hospital; Consulting Surgeon to the Long Island State Hospital, the Bushwick Central Hospital, and the Swedish Hospital.

Digitized by Google

ELECTED

1895. BRYANT, JOSEPH D., M.D., 32 West Forty-eighth Street, New York. Professor of Anatomy and of Operative and Clinical Surgery, Bellevue and St. Vincent's Hospitals; Consulting Surgeon to Gouverneur Hospital, Hospital for Ruptured and Crippled, St. Joseph's and Hackensack Hospitals, Asylum for Insane, New York, etc.

1882. BULL, WILLIAM TILLINGHAST, A.B., M.D., 35 West Thirty-fifth Street, New York. Adjunct Professor of the Practice of Surgery and of Clinical Surgery in the College of Physicians and Surgeons, New York; Surgeon to the New York and St. Luke's Hospitals; Consulting Surgeon to the Hospital for Ruptured and Crippled, and to the New York Cancer Hospital.

1900. BUNTS, FRANK E., M.D., 275 Prospect Street, Cleveland, Ohio. Professor of Principles of Surgery and Clinical Surgery in Medical College of Western Reserve University; Visiting Surgeon to St. Vincent's Charity Hospital; Consulting Surgeon to Cleveland City and Lutheran Hospitals.

1893. BURRELL, HERBERT LESLIE, M.D. (Harvard), 22 Newbury Street, Boston, Mass. Assistant Professor of Surgery in Harvard University; Visiting Surgeon, Boston City Hospital; Visiting Surgeon to the Children's Hospital; Consulting Surgeon, Carney Hospital and the Quincy Hospital. *Secretary* 1895–1901.

1889. CABOT, ARTHUR TRACY, A.M., M.D., 1 Marlborough Street, Boston, Mass. Surgeon to Massachusetts General Hospital.

†1885. CARMALT, WILLIAM H., A.M., M.D., 87 Elm Street, New Haven, Conn. Professor of Surgery in Yale University; Surgeon to the New Haven Hospital. *Vice-President*, 1895.

1896. CARSON, NORMAN BRUCE, M.D., 303 Humboldt Bldg., St. Louis, Mo. Professor of Clinical Surgery in the St. Louis Medical College; Surgeon to St. Louis and Mullanphy Hospitals and to the St. Vincent Insane Asylum, etc. *Vice-President*, 1903.

†1882. CHEEVER, DAVID WILLIAMS, M.D., LL.D., 557 Boylston Street, Boston, Mass. Professor of Surgery (Emeritus) in Harvard University; Surgeon to Boston City Hospital. *President*, 1888.

1896. COLE, CHARLES KNOX, A.M., M.D., Helena, Montana. Surgeon to St. John's, St. Peter's, and County Hospitals.

1898. COLEY, WILLIAM B., M.D., 5 Park Avenue, New York. Attending Surgeon to the General Memorial Hospital; Associate Surgeon to the Hospital for Ruptured and Crippled, New York.

Digitized by Google

ELECTED

*†1880. CONNER, PHINEAS SANBORN, M.D., LL.D., 215 West Ninth Street, Cincinnati, Ohio. Professor of Surgery in the Medical College of Ohio; Emeritus Professor of Surgery, Dartmouth Medical College; Surgeon to the Cincinnati and the Good Samaritan Hospitals. *President*, 1891; *Member of Council*, 1883, and 1895–1900; *Treasurer*, 1885–91.

1905. CRILE, GEORGE W., M.D., 275 Prospect Street, Cleveland, Ohio. Professor of Clinical Surgery, Western Reserve Medical College; Visiting Surgeon to St. Alexis' Hospital; Associate Surgeon to Lakeside Hospital.

1896. CURTIS, BENJAMIN FARQUHAR, A.B., M.D., 7 East Forty-first Street, New York. Professor of the Principles of Surgery and Clinical Surgery, University and Bellevue Hospital Medical College of New York; Attending Surgeon to St. Luke's and Bellevue Hospitals, and the General Memorial Hospital for Treatment of Cancer and Allied Diseases; Consulting Surgeon to New York Orthopedic Hospital and Dispensary.

1906. CUSHING, HARVEY, A.M., M.D., 3 West Franklin Street, Baltimore, Md. Associate Professor of Surgery, Johns Hopkins University.

1896. CUSHING, HAYWARD WARREN, A.B., M.D., 90 Commonwealth Avenue, Boston. Mass. Junior Visiting Surgeon, Boston City Hospital; Assistant Surgeon, Children's Hospital, Boston.

1897. DA COSTA, JOHN CHALMERS, M.D., 2045 Walnut Street, Philadelphia, Pa. Clinical Professor of Surgery, Jefferson Medical College; Surgeon to the Philadelphia and the Phœnixville Hospitals.

1883. DANDRIDGE, NATHANIEL PENDLETON, M.D., 422 Broadway, Cincinnati, Ohio. Professor of Practice of Surgery and of Clinical Surgery in the Miami Medical College, Cincinnati. *President*, 1904. *Treasurer*, 1894–96. *Member of Council*, 1904.

1892. DEAVER, JOHN B., M.D., 1634 Walnut Street, Philadelphia. Surgeon-in-Chief to the German Hospital, Philadelphia.

1882. DENNIS, FREDERIC SHEPARD, M.D., F.R.C.S. ENG., 542 Madison Avenue, New York. Professor of Clinical Surgery, Cornell University, New York City; Visiting Surgeon to the Bellevue and St. Vincent's Hospitals; Consulting Surgeon to St. Joseph's Hospital, Yonkers, and Montefiore Home, New York City. *President*, 1894; *Vice-President*, 1887; *Member of Council*, 1889.

Digitized by Google

ELECTED

1901. ELIOT, ELLSWORTH, JR., M.D., 48 West Thirty-sixth Street, New York. Clinical Lecturer and Demonstrator of Surgery, College of Physicians and Surgeons, New York; Surgeon to the Presbyterian Hospital.

1893. ELLIOT, JOHN WHEELOCK, A.M., M.D. (Harvard), 124 Beacon Street, Boston. Surgeon to Massachusetts General Hospital.

1896. ESTES, WILLIAM LAWRENCE, A.M., M.D., South Bethlehem, Pa. Director and Surgeon-in-Chief of St. Luke's Hospital; Lecturer on Hygiene at Lehigh University.

1898. EVE, DUNCAN, A.M., M.D., 700 Church Street, Nashville, Tenn. Professor of Surgery and Clinical Surgery, Medical Department, Vanderbilt University; Surgeon to the Nashville City Hospital.

1901. FERGUSON, ALEX. HUGH, C.M., M.D., 10 Drexel Square, Chicago, Ill. Professor of Clinical Surgery in the Medical Department of the University of the State of Illinois; Professor of Surgery in the Post-Graduate Medical School of Chicago; Surgeon-in-Chief of the Chicago Hospital; Surgeon to Cook County Hospital for the Insane; Consulting Surgeon to Provident Hospital.

1899. FINNEY, JOHN M. T., M.D., 1300 Eutaw Place, Baltimore, Md. Associate Professor of Surgery, Johns Hopkins University.

1904. FRAZIER, CHARLES HARRISON, M.D., 1724 Spruce Street, Philadelphia, Pa. Professor of Clinical Surgery, University of Pennsylvania; Surgeon to the University Hospital.

1898. FREEMAN, LEONARD, B.S., M.D., 1801 Franklin Street, Denver, Col. Professor of Surgery, Gross Medical College; Surgeon to the Arapahoe County Hospital and to St. Anthony's Hospital.

†1882. GAY, GEORGE WASHINGTON, A.M., M.D., 665 Boylston Street, Boston, Mass. Senior Surgeon to the Boston City Hospital, Clinical Instructor in Surgery in Harvard University. *Member of Council*, 1882.

1892. GERRISH, FREDERIC HENRY, A.M., M.D. (Bowdoin), LL.D. (University of Michigan and Bowdoin), 675 Congress Street, Portland, Maine. Professor of Surgery in the Medical Department of Bowdoin College; Consulting Surgeon, Maine General Hospital.

1890. GERSTER, ARPAD G., M.D., Chir. D., 34 East Seventy-fifth Street, New York. Professor of Surgery in the New York Polyclinic; Surgeon to the German and Mount Sinai Hospitals.

Digitized by Google

ELECTED

1906. GIBBON, JOHN H., M.D., 1608 Spruce Street, Philadelphia. Professor of Surgery, Jefferson Medical College; Surgeon to the Pennsylvania Hospital and the Bryn Mawr Hospital; Consulting Surgeon to the Woman's Hospital.

1906. GIBSON, C. L., M.D., 8 East Fifty-eighth Street, New York, N. Y. Professor of Clinical Surgery, Cornell University Medical College; Surgeon to St. Luke's and the City Hospitals.

†1892. HALSTED, WILLIAM STEWART, B.A., M.D., 1201 Eutaw Place, Baltimore, Md. Surgeon to Johns Hopkins Hospital.

1898. HARRINGTON, FRANCIS B., A.B. (Tufts College), M.D. (Harvard College), 201 Beacon Street, Boston, Mass. Surgeon to Massachusetts General Hospital.

1900. HARRIS, MALCOLM L., M.D., 612 Reliance Building, Chicago, Ill. Professor of Surgery, Chicago Polyclinic; Attending Surgeon, Alexian Brothers' Hospital, St. Luke's Hospital, and Maurice Porter Hospital for Children.

1895. HARTE, RICHARD H., M.D., *Recorder*, 1503 Spruce Street, Philadelphia. Associate Professor of Surgery, University of Pennsylvania; Surgeon to the Pennsylvania Hospital, and Orthopedic Hospital and Infirmary for Nervous Diseases; Consulting Surgeon to St. Mary's, St. Timothy's, and Bryn Mawr Hospitals.

1898. HEARN, W. JOSEPH, M.D., 1120 Walnut Street, Philadelphia. Clinical Professor of Surgery, Jefferson Medical College; Visiting Surgeon to the Philadelphia Hospital; Consulting Surgeon to the Phœnixville General Hospital.

1899. HORWITZ, ORVILLE, M.D., 1721 Walnut Street, Philadelphia. Clinical Professor of Genito-urinary Diseases, Jefferson Medical College; Surgeon to the Philadelphia Hospital; Consulting Surgeon to State Hospital for Insane and Hayes Mechanics' Home.

1901. HUNTINGTON, THOMAS W., A.B., M.D., *Vice-President*, 1118 Sutter Street, San Francisco, California. Professor of Clinical and Operative Surgery, Medical Department, University of California; Visiting Surgeon to the City and County Hospital, San Francisco; Consulting Surgeon, St. Luke's Hospital, San Francisco.

1901. JACOBSON, NATHAN, M.D., 430 South Salina Street, Syracuse, N. Y. Professor of Clinical Surgery, College of Medicine, Syracuse University; Surgeon to St. Joseph's Hospital.

Digitized by Google

ELECTED

1901. JOHNSON, ALEXANDER B., M.D., 12 East Fifty-eighth Street, New York. Professor of Clinical Surgery, Cornell University Medical College; Attending Surgeon to New York Hospital.

1905. JOHNSON, ROBERT W., A.B., M.D., 101 W. Franklin Street, Baltimore, Md. Professor of Principles and Practice of Surgery, Baltimore Medical College; Surgeon to Maryland General Hospital; Church Home and Infirmary; St. Agnes' Hospital.

1896. JOHNSTON, GEORGE BEN, M.D., 405 East Grace Street, Richmond, Va. Professor of the Practice of Surgery and of Clinical Surgery in the Medical College of Virginia; Surgeon to the Old Dominion Hospital, and Consulting Surgeon to the Richmond City Free Dispensary. *President*, 1904; *Member of Council*, 1907.

1901. JONAS, A. F., M.D., *Vice-President*, 106 South Thirty-first Avenue, Omaha, Nebraska. Professor of Surgery, Omaha Medical College; Surgeon to the Methodist Episcopal Hospital and to the Douglas County Hospital.

1899. KAMMERER, FREDERICK, M.D., 51 East Sixty-sixth Street, New York City. Professor of Clinical Surgery, Cornell Medical College; Surgeon to the German and St. Francis' Hospitals, New York.

*†1880. KEEN, WILLIAM WILLIAMS, A.M., M.D., LL.D., HON. F.R.C.S. ENG. and EDIN., 1729 Chestnut Street, Philadelphia. Emeritus Professor of the Principles of Surgery and of Clinical Surgery in the Jefferson Medical College; Surgeon to the Jefferson Medical College Hospital; Consulting Surgeon to the Woman's and St. Agnes' Hospitals; Membre Correspondant Etrangér de la Société de Chirurgie de Paris; Membre Honoraire de la Société Belge de Chirurgie. Ehreunitglied der Deutschen Gesellschaft für Chirurgie; Honorary Member, Clinical Society of London. *President*, 1898; *Vice-President*, 1892; *Member of Council*, 1899–1901.

1901. LA GARDE, LOUIS A., M.D., United States Soldiers' Home, Washington, D. C. Professor of Military Surgery, New York University and Bellevue Hospital Medical College; Major and Surgeon United States Army.

1901. LE CONTE, ROBERT G., A.B., M.D., *Secretary*, 1530 Locust Street, Philadelphia. Surgeon to the Pennsylvania, the Children's, and the Bryn Mawr Hospitals.

Digitized by Google

ELECTED

1903. LUTZ, F. J., A.M., M.D., 3337 Lafayette Place, St. Louis, Mo. Professor of Surgery, Medical Department, St. Louis University; Surgeon-in-Chief, Alexian Brothers' Hospital; Surgeon-in-Charge, Josephine Hospital.

1001. MCARTHUR, L. L., M.D., 4415 Drexel Building, Chicago, Ill. Professor of Clinical Surgery, Post-Graduate Medical School; Assistant Professor of Clinical Surgery, Rush Medical College; Surgeon to St. Luke's and Michael Reese Hospitals.

1896. MCCOSH, ANDREW J., B.A., M.D., 16 East Fifty-fourth Street, New York. Surgeon to the Presbyterian Hospital; Clinical Lecturer on Surgery, College of Physicians and Surgeons.

1882. MCGRAW, THEODORE A., M.D., 73 Case Street, Detroit, Mich. Professor of Surgery in the Detroit Medical College; Surgeon to St. Mary's and Harper Hospitals. *Vice-President*, 1896.

1903. MCMURTRY, LEWIS S., A.M., M.D., 1912 Sixth Street, Louisville, Ky. Professor of Gynecology and Abdominal Surgery, Hospital of Medicine, Louisville, Ky.

1901. MACDONALD, WILLIS G., M.D., 27 Eagle Street, Albany, New York.

1904. MACLAREN, ARCHIBALD, M.D., B.S., 350 St. Peter Street, St. Paul, Minn. Professor of Clinical Surgery, University of Minnesota.

1906. MACMONAGLE, BEVERLY, M.D., 1316 Sutter Street, San Francisco, Cal. Surgeon to the Children's Hospital; Consulting Surgeon to the German Hospital.

*†1880. MARKS, SOLON, M.D., 136 Wisconsin Street, Milwaukee, Wis. Surgeon to St. Mary's Hospital. *Vice-President*, 1898.

1898. MARTIN, EDWARD, M.D., 1506 Locust Street, Philadelphia. Clinical Professor of Surgery, University of Pennsylvania; Clinical Professor of Surgery, Woman's Medical College, Philadelphia; Surgeon to Philadelphia, St. Agnes', and Howard Hospitals.

†1895. MASTIN, WILLIAM MCDOWELL, M.D., Northeast corner of Joachim and Conti Streets, Mobile, Ala. Surgeon to the Mobile City Hospital.

1895. MATAS, RUDOLPH, M.D., 2255 St. Charles Avenue, New Orleans, La. Professor of Surgery, Medical Department, Tulane University; Professor of Clinical Surgery, New Orleans Polyclinic; Surgeon to Charity Hospital; Consulting Surgeon to the Eye, Ear, Nose, and Throat Hospital. *Vice-President*, 1901.

Digitized by Google

ELECTED

1903. MAYO, CHARLES H., M.D., Rochester, Minn. Surgeon to St. Mary's Hospital.

1899. MAYO, WILLIAM J., A.M., M.D., F.R.C.S. EDIN., LL.D. TOR., 427 West College Street, Rochester, Minn. Surgeon to St. Mary's Hospital. *Vice-President*, 1903.

*†1880. MEARS, J. EWING, A.M., M.D., 1535 Land Title Building, Philadelphia. *President*, 1893; *Recorder*, 1881–93.

1901. MEYER, WILLY, M.D., 700 Madison Avenue, New York. Professor of Surgery in the New York Post-Graduate Medical School and Hospital; Attending Surgeon to the German and New York Skin and Cancer Hospitals; Consulting Surgeon to the New York Infirmary for Women and Children.

1893. MIXTER, SAMUEL JASON, S.B. (Massachusetts Institute of Technology), M.D. (Harvard), 180 Marlborough Street, Boston. Surgeon to Massachusetts General Hospital and to Carney Hospital; Consulting Surgeon to the Massachusetts Charity Eye and Ear Infirmary; Instructor in Surgery in the Harvard University.

1896. MONKS, GEORGE HOWARD, A.B. (Harvard), M.D. (Harvard), M.R.C.S. Eng., 67 Marlborough Street, Boston. Junior Visiting Surgeon, Boston City Hospital; Lecturer on Surgery, Harvard Medical School and Harvard Dental School.

1895. MOORE, JAMES E., M.D., 704 Pillsbury Street, Minneapolis, Minn. Professor of Surgery, University of Minnesota; Surgeon-in-Chief to the Northwestern Hospital. *Vice-President*, 1905.

1898. MORTON, THOMAS S. K., M.D., Schoolhouse Lane, Germantown, Philadelphia.

1904. MUDD, HARVEY G., M.D., 2604 Locust Street, St. Louis, Mo. Professor of Fractures and Dislocations and Clinical Surgery, Medical Department, Washington University; Surgeon to St. Luke's Hospital; Consulting Surgeon to the St. Louis City Hospital.

1906. MUMFORD, J. G., M.D., 29 Commonwealth Ave., Boston, Mass. Instructor in Surgery, Harvard Medical School; Visiting Surgeon to the Massachusetts General Hospital.

1900. MUNRO, JOHN C., M.D., 173 Beacon Street, Boston. Instructor in Surgery, Harvard; Professor of Surgery, Tufts College Dental School; Assistant Visiting Surgeon, Boston City Hospital. *Vice-President*, 1905.

1902. MURPHY, JOHN B., A.M., M.D., 100 State Street, Chicago, Ill. Professor of Surgery, Medical Department of Northwestern

Digitized by Google

ELECTED

University, Chicago Post-Graduate School and Hospital, and Chicago Clinical School; Attending Surgeon to Mercy Hospital, Cook County Hospital, and Wesley Hospital; Consulting Surgeon to the Alexian Brothers' Hospital and Hospital for Crippled Children.

1898. MURRAY, FRANCIS W., M.D., 32 West Thirty-ninth Street, New York City. Professor of Clinical Surgery in Cornell University Medical College; Surgeon to the New York and St. Luke's Hospitals.

1882. DE NANCRÈDE, C. B. G., A.M. (University of Pennsylvania), M.D., LL.D. (Jefferson), 720 South University Avenue, Ann Arbor, Mich. Professor of Surgery in the University of Michigan; Professor of Surgery, Dartmouth Medical College. *Vice-President*, 1889 and 1899.

1903. NEILSON, THOMAS R., M.D., 122 South Seventeenth Street, Philadelphia, Pa. Surgeon to the Episcopal Hospital and to St. Christopher's Hospital for Children; Clinical Professor of Genito-urinary Diseases in the University of Pennsylvania.

1900. OCHSNER, A. J., B.S., F.R.M.S., M.D. (ENG.), 710 Sedgwick Street, Chicago. Professor of Clinical Surgery, College of Physicians and Surgeons; Surgeon-in-Chief of Augustana and St. Mary's Hospitals.

1900. OLIVER, J. C., M.D., 628 Elm Street, Cincinnati, Ohio. Dean and Professor of Operative Surgery, Miami Medical College; Surgeon, Cincinnati, Presbyterian, and Christ Hospitals.

1905. OVIATT, CHARLES W., M.D., 500 Algoma Street, Oshkosh, Wis.

†1882. OWENS, JOHN E., M.D., 1201 Venetian Building, Chicago, Ill. Professor of Principles and Practice of Surgery and Clinical Surgery in the Chicago Medical College; Surgeon to St. Luke's Hospital. *Vice-President*, 1900.

1899. PARHAM, FREDERICK WILLIAM, M.D., 1429 Seventh Street, New Orleans, La. Professor of General, Clinical, and Operative Surgery on the Cadaver, New Orleans Polyclinic; Surgeon to Charity Hospital; Consulting Surgeon to Eye, Ear, Nose, and Throat Hospital.

1885. PARK, ROSWELL, A.M., M.D., 510 Delaware Avenue, Buffalo, N. Y. Professor of Surgery in the Medical Department of the University of Buffalo; Surgeon to the Buffalo General Hospital; Consulting Surgeon to the Fitch Accident Hospital.

Digitized by Google

ELECTED

President, 1900; *Vice-President*, 1893; *Member of Council*, 1893–94, 1901–03.

1893. PARMENTER, JOHN, M.D., 519 Franklin Street, Buffalo, N. Y. Professor of Anatomy and Clinical Surgery in the Medical Department of the University of Buffalo; Surgeon to the Sisters of Charity, Erie County, Fitch, Children's, and Emergency Hospitals; Assistant Surgeon to the Buffalo General Hospital.

1889. PILCHER, LEWIS S., A.M., M.D., LL.D. (Dickinson), 145 Gates Avenue, Brooklyn, N. Y. Professor of Clinical Surgery in the Post-Graduate Medical School, New York; Surgeon to the Methodist Episcopal Hospital, New York. *Vice-President*, 1893.

1904. PORTER, CHARLES ALLEN, A.M., M.D., 254 Beacon Street, Boston, Mass. Assistant Surgeon to the Massachusetts General Hospital; Instructor in Surgery, Harvard Medical School.

†1887. PORTER, CHARLES BURNHAM, A.M., M.D. (Harvard), 5 Arlington Street, Boston, Mass. Professor of Clinical Surgery in Harvard University; Surgeon to the Massachusetts General Hospital. *Vice-President*, 1892.

1896. POWERS, CHARLES A., A.M., M.D., *Treasurer*, Fourteenth and Stout Streets, Denver, Col. Professor of Surgery in the University of Denver, and Surgeon to the Denver City and County Hospital, and to St. Luke's Hospital; Consulting Surgeon to the Mercy Hospital and to the State Home for Children. *Vice-President*, 1903.

1886. RANSOHOFF, JOSEPH, M.D., F.R.C.S. ENG., 19 West Seventh Street, Cincinnati, Ohio. Professor of Anatomy in the Medical College of Ohio; Surgeon to the Cincinnati and the Good Samaritan Hospitals.

1887. RICHARDSON, MAURICE HOWE, A.B., M.D., 224 Beacon Street, Boston, Mass. Moseley Professor of Surgery in Harvard University; Surgeon to the Massachusetts General Hospital. *President*, 1902; *Vice-President*, 1897; *Secretary*, 1894–96; *Member of Council*, 1904.

1901. RIXFORD, EMMET, B.S., M.D., 1795 California Street, San Francisco, Cal. Professor of Surgery in Cooper Medical College; Surgeon to City, County, and Lane Hospitals. *Vice-President*, 1905.

1882. ROBERTS, JOHN B., A.M., M.D., 313 South Seventeenth Street, Philadelphia. Professor of Anatomy and Surgery in the Philadelphia Polyclinic; Surgeon to the Methodist and Jewish Hospitals. *Vice-President*, 1888 and 1894; *Treasurer*, 1892–93.

Digitized by Google

ELECTED

1898. RODMAN, WILLIAM L., A.M., M.D., 1904 Chestnut Street, Philadelphia. Professor of the Principles of Surgery and Clinical Professor of the Principles and Practice of Surgery and Clinical Surgery in the Woman's Medical College, Philadelphia; Professor of Surgery, Medico-Chirurgical College, Philadelphia.

†1882. RUSHMORE, JOHN DIKEMAN, M.D., 129 Montague Street, Brooklyn, N. Y. Professor of Surgery in the Long Island College Hospital; Surgeon to the Brooklyn, St. Peter's, and the Eye and Ear Hospitals.

†1882. SENN, NICHOLAS, M.D., PH.D., LL.D. (Jefferson), 532 Dearborn Avenue, Chicago, Ill. Professor of the Principles of Surgery and Clinical Surgery in Rush Medical College; Surgeon to Presbyterian Hospital; Surgeon-in-Chief to St. Joseph's Hospital. *President*, 1892; *Member of Council*, 1897.

1902. SHEPHERD, FRANCIS J., M.D., 152 Mansfield Street, Montreal, Canada. Professor of Anatomy and Lecturer on Operative Surgery in McGill University, Montreal; Senior Surgeon to the Montreal General Hospital.

1905. SHERMAN, HARRY M., A.B., M.D., A.M., 2125 Jackson Street, San Francisco, Cal. Professor of Surgery in the University of California; Surgeon to St. Luke's Hospital, San Francisco; Orthopedic Surgeon to the Children's Hospital, San Francisco.

1895. SOUCHON, EDMOND, M.D., 2403 St. Charles Avenue, New Orleans, La. Professor of Anatomy and of Clinical Surgery, Tulane University; Surgeon to Charity Hospital; Consulting Surgeon to the Eye, Ear, Nose, and Throat Hospital. *Vice-President*, 1899

1900. TAYLOR, WILLIAM J., M.D., 1825 Pine Street, Philadelphia. Surgeon to the Orthopedic Hospital and Infirmary for Nervous Diseases, and to St. Agnes' Hospital; Consulting Surgeon to the West Philadelphia Hospital for Women.

†1882. TIFFANY, LOUIS MCLANE, A.M. (Cantab.), M.D., 831 Park Avenue, Baltimore, Md. *President*, 1895; *Member of Council* 1883–89; 1896–97.

Digitized by Google

ELECTED

1882. VANDER VEER, ALBERT, A.M., M.D., PH.D., 28 Eagle Street, Albany, N. Y. Dean of Albany Medical College; Professor of Didactic Abdominal Surgery and of Clinical Surgery in the Albany Medical College; Consulting Surgeon to St. Peter's Hospital; Attending Surgeon to the Albany Hospital. *President*, 1905; *Vice-President*, 1898; *Member of Council*, 1907.

1902. VAUGHAN, GEORGE TULLY, M.D., 1718 I Street, Washington, D. C. Professor of Principles and Practice of Surgery, Georgetown University; Professor of Surgery and Genito-urinary Surgery, Washington Post-Graduate Medical School; Chief Surgeon, Georgetown University Hospital; Surgeon, Emergency Hospital; Consulting Surgeon, Government Hospital for the Insane, Washington, D. C.; Assistant Surgeon-General U. S. Public Health and Marine Hospital Service.

1891. WALKER, EDWARD W., M.D., 30 Garfield Place, Cincinnati, Ohio. Professor of Surgery, Miami Medical College.

†1882. WARREN, JOHN COLLINS, M.D., LL.D. (Jefferson), HON. F.R.C.S. ENG. 58 Beacon Street, Boston, Mass. Professor of Surgery in Harvard University; Surgeon to the Massachusetts General Hospital. *President*, 1896; *Vice-President*, 1890; *Member of Council*, 1897.

1896. WATSON, FRANCIS SEDGWICK, A.B., M.D., 92 Marlborough Street, Boston. Surgeon to the Boston City Hospital; Instructor in Genito-urinary Surgery, Harvard Medical School.

1889. WEEKS, STEPHEN H., M.D., 662 Congress Street, Portland, Maine. Emeritus Professor of Surgery in the Medical School of Maine; Surgeon to Maine General Hospital. *Vice-President*, 1903; *Member of Council*, 1893.

†1889. WEIR, ROBERT F., A.M., M.D., HON. F.R.C.S. ENG., Cor. Mem. Surg. Soc., Paris, 11 East Fifty-fourth Street, New York. Professor of Surgery in the College of Physicians and Surgeons, Columbia University; Surgeon to the Roosevelt Hospital. *President*, 1899; *Member of Council*, 1893–1896; 1901–03.

1892. WHARTON, HENRY R., A.M., M.D., 1725 Spruce Street, Philadelphia. Surgeon to the Presbyterian, Children's, and Methodist Hospitals.

1882. WHITE, J. WILLIAM, M.D., Ph.D., 1810 South Rittenhouse Square, Philadelphia. John Rhea Barton Professor of Surgery in the University of Pennsylvania.

Digitized by Google

ELECTED

†1882. WILLARD, DE FOREST, A.M., M.D. (Univ. of Pa.), PH.D., 1901 Chestnut Street, Philadelphia. Professor of Orthopedic Surgery in the University of Pennsylvania; Surgeon to the Presbyterian Hospital; Consulting Surgeon to the Germantown Hospital; the Atlantic City Hospital; the Jewish Hospital; the Phœnixville Hospital; and the South Mountain Hospital. *President*, 1901; *Recorder*, 1893–1900; *Member of Council*, 1901–04.

1901. WOOLSEY, GEORGE, M.D., 117 East Thirty-sixth Street, New York City. Professor of Anatomy and Clinical Surgery, Cornell University; Surgeon to Bellevue Hospital; Associate Surgeon to the Presbyterian Hospital.

Digitized by Google

HONORARY FELLOWS.

ELECTED.

1885. ANNANDALE, THOMAS, M.R.C.S. ENG., M.D. EDIN., 34 Charlotte Square, Edinburgh, Scotland. Regius Professor of Clinical Surgery in the University of Edinburgh.

1905. BILLINGS, JOHN S., M.D., 40 Lafayette Place, New York, N. Y.

1891. BRYANT, THOMAS, ESQ., F.R.C.S. ENG., 65 Grosvenor Place, Grosvenor Square, W., London.

1891. CHIENE, JOHN, F.R.C.S. EDIN., M.D. EDIN., 26 Charlotte Square, Edinburgh, Scotland. Professor of Surgery in the University of Edinburgh.

1885. CZERNY, PROF. DR. VINCENT, 25 Sophien Strasse, Heidelberg, Germany. Professor of Surgery in the University of Heidelberg.

1885. VON ESMARCH, NIRKL, PROF. DR. FREIDRICH, 2 Hospitalberg, Kiel, Schleswig-Holstein, Germany. Professor of Surgery in the University of Kiel.

1891. HARRISON, REGINALD, ESQ. F.R.C.S. ENG., 6 Lower Berkeley Street, Portman Square, W., London.

1890. HORSLEY, SIR VICTOR ALEXANDER HADEN, F.R.C.S. ENG., 25 Cavendish Square, W., London.

1894. KOCHER, PROF. DR. THEODOR, Professor of Surgery, University of Berne, 25 Villette, Berne, Switzerland.

1885. LISTER, LORD JOSEPH, F.R.C.S., ENG., D.C.L., LL.D., 12 Park Crescent, London, N. W. Professor of Clinical Surgery in King's College.

1894. MACEWEN, SIR WILLIAM, M.D., Mast. Surg., 3 Woodside Crescent, Glasgow, Scotland.

Digitized by Google

ELECTED

1903. ROBSON, A. W. MAYO, M.D., F.R.C.S., D.Sc., 8 Park Crescent, Portland Place, London, W., England. Vice-President, Royal College of Surgeons of England; Hunterian Professor of Surgery and Pathology.

1882. SMITH, STEPHEN, A.M., M.D., LL.D., 574 Madison Avenue, New York. Professor of Clinical Surgery in the University Medical College of New York; Surgeon to the Bellevue and St. Vincent's Hospitals. *Vice-President*, 1890.

1896. TERRIER, DR. FELIX, 11 Rue de Solferino, Paris, France. Professor of Operative Surgery in the Faculty of Medicine of Paris; Surgeon to the Hôpital Bichat.

Digitized by Google

REPORT OF THE COMMITTEE ON NECROLOGY.

GEORGE RYERSON FOWLER, M.D.

Dr. George Ryerson Fowler, a member of the American Surgical Association since 1891, died in Albany, New York, February 6, 1906. The circumstances attending his death were such as gave a tragical aspect to the passing of this distinguished surgeon. He had left his home in Brooklyn, New York, apparently in the best of health, for the purpose of attending to his duties as a member of the Medical Examining Board of the State of New York, and of engaging in the work of the Annual Meeting of the Medical Society of the State of New York. While en route he was seized with severe abdominal pain, for which he sought medical advice as soon as he reached his hotel in Albany. The continuance of marked and severe symptoms caused his advisers to have him removed to the Albany Hospital, where, upon the following day, he was subjected to a laparotomy; the section revealed a necrotic appendix, which was removed. A paresis of the small bowel developed immediately thereafter, which persisted despite every effort of his colleagues, and terminated in his death upon the fourth day thereafter.

Dr. Fowler was born in New York City, December 25, 1848; his parents, Thomas W. and Sarah Jane (Carman) Fowler, were both natives of Long Island, as was also his grandfather, Duncan B. Fowler, who participated in the War of 1812. The early part of the life of Dr. Fowler was passed in Jamaica, Long Island, where his parents had removed, and there he laid the foundation of his general education in the common schools of that town. Having chosen medicine and surgery as his lifework, he entered Bellevue Hospital Medical College, in New York City, where he was graduated with the degree of Doctor of Medicine in 1871. Two men among his teachers especially influenced him: these were James R. Wood and Lewis A. Sayre. Insensibly, perhaps, but none the less actually, they were his models and the inspirers of the devotion to the surgical side of his work, which from the first characterized him.

The first fifteen years of Fowler's professional life were occupied by a general practice, although with progressive preponderance of that which was surgical; his ambition from the first was to be recognized as a surgeon. The advantages of a hospital interneship after his graduation had been denied him, simply because the necessity of self-support had made it necessary for him to enter at once into active practice. It was many years before any opportunity for hospital work opened to

Digitized by Google

him, although from the first he had an intense desire both to teach and to labor in the wards of a hospital. All the existing avenues in either direction in the city of his location were preoccupied, and it was not until the building of a new and large hospital in Brooklyn—St. Mary's Hospital—in 1882, that he received recognition. When the staff of that great hospital was organized, Fowler was selected as one of its surgeons. Five years later, when the Seney Methodist Episcopal Hospital opened its doors to patients, Fowler was one of the men chosen to do its surgical work, and for twenty years, up to the time of his death, he rendered continuous service to this hospital. The Brooklyn Hospital made him its Chief Surgeon in 1896, and of the German Hospital, when it was opened in 1900, he became at once its most active surgeon. Meanwhile, he had been made one of the Professors of Surgery in the Polyclinic Post-graduate School of New York City. The State availed itself of his knowledge by appointing him Examiner in Surgery in its Medical Examining Board, and, later, by utilizing his services as Surgeon-General of its National Guard. As a Chief Surgeon of Volunteers, he was in the United States service during the Spanish-American war, and in that capacity accompanied the Seventh Army Corps to Cuba.

Dr. Fowler was also upon the consulting staff of many hospitals in Brooklyn and on Long Island, and was active in all the important medical organizations of his city and State. He was twice President of the Medical Society of the County of Kings, was Vice-President of the New York Academy of Medicine, and from 1897 to 1906 was Treasurer of the American Surgical Association.

Dr. Fowler was a man of indomitable energy; his capacity for work seemed almost without limit; his growth as a surgeon was progressive and symmetrical. He had a cordial and open nature which attracted men to him; he had perfect confidence in his own resources and in his ability to meet emergencies; he was possessed by his profession to a remarkable degree, so that a demand upon him for professional services ever met an eager response upon his part. There was no department of surgical effort which he did not make his own; he was among the earliest and most enthusiastic adherents in Brooklyn of the Listerian methods, and each new advance of surgery which characterized the last quarter of the nineteenth century found in him one of its earliest and most enthusiastic followers. At home and abroad, he sought everywhere to familiarize himself with the methods of the leaders in surgery.

He was a frequent contributor to surgical literature. Beginning in 1880, with papers on "Excision of the Knee-joint," "Fractures of the Elbow-joint," and "The Surgical Treatment of Facial Neuralgia," each year thereafter was marked by important contributions from his pen. In 1887 he contributed to Wood's *Reference Hand-book of the Medical*

Digitized by Google

Sciences, "Injuries and Diseases of the Patella;" in 1893, to Appleton's *System of Genito-urinary Surgery* the article on "Injuries and Diseases of the Bladder;" and in 1901, to the *International Text-book of Surgery* articles on "Wounds and Contusions," "Burns and Scalds," "Effects of Lightning Shock," "Fat Embolism," and "Repair of Special Tissues."

Into the development of the surgery of appendicitis, Dr. Fowler threw himself with especial abandon. From the beginning of the new teachings on this subject, he took the most advanced ground. In 1894 he published a monograph upon the subject, which still remains one of the most complete and authoritative therein. It is but another of the not infrequent examples of the "irony of fate," that from this disease, to the knowledge and treatment of which he had contributed so much, he himself should ultimately have fallen a victim.

For the twelve years previous to his death he was engaged in the writing of a *Treatise upon General Surgery*. This work he lived to complete; the last page of proof he had read shortly before starting upon his last journey. It is most pathetic that after so many years of arduous toil he should not have lived to see the child of his brain in the form of the published volume. This book, published after his death, remains, in an eminent degree, a fitting monument to the enthusiasm and energy and wide professional mastery which characterized its author.

Dr. Fowler travelled extensively both in this country and in Europe, and always combined with the pleasure of travel a constant search for knowledge that might bring him still nearer to perfection in his mastery of his work.

The work with which the name of Dr. Fowler will, perhaps, the longest remain associated, will be the treatment of general peritonitis; the elevated trunk posture to facilitate gravitation of peritoneal exudations into the pelvis, with provision for its removal therefrom by proper drainage, was first positively brought to the attention of the profession by Dr. Fowler, and under the name of "Fowler's position," has assumed a permanent place among the important methods of combating general peritonitis.

He was married in 1873 to Miss Louise Rachel Wells, of Norristown, Pa. Of this union there are three living children: one daughter and two sons. The sons have both followed in the footsteps of their father; the elder, Russell S., being now his successor as one of the Chief Surgeons at the German Hospital, and as Attending Surgeon at the Methodist Episcopal Hospital in Brooklyn. The second son, Royal H., is in the graduating class of the Cornell University Medical Class, and has recently been selected as one of the internes of St. Luke's Hospital, in New York.

Digitized by Google

Digitized by Google

BOSTON MEDICAL
NOV 13 1907
LIBRARY.

ADDRESS OF THE PRESIDENT.

THE TEACHING OF SURGERY.

By DUDLEY P. ALLEN, M.D.,
CLEVELAND.

A GENERATION in the history of any profession is, seemingly, a short period. The importance of a period may not, however, be measured by years, but by events. Measured by this standard, the generation now passing has lived in one of the great epochs, if not the greatest, in the history of surgery.

One of my earliest memories in the line of surgery is of an old man going about on crutches with an amputation in the middle of the thigh. I was told that the operation had been performed by my grandfather, without the use of an anesthetic.

The first amputation I ever saw was made in the anatomical amphitheatre of a medical school, in order that it might be witnessed by a larger audience than could be accommodated in the hospital. The patient was placed upon a table which but a few moments before had been occupied by a cadaver.

To allow one's memory free rein would trespass upon your time, but, still, it is alluring to recall certain past events. To have witnessed during three years the development of the operation of litholapaxy, in the hands of Bigelow, was most interesting. To have seen his spectacular demonstration of the reduction of dislocations of the hip was a sight never to be forgotten.

No one who ever took the noted course in operative surgery under Langenbeck and followed his clinical teaching will ever forget

Digitized by Google

his painstaking instruction. I heard him remark that no suprapubic operation for the removal of a vesical calculus had, so far as he knew, ever proved successful. All had terminated in sepsis. Should he ever attempt the operation again, he said he would afterward place the patient in a permanent bath, in order to decrease the dangers of sepsis by diluting the urine.

In the height of his powers, no teacher was more brilliant or more attractive than Volkmann. He early discarded the spray. As he flushed wounds every few minutes with a solution of carbolic acid, poured from a height of three or four feet from the spout of a watering-pot, similar to that used in watering flowers, he and his assistants stood in a pool of water and blood. It was, however, his success in treating compound fractures of the leg by this method which revolutionized surgery in Germany.

Billroth's first successful resection of the pylorus astonished the world. To have stood next to him in one of the earliest of these operations is a memorable event. It is no wonder that a teacher at once so brilliant and so genial should have endeared himself to all his pupils.

The surgical clinics of Paris, the operators in full dress, with the wide expanse of shirt front, protected perhaps only by a napkin tucked in above the collar, comes back to one almost as a dream. The charcoal brazier, lighted and having in it the heated irons, still in not infrequent use, carries the mind back at one leap wellnigh to the days of Ambrose Paré.

The great surgeons of the generations past have been our teachers. Their masterly contributions to surgery are our inheritance. We cherish their memory and their instruction. It seems impossible that during a similar period so much advance in surgery can again take place. Certainly it cannot, unless some new light breaks upon us, a light which may perhaps enable us to combat certain diseases, as, for instance, cancer, without the knife. They taught us by clinics and by lectures. Students journeyed far to listen to their instruction. In his introductory lecture on "Anatomy," Oliver Wendell Holmes once asked the question, "Why do men attend universities to listen to lectures which they might read with so

Digitized by Google

much less expenditure of time and money? Why have they always done so? Because," he said, "no printed page ever has or ever can give to teaching the force of the words spoken by a great instructor."

The special theme which I wish to bring before you today is, however, not what has been inherited from the generation fast passing away, but rather how that knowledge may be best imparted to the present generation of students; how to teach them so that they may be not only learned in the knowledge of what has gone before, but may be capable searchers after new knowledge. The question is not only what shall be taught, but how instruction can best be imparted.

In deciding how surgery shall be taught and how much it is wise to give to the average student, it is obvious that the question cannot be answered arbitrarily. The character of the instruction must unquestionably vary, not only with the facilities at the command of various schools, but also with the abilities, training, and characteristics of the individual teacher. As has been well said, "A man may teach most successfully after a method agreeable to himself, but poorly after the prescribed method of another."

It is unnecessary to consider the question of the education of men who are to practise in the thinly populated sections of our country. It is desirable that these sections should have physicians of good general education, but scattered communities cannot, unless for special reasons, attract men of the highest training. The purpose of this paper is to discuss methods of education in schools of the first rank alone.

For men who do not propose to become practitioners, but who intend to do laboratory work exclusively, a limited general training may be sufficient. It is quite possible, however, that a considerable general knowledge of both medicine and surgery would result in directing the investigations of the laboratory workers along lines which would be increasingly beneficial to the clinician.

Every surgeon, in addition to his special field, should be thoroughly trained in medicine. The reasons for this are obvious. No surgeon can be a good diagnostician and a wise counsellor

Digitized by Google

who is not thoroughly acquainted with the various diseases affecting the abdomen and thorax. The recognition of typhoid perforations; the relative merits of medical and surgical means of relieving diseased conditions of the digestive tract; the significance of cardiac lesions, as determining the advisability of operation; the location of abscesses, whether in the lower part of the thorax, in the liver, or in the gall-bladder; the diagnosis of empyema and pulmonary abscess, and how best to evacuate them—all of these demand of the surgeon first-class ability as a diagnostician. In the surgery of the female pelvis, the diagnosis of early pregnancy is often of the highest importance. The lack of skill in this direction has led many a surgeon to cut down even upon a normal uterus at term.

A surgeon of the first rank should be thoroughly intelligent in diseases of the ear, on account of its relationship to meningitis, sinus thrombosis, and brain abscess. Ignorance of the laryngoscope may lead to the extirpation of the larynx for malignant disease when such disease is absent. In a word, though a surgeon should limit his personal service strictly to those fields in which he is a master, he should be sufficiently intelligent in every direction to recognize when he needs advice or aid from men of special knowledge in other fields. He should, most of all, know in what cases medicine can give relief without operative interference. He should be able to decide wisely, not whether an operation can be done, but whether it offers a better promise of benefit than any other method.

It is not long since graduates of medical schools entered upon the practice of their profession with little practical knowledge and less personal experience in surgery. Many of them undertook whatever surgery presented itself. In cases of emergency this was often necessary. The only limit to the activities of some so-called surgeons is the possibility of an operation and the consent of the patient. No one but a surgeon who has carefully watched over the first essays at operations of his own assistants has any conception of the possibilities of error in the operations of a beginner in surgery. The final success of untrained men in surgery has been

Digitized by Google

at the cost of many lives and much suffering and misfortune on the part of many patients. Certain conditions existing at the present time do not tend to decrease the difficulty. Everywhere in towns of but a few thousand inhabitants hospitals are springing into existence. The general public is trained to understand that the possibilities of surgery are great, and that a hospital offers the greatest safety to a patient. The public has not learned that the safety of a hospital depends upon its equipment and administration and the results of operation upon the ability, training, and character of the surgeon. The glamour of operations to the untrained and unskilled, emboldened by a partial immunity from sepsis, gained by a very limited knowledge of surgical technique, has done much to counterbalance what should have been the benefits and security of modern surgery. There is little hope of an early escape from this condition of affairs. The avenue of improvement would seem to be in a full appreciation of present conditions and an advance in the methods of training surgeons. The public will gradually, but inevitably, come to appreciate the vast difference between men called surgeons and institutions called hospitals.

How are men to be trained so as to render the best service to their fellows, and at the same time most efficiently advance knowledge? In studying this question it has been most interesting to compare the varying opinions held by various teachers and schools. A partial summary of some of the conflicting opinions may be of interest:

Opinion 1. A complete course of systematic lectures covering the entire field of surgery is important.

Opinion 2. Systematic instruction may best be obtained by recitations from a text-book, supplemented by the quiz master or by regular lectures covering advances in surgery more recent than the text-book.

Opinion 3. The systematic and comprehensive presentation of the subject of surgery is unnecessary. The thorough mastery of certain of the most important subjects will so train the student's mind that he will himself make good many omissions.

Digitized by Google

In another direction opinions are equally at variance:

Opinion 1. The large clinic given by a teacher of vast experience, able by wise master-strokes to present a picture in proper perspective, giving to an entire class what his time will not permit him to repeat to a number of sections, cannot wisely be supplanted by section work.

Opinion 2. Large clinics are almost valueless. The majority of students see little and profit less than when taught in small sections.

Opinion 3. The student profits chiefly if permitted to serve as an assistant in operations.

There is a wide divergence of opinion as to the teaching of operative surgery:

Opinion 1. Operative surgery taught on the cadaver is of great value in giving an accurate and practical knowledge of regional surgery, the formation of flaps, resections, intracranial operations, etc.

Opinion 2. Operations upon the cadaver are not only valueless, but undesirable, since they teach carelessness, as compared with operations upon the live tissues of animals. Operations upon animals, on the other hand, conducted with strict asepsis, are of the greatest benefit in inculcating the principles of surgical technique, and the method may be made equally valuable in diagnosis and treatment.

Opinions are also divided as to the elective system in the study of medicine. Some would dispense with all didactic teaching and large clinics during the last college year, and instruct students solely in small sections, or utilize them as assistants in hospital wards and at operations. Without wearying you further with details, it is evident that the methods followed by various schools differ greatly. It is also evident that we are departing widely from the precedents set by our predecessors and by the faculties of foreign universities. There is one point, however, upon which it would seem there can be but little difference of opinion.

When one considers the vast increase there has been in medical knowledge, the far greater proportion of time now given to labora-

Digitized by Google

tory instruction as compared with former years, and the great development of instruction in what are called the special lines of practice, it is evident that it must be impossible in four years to give any student what might be termed training as a specialist in any one branch.

The great misfortune of the specialist of the present day is his inadequate knowledge of other departments than his own. To begin to specialize during a four years' course of study is to breed narrow men. Unquestionably a general hospital training after a full course of study would be of great value even to one intending to become a specialist. He would then have the broad foundation upon which to build, and would more properly deserve the respect due to the man of special knowledge. On the other hand, since ignorance of the lines of special practice must be a great misfortune to every man, and most especially to the general practitioner of medicine and surgery, it must be of the greatest value to give to every student well-devised and well-proportioned instruction in what are called the specialties.

Every Fellow of this Association must have been a frequent witness to the misfortunes which have resulted from the lack, not only of general, but also of special training.

Should it be granted that four years are not more than sufficient to give to students thorough training in the general lines of medicine, obstetrics, and surgery, and an intelligent appreciation of special lines of practice; and should it also be granted that the student who intends to become a surgeon can attain the necessary knowledge only through hospital residence and postgraduate study in various hospitals, both at home and abroad, how may the time assigned to the teaching of surgery be best employed?

To be dogmatic in the discussion of this subject would evidently be inappropriate. Unquestionably, the end may be obtained by a variety of methods. No two institutions, no two men, can follow exactly the same method with equal success. Certain things, however, seem fundamental. All students should have an intelligent comprehension of what surgical disease is, and the results it produces. This can only be taught by the study of surgical path-

Digitized by Google

ology. Brilliantly as this is taught by some schools in the United States, it is my observation that both in this country and abroad there is no subject in which it is so difficult to secure satisfactory instruction.

The student should be thoroughly drilled in diagnosis, and though much valuable instruction may be given by the experienced teacher before considerable numbers of students, better than can possibly be given by teachers of less breadth of knowledge to small numbers, there can be no question that the intimate instruction given to small classes, bringing each student in close contact with the patient, is of vast importance. The departure made by some schools in this direction is a great advance. Both methods are, however, desirable.

The student should also be taught to write accurate histories of his cases. An accurate history cannot be written without an accurate and painstaking examination.

It would seem wise, also, that every student should have a fairly comprehensive knowledge of surgery. This will be of benefit to the future physician, enabling him to know when he may turn to the surgeon for timely aid. It is essential to the surgeon. It is, of course, impossible, with the time given to the teaching of surgery, that it should be too minute in special directions. Exhaustive instruction in certain lines might mean the total neglect of others. How can this comprehensive knowledge be obtained?

Teachers who command so abundant clinical and pathological material as to enable them to present large groups of clinical cases at the same time from a clinical, a therapeutic, and a pathological standpoint, can afford students unusual opportunities for the acquirement of knowledge. Few have such facilities. How may others with smaller material give systematic instruction? Four methods, variously combined, are in common use in this country: (1) Recitations from a text-book, supplemented by the remarks of the teacher. (2) Regular lectures followed by the quiz. (3) Clinical instruction, with remarks upon the various cases. After a sufficient number of cases along a given line have been demonstrated, the teacher summarizes them and presents the subject in

Digitized by Google

its general bearings. (4) Teaching chiefly in small sections, with the instruction and quizzing incident to it, a limited amount of systematic teaching, so called, being given.

It would be presumptuous to say what is the best method. It is certain, however, that the repetition of his knowledge by the student in written reports, in the recitation, the quiz, or the section work, has two great advantages, viz: (1) The student can only make accurate statements if he has accurate knowledge. (2) The failure of a considerable number of students to demonstrate their possession of accurate knowledge must prove to the teacher that he has signally failed in his instruction.

A remark once made to a teacher whose examinations were especially severe, and who usually "plucked" half of his class, was most appropriate. His associate said: "I should be ashamed if I should teach a class of students so that so large a proportion would fail to pass my examinations."

The student, whether by recitation, by discussion, or by written report, should continuously be required to demonstrate the accuracy of his knowledge. It would doubtless be of the greatest value to him to be stimulated to investigate and report upon certain assigned themes requiring both reading and special study. He would thus necessarily be led to think for himself. The tendency of our American teaching is to overburden the student with teaching and so to fill up his time that none remains to him in which to do anything along individual lines. As a result, too many students leave college crammed with facts, but lacking in the ability to work independently, and to increase their knowledge by their own initiative at a later period. Thus it would seem that, first, some quizzing at least on the part of the lecturer himself would be beneficial both to the student and the teacher. Second, that quizzing in small sections, commonly in connection with clinical cases, would be an absolute essential, and, third, that the seminar, discussing with the student, before his fellows, work performed by himself would be of the greatest value. By whatever method it is accomplished, it is desirable that the instruction should be so comprehensive that there should remain no important subjects in surgery upon which the

Digitized by Google

student is not at least intelligent. He should also, so to speak, be made, not only a consumer, but a producer of knowledge.

The teaching of surgical pathology is most important. As has already been said, this is as a rule most inadequately done. Few schools have the requisite facilities. It is of value to understand this subject from the general viewpoint. It is of greater value still, if to a general knowledge of the gross and microscopic specimens can be added a study of specific cases seen clinically. This is very rarely done. Were it done, more men would be led later in practice to follow their clinical material to the laboratory, and from its study be able to increase the accuracy both of their diagnosis and prognosis in many cases. The closer contact of the clinician with the laboratory worker would also doubtless aid the latter in the formation of opinions valuable to the former. It might also bring about another result much to be desired. Many things, the product of laboratory investigation or experimentation, have been offered to the clinician as of diagnostic or therapeutic value. We have been living in the age, as it were, of the laboratory. The whole profession has welcomed its labors and its discoveries.

The greatest money expenditure in teaching has been for the laboratory. Everyone rejoices in its great development. Everyone acknowledges the value of the laboratory method. At the same time there can be few clinicians who have not had reason for grave disappointment many times, when they have felt compelled to put aside conclusions reached through long clinical experience and be guided by those from the laboratory, on the ground that the latter alone were reliable, only to find that they had erred in so doing. There has been, and still is, a vast amount of fetich about laboratory findings and instruments of precision. When, years ago, in Cohnheim's laboratory, I had worked long and without being able to reach a conclusion upon some microscopic specimen, I often turned to one of his subordinates, who usually could explain the specimen at once. Still remaining unsatisfied, I have turned to Cohnheim himself. In his kindly way he would sit down and study long and carefully, and perhaps say at length, "I am uncertain what that specimen is; you had better ask Professor Weigert,"

Digitized by Google

a distinguished authority then associated with him. Cohnheim, one of the most inspiring teachers of his age, was great enough to recognize his limitations. The findings of the laboratory, prized as they are by all of us, are no more accurate than the accuracy of the investigator who makes them. The vast intricacy of the problems under investigation makes of little value the results obtained by any save the thoroughly competent workers. Much that is published at the present time as research work has absolutely no value except to advertize the man who writes it. These published conclusions would not be accepted so unquestionably by the clinician were the clinician so trained in laboratory methods as to be a competent judge of their value. Could the student bring into close association his clinical material and his physiological and pathological training, bringing the one to bear upon the other, it would doubtless be greatly to the benefit of both laboratory and patient. The application of laboratory findings to the clinic would be more efficient, and the clinician would doubtless learn more accurate diagnosis through acquaintance with thorough laboratory methods.

The question of how best to teach surgical technique and operative surgery is now under active discussion. That instruction in this department of surgery should be given early in the teaching of surgery seems wise. It is desirable that students should early comprehend asepsis and the details of operations. The teaching of these upon dogs seems a distinct advance, since the details of asepsis can be taught as accurately in this way as in any other, and the method has the advantage that errors do not jeopardize the life of a patient. Operations upon live tissues give opportunity for genuine training, comparable to operations upon human beings.

It does not seem equally clear that the teaching of operative surgery upon the cadaver should be abandoned. If cadavers which have not been hardened by preservatives are used, it is possible to teach the student much about the formation of flaps, the resection of joints, the ligation of vessels, certain operations upon the skull, etc. It teaches him also that operation and dissection are two different things. In the days before the advent of

Digitized by Google

anesthesia, dexterity and despatch in operating were essentials to success. To witness the dissecting and dilatory methods rendered possible by anesthesia and asepsis, methods now too commonly in vogue, is a distinct step backward. Even though contused and lacerated tissues may heal under asepsis, it in no manner argues against the desirability of operating with clean-cut incisions, the minimum handling of tissues, and the greatest despatch compatible with accurate work. Is not the human body still the best object upon which to practise certain operative procedures, and will there not always remain great value in familiarity with the various important surgical regions of the body from the standpoint of applied surgery in addition to that of anatomy?

Among the later departures in the teaching of surgery is to do away largely or entirely with any systematic or class work during the fourth year of college. I wish to say here emphatically that I believe this is a bad plan. Instruction for short periods in sections, although of the greatest value, can never take the place of instruction given by the clinician. Section teaching is most laborious and time-robbing. The teacher wearies of repeating the same instruction several times during a semester. He will have lost his enthusiasm after several repetitions. The fate of such instruction must be that it will be abandoned to the younger men. Some of these young men will do admirable work; some will do very ordinary work. The teaching of the various sections of a class will be unequal. No one will question the desirability of section teaching. What is questioned is the plan to abandon, during the fourth year, all systematic instruction to the class as a whole. The dogmatic teacher is always popular. There will always remain, however, an important place where the clinician of great experience can give to students a broad view of surgery unattainable in any other manner. Should medical colleges ever be able to command the entire time of a surgeon, as a teacher in a university clinic, desirable as this would be, it would never render undesirable the added teaching of the broad clinician.

There remains for consideration the question of electives. While everyone will perhaps grant their desirability for men who expect

Digitized by Google

to pursue laboratory courses alone, their importance for men who are to practise medicine or surgery is an entirely different question. As has already been said, it is most desirable that every student should be thoroughly grounded in the knowledge which is fundamental to the practice of his profession, and it is also important that he should be equally intelligent in what are called the specialties. If he does not have this knowledge he may fail to secure for his patient the help of which he stands in greatest need. There is, however, at the present time, no greater curse in the profession and the community than the specialist, falsely so called. It is time enough to put up a sign-board pointing the student to special lines of practice when he has completed his regular course in the medical school. Four years are all too short for the acquirement of sufficient knowledge. Our neighbors in Canada will soon require five years. Across the sea, six years have long been requisite. I believe we will do better to train men systematically for four years. The time is not far distant when five will be required. After a systematic course of training it will be time enough for men seeking to enter special fields of practice, to gain by hospital service and postgraduate study, here and abroad, the more advanced knowledge absolutely necessary to entitle them to offer their services to the profession and the public as possessed of special knowledge.

No training is more valuable to a young man than to serve under a capable surgeon as an assistant in a hospital. Such assistantship should be sufficiently long to give breadth of observation and an opportunity to do operations. The interneship common in most hospitals is inadequate to such training. The residence should be longer and the opportunities more ample. Haste has no place in the training of a surgeon. It would be of great value if after the ordinary interneship selected men could be retained for a longer period as assistants, supervising the body of internes. It is also very desirable that these men should be actively engaged in working up the pathological material coming from the surgical clinic. Combined clinical and pathological knowledge thus obtained will train a body of young surgeons which must unquestionably com-

Digitized by Google

mand the respect of the entire profession and the confidence of the public. Young men thus trained will preserve the best traditions of the past, and contribute to the knowledge of the future. The answer to the question of how to train men to become surgeons is to train them thoroughly.

There remains for consideration a difficult question. How may a standard of surgical knowledge be established, the attainment of which will gain men general recognition? Combined action on the part of State Examining Boards is seemingly unattainable. It is a question if a national examining board could be created whose findings would be mandatory upon all States.

The American Surgical Association could create itself a National College of Surgeons and hold annual examinations. Only those passing this examination would be eligible to Fellowship. The eligibility to such Fellowship and the certificate of having passed such an examination would at once give a man a recognized standing. It would commend him as a thoroughly trained man to any community in the United States where he might wish to live. Doubtless such a certificate would gain recognition abroad. To formulate a wise plan would require mature deliberation. Is it not worthy of our consideration?

Without longer trespassing upon your time, the purpose of this paper may be summarized in a few words:

It is to urge for the training of surgeons: first, thorough and broad instruction; second, prolonged hospital residence and post-graduate study; and, third, the establishment of some standard of attainment which must be reached by men to gain them general recognition by the profession. If these ends be attained, the community and the general profession will not long remain in doubt as to the men who are deserving of their confidence and support. Such a standard would do much to protect the public from incompetent men and to place in the hands of capable surgeons those facilities, which they alone are able to utilize to the best development of their profession and the best interests of humanity.

Digitized by Google

SPINAL ANESTHESIA.

By PROFESSOR KUSTER,
MARBURG, GERMANY.

MR. PRESIDENT AND GENTLEMEN: First let me thank you very cordially for the honor you have done me, in inviting me to address an assembly such as the American Surgical Association, which, in a few years, has attained a position among the foremost scientific societies of the world.

I propose to speak of spinal anesthesia, as this excellent remedial agent is being used for operations in Germany more and more extensively, although it appears that in America it is still regarded with great mistrust. This is certainly due to the fact that, from time to time, it has resulted in failure, paralysis, and even death. Still, I hope to be able to prove to you that, at the present day, this mistrust is no longer justifiable.

Here is a brief account of the discovery: In 1885 an American, Corning,[1] published his first contribution on "Spinal Anesthesia and Local Medication of the Cord." In 1888[2] and 1894[3] further works by the same author appeared, in which he accurately described his procedure. It appears from them that Corning's original idea was to influence the spinal cord medically by means of injecting the medicine as far as the region of the dura mater, in the supposition that the vascular connection of the venæ spinales with the plexus spinales internæ would rest upon the spinal cord. It is only in his 1894 publication that he also devotes his attention

[1] New York Medical Journal, 1885.

[2] Corning, A Further Contribution on Local Medication of the Spinal Cord, with Cases, Medical Record, March, 1888.

[3] Corning, Pain in its Neuropathological, Diagnostic, Medicolegal and Neurotherapeutic Relations, Philadelphia, 1894.

Digitized by Google

to injections into the dura mater itself and describes the process, which at that time was very imperfect. But his only object was a *curative action* on the spinal cord; there was no suggestion of applying it to surgery as a useful form of *anesthesia*. Indeed, that method of sweating the spinal cord was, apparently, not considered in any way. Hence, it is not feasible that Corning should be quoted as the first who applied spinal anesthesia to surgical purposes.

Meanwhile, in the year 1891, Professor Quincke[1] had recommended the puncture of the vertebral column for the reduction of intracranial pressure by diminution of the cerebrospinal fluid, and, as the result of his anatomical studies, had prepared a special technique for the small operation. According to Professor Bier's own admission, this gave the initiative to experiments in lumbar anesthesia, and his first communication on the subject appeared in 1899.

The Anesthetic Drugs Employed in Spinal Anesthesia.

The first drug with which Bier tried successfully to produce spinal anesthesia was cocaine. But it was soon evident that this was a dangerous method: for one thing, because it had a strong irritant action upon the spinal cord, and had general toxic characteristics, but chiefly because it could not be sterilized with certainty without becoming decomposed. Therefore, every injection into the dura mater was liable to cause infection. Experiments were then begun by manufacturing chemists with the object of producing a new and harmless drug; but all these—tropacocaine, eucaine, and stovaine among others—failed to fulfil the condition of being completely harmless. We know, too, now that the widely lauded stovaine can have a fatal action (see the famous case published by Fritz König). It is only in novocaine, which two years ago was placed on the market by the manufacturers at Höchct on the Main, that finally a drug seems to have been found which has a certain action and is at the same time without danger,

[1] Die Lumbalpunction bei Hydrocephalus, Berliner klinische Wochenschrift, 1891.

Digitized by Google

especially if, as Braun recommends, it is supplemented by suprarenin. This mixture is regularly prepared in the little bottles obtained from the Höchct manufacturers, as suprarenin has an anesthetic action, which novocaine not only does not limit, but assists. The formula for the fluid contained in the ampulla is as follows: Novocaine, 0.15 gram; suprarenini borici, 0.000325 gram (5 drops of suprarenini borici 1 to 1000), in 3 c.c. water, which is to be seen on the label.

I propose to give you the results of my experience in almost 300 anesthetic cases, in the hope of gaining new supporters for this excellent method. Some of the observations made in my clinic were published at the end of the last year by the head surgeon, Dr. Henking.[1] We have applied novocaine in all suitable cases, therefore, in all operations on the lower extremities, the pelvic region, the genitals and region of the lower abdomen, and up to the umbilicus. This method is also very suitable for examinations of this region and for the introduction of instruments. At the same time, I have frequently and successfully gone above this line in order to perform operations on the stomach, kidneys, and gall-bladder. Nevertheless, when operating on the upper abdominal region it is sometimes necessary to have recourse to special remedies, *i. e.*, those of general narcosis, but prepared in a special manner.

Anatomical Conditions.

The spinal cord ends at the lower edge of the first and at the upper edge of the second lumbar vertebra with the conus terminalis, from which point the filum terminale, containing the nervous coccygeus, runs to the lower end of the dura mater, *i. e.*, as far as the apex of the second or third sacral vertebra. This deep segment of the dura mater is supplied by the powerful strands of the cauda equina, which, according to the representation of Quincke,[2] contains a narrow, downward-pointing fissure

[1] Erfahrungen über Lumbalanaesthesie mie Novocain, Münchener mediz. Wochenschrift, 1906, No. 50.

[2] Ueber Lumbalpunction Die deutsche Klinik am Eingange des 20ste Jahrtuadechs, Band vi, Abeil. 1, Berlin, 1902.

Digitized by Google

between it and the subarachnoidal cavity. It is supplied with cerebrospinal as well as the entire dura-mater fluid. Dönitz[1] proposes to indicate this cavity as the cisterna terminalis. The motor and sensory roots of the cauda are still separated from each other here; the motor lie united in a thin mass in front, the sensory behind and, indeed, in such a way that the front dura-mater cavity can be reached only with some difficulty from the posterior segment. It is, therefore, clear that a puncture which exactly hits the middle line and also the cisterna terminalis is more certain to admit an increased amount of the fluid than if the point of the needle were introduced sideways between the columns of the cauda.

Technique of the Method.

It is best to seat the patient on a table with his bare back turned backward. But in cases in which he is very weak, or suffers intense pain when sitting, the puncture can be made in lateral position, but at the same time the back must be strongly curved, as in this way the points of the spinous processes become slightly separated and the needle can then be inserted more easily and accurately. After the field of operation has been cleared of hairs, washed thoroughly with soap, and rubbed with alcohol, a sterilized cloth is held by an assistant in such a manner that its edge is stretched tightly across the upper edge of the intestinal crest. The connecting line touches the fourth interspinal cavity; either this or the third is selected for the puncture.

The puncture is made with the syringe designed by Bier, and contains 2 c.c. Take one of the small bottles procured from the manufacturers, which contains the above-mentioned 5 per cent. lotion of novocaine, with the addition of suprarenin: knock off the neck of the bottle with a knife, and empty the contents into the syringe. Now take the hollow needle, inspect it with a stiletto, and hand it to the operator, who, in the meanwhile, has found the correct place on the patient's back and

[1] Technik, Wirkung und specielle Indication der Ruckenmarks-Anaesthesie, Verhandl. der deutschen Gesellsch. f. Chirurgie, 1905, Band xxxiv.

Digitized by Google

secured it by keeping his index finger on it. The syringe is placed accurately in the middle line and prevented from emptying by holding it between two fingers of the left hand, the needle being pressed in a downward position through the skin and interspinal ligaments. Occasionally the needle tends to incline sideways, but it

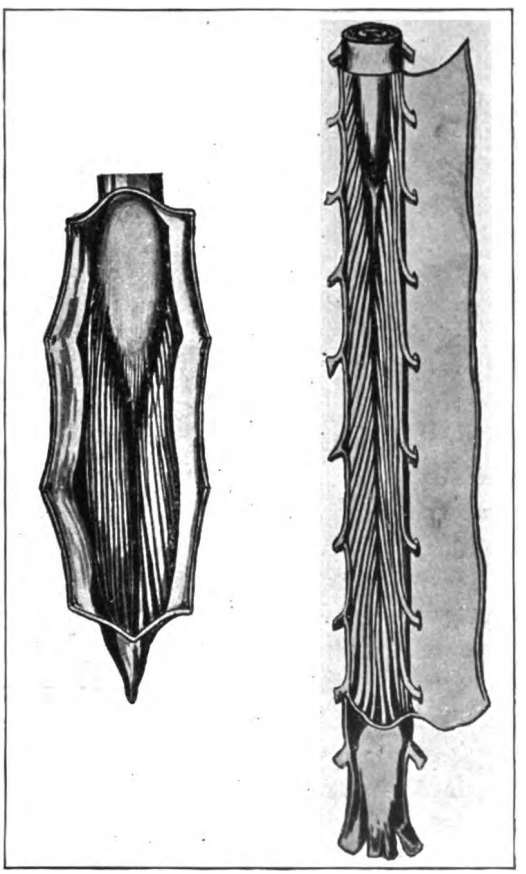

must be held in the right position by the fingers. If, as one proceeds, any bony obstacle is encountered, then the point should be drawn back a little, and a fresh way through the dura found by means of probing, which can usually be easily done in an upward direction. When one has got away from the bony wall, it

Digitized by Google

is best to take the stiletto out and probe for the dura with the needle alone, directly the point has bored through this and the arachnoid; the fluid, which at once begins to flow, indicates the correct position of the needle. This process has the great advantage over boring with the stiletto, that the latter must be repeatedly withdrawn and again inserted in order to know whether the fluid is already flowing or not.

In all circumstances the appearance of clear fluid must be waited for, as otherwise we have no certainty that the needle-point has really penetrated the arachnoid space. If the fluid is bloody to begin with, it must be allowed to flow until it has become clear; but if apparently pure blood comes, then it is better to withdraw the needle and reinsert it for a fresh puncture in the next upper intervertebral space. Such a condition, however, evidently caused by interference with the interspinal venæ plexus, is very rare if the stiletto is withdrawn and the needle inserted half-blunt.

The quantity of fluid which follows the needle varies widely. Sometimes it comes in a stream, at others only drop by drop; or there may be no clear fluid come at all, although one is certain of having attained the dural space. It has been assumed that these phenomena are due to the high or low pressure existing in the spinal channel, but this explanation is without doubt unproved; for if the needle is withdrawn, a stream of fluid can usually be obtained by turning the needle around or reinserting it at another point. Therefore, it is evident that it is only a question of mechanical obstacles; and, if the anatomical conditions are considered, one must at once conclude that the flow is only absent, if the cisterna terminalis has been penetrated between the strands of the cauda equina, where there is room for very little fluid.

Up to the present it has been usual to make the injection directly the fluid began to flow. This procedure, however, is not to be recommended, as it appears often to cause more unpleasant after-effects, as if the pressure in the spinal cord had been diminished. For some time, therefore, I have first allowed a stream of fluid to flow which was relatively equal in quantity to the amount about to be injected. In February last Mr. C. Canny

Digitized by Google

Ryall, of the Kensington Hospital, London, while visiting me, drew my attention to the fact that if 15 c.c. of the fluid was methodically sucked out there were hardly ever unpleasant after-effects. I have borne this proposition in mind in a number of cases of injection of novocaine, have increased the aspiration up to 15 c.c., and have sometimes found Ryall's opinion confirmed; still, my experiments have not been sufficiently numerous for me to be able to assert that headache and other unpleasant symptoms never occur. I have recently had one case of headache.

For operations on the pelvis, even with adults, the injection of 2 c.c. novocaine-suprarenin solution is sufficient; but in operations on the extremities and the abdomen, as well as on those above the umbilicus, the entire contents of the small bottle of solution—namely, 3 c.c.—are required.

Immediately after the injection has been made the head of the table on which the patient is lying should be lowered considerably, so that the pelvis is raised; when in this position the patient's hands should be held tightly, or the forearms should be strapped together. The anesthesia should now be tested by pricking the patient with a sharp instrument, especially on the part about to be operated on. If this has become anesthetic, the operation can now be commenced.

Meanwhile, as Dönitz has demonstrated by experiments at the Clinique of Bonn, one can cause the anesthesia to be extended to a certain degree, partly by means of a kind of pelvic presentation (keeping the pelvis in position), partly by head obstruction. In pelvic presentation the mechanical factor certainly plays an important part; the novocaine solution flows to the posterior surface of the spinal cord and outward to the subarachnoidal spaces, and acts upon the part of the spinal cord with which it comes in contact. But anesthesia is rarely induced in this way, then only after waiting, sometimes as much as ten minutes or even longer in the region of the umbilicus. The sooner the patient can be again laid horizontally, the more certain is the anesthesia to remain limited to the lower extremities and the pelvic region. But as regards head obstruction, that is another matter. As Bier has

Digitized by Google

shown, this causes an increase in intracranial pressure, while at the same time the obstruction of the veins of the brain forces the fluid downward. If, however, the bandage is removed there is at once a strong efflux of the fluid already in the vertebral canal to the cranial cavity. If before making the injection a bandage is placed around the patient's neck and again removed after the incorporation of the fluid a stream flows upward, drawing with it the anesthetic from the lower segment of the dural cavity, before it has had time to accomplish its action there; consequently, the limbs may remain almost entirely sensitive, while the trunk is anesthetic as far up as the first rib. But this action may be further augmented if, according to Ryall's suggestion, 15 c.c. of the fluid is allowed to flow before the injection is made. Then, after the bandage has been removed, the mixture is more certain of flowing upward. This is a procedure which should be carefully noted in operations on the upper abdominal region.

Paralysis should, *a priori*, be regarded as motor as well as sensory; in reality this is often the case and is, in fact, regarded as the rule in the observations of many. In my experience, however, it is the exception; that is to say, while there is complete sensory paralysis the motor may be absent altogether, or only very slightly indicated. This is explained by the fact that the ligamentum denticulatum and the cauda equina separate the posterior portion of the arachnoid space—that is, the sensory nerves and posterior segment of the spinal cord from the front segment, in so far that the injected fluid can only reach them with a certain difficulty. If after the injection the patient is at once laid flat, with the pelvis raised, the difficulty of the flow is overcome and the posterior portion of the spinal wound should be rinsed out.

I observed unilateral sensory paralysis three times in the first 160 cases, but have not done so since. This is explained by the fact that later I almost invariably made the injection with the patient in a sitting posture and always in the middle line; and naturally, too, by the improved technique.

Digitized by Google

Course of the Anesthesia and Failures.

As a rule, at the end of from five to ten minutes the patient is so completely anesthetic that the operation can be commenced; it is recommended, however, as his anxiety may not be sufficiently appreciated, that the patient's face be covered with a thin cloth, which admits of his being watched by an assistant. If their attention is distracted by conversation—and this is particularly advisable with children—they appear to take so little notice of what is being done that during the whole operation they will not evince a single sign of pain. It is only when there is severe tearing of the front portion of the peritoneum, or of the spermatic cord, that they are liable to groan; if, however, they are asked whether they are in pain, they will generally reply that there is an unpleasant sensation, or that they feel sick. Occasionally they may vomit, the face becomes pallid, and sweat breaks out on the brow. But in the greater number of cases everything passes off peacefully; even in very great interference, such as disarticulation of the hip-joint; it will be exceptional if there is any slight evidence of shock.

In rare cases the remedy seemed to fail, but I now believe this was due to slight impatience and because one did not wait long enough. I have then had recourse to a suggestive narcosis, that is, a few drops of ether have been poured on to a mask and placed before the patient's face. The operation can then almost without exception be commenced and accomplished painlessly. It is only in very rare cases, with highly excitable patients, that I have been obliged to induce general narcosis.

After-effects.

For most cases the anesthesia is so perfect that there is no disturbance, even in prolonged operations. At the same time, it is advisable to at once utilize the time when anesthesia has been induced, as it varies in duration. Sometimes, at the end of forty-five minutes, the patient is observed to become rather restless and to groan, although this is frequently only due to a strong feeling of

Digitized by Google

sickness and a desire to vomit. But on an average, at the end of an hour and a half the action of the anesthetic will be over, and the patient will begin to experience genuine sensations of pain.

As a rule, after the cessation of the anesthesia the patients feel perfectly well and accept the nourishment offered them with considerable appetite. Some, who at the same time experienced motor paralysis—as already mentioned, only a very small number—assert that they still feel a sensation of weakness in their legs, which, although it does not prevent their walking, makes them limp a little. After a few hours the power of movement is completely restored. Still, it is noteworthy that sensation more quickly returns to the normal than does the capacity of movement.

With regard to the ill effects which accompany lumbar anesthesia, the principal one is headache, which in the first 200 cases appeared in about 14 per cent. This can become very violent and last several days, so that the patients suffer intensely. We possess, however, an excellent remedy for it by the renewed puncture of the dural cavity and drawing off about 10 c.c. of fluid, as first recommended by Chaput.[1] This method acts like magic. Directly after the operation the patients declare that their heads now feel completely relieved; the pain has disappeared immediately. This was the case in March with a boy of nine, who before had suffered severely, but directly after the puncture became bright and in good spirits. This method has only failed in one case. The patient in question was a man of about thirty, who had been operated on for hemorrhoids. He had previously suffered from severe headaches and was very ill the day of the operation. A renewed puncture, made the following morning, brought him no relief. The pain lasted with varying violence for six days, and was not relieved by pyramidon, which is highly recommended in such cases as a curative remedy; it was only at the end of this time that the pain became milder and gradually disappeared.

A second case is also worthy of note: A man of thirty-five had been castrated because of sarcoma of the testicle. As he also suffered from headache, which increased in violence, a lumbar

[1] Centralblatt f. Chirurgie, 1906, Nr. 26.

Digitized by Google

puncture was performed at the end of two days. The fluid drawn out looked cloudy and contained diplococci. Nevertheless, the headache disappeared at once, and recovery took place without any further disturbance.

Before we pursued this method of treatment we once saw a case the symptoms of which could only be described as aseptic meningitis. There was violent sickness, together with stiffness of the neck, severe headache, and sensibility to touch of the spinous process of the cervial segment of the vertebral column. But at the end of four days the disturbance disappeared spontaneously. Having regard to the previous observation, one cannot help presuming this might have been more rapidly and surely overcome by means of lumbar puncture.

Henking in the report of our first 160 cases refers to a number of after-effects which we seldom meet, thanks to a more perfect technique. The following cases are among them:

A boy aged twelve was operated on for purulent epityphlitis; six days later epileptiform spasms appeared, which affected first the right and then the left side of the face and gradually extended to the upper extremities. The boy was completely dominated by them; every movement brought on a spasm. Recovered after a repuncture.

In another case, that of a man aged twenty-eight, twelve hours after the injection great restlessness appeared, which became almost maniacal and persisted for sixty hours. It then disappeared after a large dose of morphine; but the headache continued for six days longer. Here, also, in all probability, a lumbar puncture would have proved effectual more rapidly.

Once, at the end of fourteen days, paralysis appeared which persisted for three weeks; paralysis of the bladder and rectum occurred twice, and also disappeared at the end of eight to ten days; finally, paresis of one leg was observed once.

Fever has only occurred once, on the day of the injection.

On the other hand, we have only once seen slight pneumonia after an operation for epityphlitis, in which, as a matter of fact, general narcosis was also employed. It ran its course in two days.

Digitized by Google

There was no doubt it was a case of embolus. We may, therefore, conclude from our observations that lumbar anesthesia is a protection against the frequent and dangerous postoperative pneumonias. This opinion is in marked contrast to many observations in which pneumonia is frequently referred to; for example, at the Breslau Clinic it is asserted that pneumonia has not decreased at all under lumbar anesthesia. But when one reflects that the majority of postoperative pneumonias are due to the aspiration of phlegm or saliva during profound narcosis, one must conclude that similar results cannot follow operations performed during complete consciousness. I consider, therefore, that the prevention of pneumonia through aspiration is one of the most powerful arguments in favor of spinal anesthesia.

The question as to whether in spinal anesthesia there is a possibility of its causing degeneration of the spinal cord, even after the lapse of years, may be touched upon here. This form of local anesthesia has already been practised for nearly eight years, and the most varied drugs have been employed, without a single case of subsequent illness having been reported in literature; so we may look forward calmly and confidently, without anticipating the appearance of any. As novocaine especially is proved to be more certain in its action, and as acute disturbances of a threatening nature are manifestly of the rarest occurrence, we may confidently assert that in the future neither early nor late processes of degeneration need be anticipated. Consequently, I have not hesitated to resort to spinal anesthesia several times with the same person. Thus, in one case of novocaine anesthesia I have employed it five times on a man aged sixty-five, without so far any apparent harm resulting.

Statistical Observations.

Up to April 1st of this year lumbar anesthesia in my clinics has been induced 290 times, of which 208 cases were men and 82 women. The youngest individual who submitted to this treatment was a child aged five years; the oldest was a man of seventy-seven. There was no noteworthy difference perceptible in the behavior of the two sexes; but age, on the other hand,

Digitized by Google

made a certain difference. With children the small operation is always particularly easy, because of the wide opening between the vertebræ. Consequently, they suffer so little from the simple prick that in the children's portion of my clinic, they have a great preference for this remedy in operations, as contrasted with general narcosis. Children, when brought into the operating room, nearly always beg for a "Pieks" (prick), and detest the "little cap," as they call the narcosis mask. Spinal anesthesia is a great advance in the struggle to combat and avoid the operative pain of a wound. It is also of the greatest assistance to us when making examinations of the pelvic organs and of the abdominal cavity, especially in the cases in which pain or reflex muscular contraction augments the difficulty of the examination. The method appears to be less dangerous than general narcosis, as it does not immediately threaten life, and also does not induce any serious after-effects; pneumonia in particular, caused by inhaling irritating substances—*i. e.*, pneumonia by aspiration—appears to be entirely prevented. The method does not, as a rule, affect the health by any means as much as general narcosis; so that it can be employed without danger even in the cases of weak, delicate, and suffering people, and those who are afflicted with severe disorders of the internal organs—the kidneys, heart, etc. It is, therefore, worthy of the most comprehensive regard and development.

I shall rejoice if my address is the means of extending the field of this method of operative surgery, and procuring for it a wider range of usefulness than has hitherto been the case in America.

Digitized by Google

DISCUSSION.

DR. THOMAS W. HUNTINGTON, of San Francisco.

In opening the discussion upon the excellent paper by Professor Küster, I wish to say that in entering upon the work described by the reader, I believe that no person ever employed spinal anesthesia with greater unwillingness or with more doubt as to its legitimacy than myself. I appreciated what seemed the great risk in approaching so important a structure as the spinal canal by the prescribed method. Urged, however, by my associates and influenced materially by the experience of colleagues, I concluded two years ago to give it a fair test. We engaged in the undertaking systematically and for a time employed spinal anesthesia whenever it was applicable in adults. We have never attempted it in early childhood, for obvious reasons. My observations are closely in accord with those of the reader, with one or two possibly essential differences.

The drug of our choice has been tropococaine instead of novocaine, and have used as a solvent the spinal fluid, employing from 2 to 4 c.c. of the spinal fluid for this purpose.

We have come to think that this method of administration is of very great moment. Rarely have our cases suffered from headaches or nerve disturbances, while in our earlier efforts with cocaine these were not uncommon and were sometimes exceedingly annoying. Without exception there has been satisfactory anesthesia below the point of administration. Patients lie passively during operation and have been free from all the terrors which were depicted so brilliantly by those who have decried the method without extensive experience.

The one thing which has impressed us most, the thing which has convinced me that spinal anesthesia has come to stay, is the postoperative comfort of the patient. Go to the bedside of patients operated upon from two to four hours previously and you will find them lying comfortably, some taking their meals as usual, some sleeping, and none of them suffering from postoperative vomiting. Shock is greatly minimized and in ordinary cases it is unnecessary for nurses to hover over the patients in an effort to relieve distress.

I believe this one feature is sufficient to convince the person with experience that we have in spinal anesthesia a means of eliminating postoperative distress, discomfort, and pain, which is perhaps superior to all other anesthetics.

Personally, I am willing heartily to endorse spinal anesthesia when properly conducted.

Digitized by Google

DR. A. T. BRISTOW, of Brooklyn.

Some three or four years ago I did about fifty operations at the County Hospital under cocaine anesthesia. I have had no experience with any of the other narcotics, but I would like to detail my experience in these cases. In the first place the patients suffered, as a rule, a good deal from headache; this was extremely persistent and severe, lasting in one case for three weeks. Vomiting also was frequent. Then, again, I was not always sure of my anesthesia. In two-thirds of the cases it was satisfactory, while in one-third it was most unsatisfactory. In operations on the cord for varicocele, etc., I got practically no anesthesia. I had, moreover, a series of six cases of postoperative insanity I reported at the time. Professor Küster has suggested a similar case of his own in which a maniacal condition existed after spinal anesthesia. In six of these cases, after the use of spinal anesthesia, the patients developed illusions of persecution which lasted from two to three weeks. One man, an electrician, got the idea that the hospital was running electric currents into him to destroy him. Another said that his relatives were seeking to poison him. They all ultimately recovered.

I was not so unfortunate as to have any paralysis or infections. For one thing, I invariably, before introducing the needle, make a slight puncture with the scalpel, in order to avoid passing the needle through the infected layer of skin.

The cases of mania were most interesting to me, and so far as I know, after having made inquiry in New York, I am the only surgeon who has had such cases.

DR. SCHMIEDEN, of Bonn (by invitation).

It is my intention to add but a few words to the paper under discussion on "Lumbar Anesthesia," and that is with reference to the indication as observed at Bier's clinic.

As you know, Bier has spared neither time nor effort to perfect the method in every direction. Yet he had often been the very one to condemn too geat enthusiasm, which can only hurt even the best of causes. The extension of the field of application must keep pace with the progress of the technique, but must not precede the same. We want to use lumbar anesthesia only where it is absolutely safe.

We know very well that occasionally lumbar anesthesia may be extended up to the shoulders, but we do not at present advise this for practical purposes. We use it in hernias and all operations below Poupart's ligament (rarely in the case of laparotomies). In the back one can well go up somewhat higher. Hence, we do all operations upon the kidneys under lumbar anesthesia.

From the foregoing you will see that the field of application is suffi-

Digitized by Google

ciently large as it is. Everything that lies below the limits stated is operated upon, almost without exception, under lumbar anesthesia at Bier's clinic.

The technique is progressing from year to year and we still hope to make many improvements, and have no doubt that in the end Bier's prognostication of a brilliant future for lumbar anesthesia will be realizd.

DR. WILLY MEYER, of New York.

Regarding this method, I would say that the same certainly has not been very extensively used on this side of the Atlantic, since the first enthusiasm following its introduction rolled by. There must be reasons for this. I believe they are threefold: First, that surgeons soon realized that spinal anesthesia also has its dangers; second, the unsettled condition that arose from the uncertainty as to the proper drug to be used; third, that general anesthesia in America has been continuously improved and its dangers reduced, partially by using safer anesthetic drugs, partially by employing specially trained narcotizers in nearly all its hospitals, thus doing away with the dangers arising from entrusting this important work to the youngest man on the staff.

Yet I believe that spinal anesthesia has its clear indication. Personally, I have used it in some 70 cases since 1900, employing cocaine (with or without paranephrine), tropacocaine, adrenalin, stovaine, and, at the special request of Dr. S. J. Meltzer, of New York, sulphate of magnesia. The physiological effect of the latter in its various applications on the human subject certainly is a wonderful discovery. But if used for spinal anesthesia it produces temporary paralysis of bladder and rectum, which is a concomitant effect, and this in certain cases, *e. g.*, hypertrophy of the prostate or stricture of the urethra, may give surgeon and patient a great deal of trouble. In view of this, I hardly think we are justified in recommending its general use for spinal anesthesia.

Novocaine, which was so warmly endorsed by Trendelenburg, of Leipzig, two years ago, and has again today been highly recommended by Professor Küster, is the only drug I have not tried. Lately, I have resumed the use of tropacocaine, which is half as poisonous as cocaine. I had abandoned it for a while on acount of two deaths. The cause was, as I later ascertained, exaggerated sterilization of the solution, which I presume split the drug. Tropacocaine is made from tropine, a fractionation product of atropine and hyoscyamine. Today, tropacocaine as well as stovaine are to be had in the market properly sterilized, ready for use, and put up in the extremely convenient ariston ampullæ, which for me constitutes a reason in favor of its use.

Digitized by Google

Personally, I believe spinal anesthesia to be distinctly indicated in very old patients, diabetics afflicted with gangrene, many cases of urinary surgery, especially old prostatics, and in all cases complicated with chronic heart or lung trouble.

I think it is our duty to recognize that we have today three different useful methods for painless operating: General anesthesia, local anesthesia, and spinal anesthesia, each one of which has its indication. If local anesthesia be impossible and the dangers of general anesthesia are greater than those of spinal anesthesia, the latter should be employed. But, generally speaking, I believe it will be a good plan, as far as surgical work in this country is concerned, to limit the use of spinal anesthesia to such cases in which it is strictly indicated, at least for the present.

DR. GEORGE E. BREWER, of New York.

I would like to ask Professor Küster if he can give us an idea of the statistics, the mortality following this procedure, gathered from his own experience and that of his colleagues in Europe. The reason I ask this is that after the first enthusiasm regarding spinal anesthesia had passed, at one of the Congresses in Paris a number of reports were made, and it was commuted from these that the mortality was something like 1 in 500. That is one of the reasons why it has not been used more extensively in this country. I have made it a rule never to employ it unless I felt that the administration of a general anesthetic was accompanied by a greater risk than 1 in 500.

DR. WILLIS G. MACDONALD, of Albany.

Before closing this discussion on lumbar anesthesia, I should like to present to the Association in a general way some personal experience and observation with relation to its employment.

I returned early in August, 1900, from a trip abroad, during which I visited a large number of clinics in Germany, Switzerland, and France. Just at this time, that of the Paris International Medical Congress, lumbar anesthesia was attracting wide attention, particularly in the Paris hospitals. I had the pleasure of observing its employment on several occasions by some of the most skilful surgeons. Purchasing the then most approved apparatus, I approached the employment of the method with some considerable enthusiasm. During the first year I employed lumbar anesthesia in not far from 60 cases out of a total of 1000 or more anesthesias. During this time a 1 or 2 per cent. solution of cocaine was employed, but never in a maximum dose. Several postoperative complications in the way of severe headaches, prolonged vomiting, and disturbed mind were observed, together with symptoms of considerable shock and not infrequently cocaine poisoning.

Digitized by Google

In the succeeding years we have used this plan of anesthesia with a progressively decreasing frequency and have employed all of the substitutes for cocaine which have been advocated, including eucaine, stovaine, and novococaine. While in the use of some of these latter agents the disagreeable manifestations associated with the employment of the remedy have been less frequent, yet, nevertheless, they have from time to time been sources of great anxiety.

I am familiar with the newer preparations and methods which have been recently presented, and saw a death occur from the administration of two-thirds of a bottle of solution identical with that which has been passed about the Association this morning.

There can be no doubt but that lumbar anesthesia is an agent of some considerable value. Time is not afforded for a general discussion of the indications for its use, which I believe to be limited, and that this form of anesthesia in no way is to be employed as a general substitute for ether or chloroform.

The question of anesthesia is largely a matter of personal equation, depending to a considerable extent upon the personnel of the clinic and the geographical surroundings. There can be no question but that in America general anesthetics are employed at this time with greater skill than in any other country of the world, except perhaps England, and that surgery is becoming awakened to the usefulness of the specially trained and skilled anesthesist now so frequently employed in our hospitals and private practice.

It appears to me that in this relation, that is, of the employment of local and lumbar anesthesia, we Americans are not alone given to all of the fads.

PROFESSOR E. KUSTER. In reply to the question of the gentleman who spoke last, I wish to state that a certain number of deaths have been observed after nearly all the drugs hitherto employed for lumbar anesthesia. The most dangerous anesthetic we have found to be cocaine, already described by me; however, all other drugs are more or less dangerous, even stovaine, which was so highly recommended at one time. The autopsy findings in the case reported by Fritz König have shown that stovaine may produce acute degeneration of the cord, resulting in death. No such experience has as yet been reported in connection with novocaine, although this latter drug has been very extensively used. Of course, this does not prove that unfavorable results may not still occur, yet there seems to be no ground for such apprehensions.

Digitized by Google

CONTINUOUS PASSIVE HYPEREMIA IN DELAYED UNION OF FRACTURES AND IN HASTENING THE CONSOLIDATION OF FRACTURES.

By JOHN B. ROBERTS, M.D.,
PHILADELPHIA.

Ten or eleven years ago I reasoned that physiological processes made it probable that delayed union in fractures could be successfully treated by engorging the fragments of bone with venous blood. This I determined to effect by applying a rubber bandage moderately firmly around the limb above the seat of fracture. I reported an instance of delayed union of the tibia and fibula so treated to the Section on General Surgery of the College of Physicians of Philadelphia in 1897[1] and mentioned the subject elsewhere about the same time.[2]

When the report was made the patient had worn the bandage for nearly three and a half months. It was used after waiting for two months for union after resection of a fracture of the tibia and fibula, which had remained ununited for five months. The bandage was applied around the lower part of the thigh, and was worn day and night just tight enough to make the foot and leg blue and swollen from venous engorgement. The skin beneath the bandage was kept in good condition by occasional bathing with alcohol and the use of a short cotton bandage beneath the rubber one.

The treatment with continuous hyperemia was supplemented by the employment of a gypsum splint, the administration of calcium salts, and walking with a cane. It seemed as though the method

[1] Suggestion for Hastening Consolidation in Delayed Union of Fractures, Annals of Surgery, January, 1898, p. 95.

[2] Manual of Modern Surgery, second edition, p. 378.

Digitized by Google

was of service, though it was not proved that such was the case. Consolidation of this fracture and of one of the other leg finally occurred.

So far as I knew, the suggestion was novel and was presented to the meeting with the hope that other surgeons would employ chronic hyperemia in the same manner in similar cases. Since that time I have continued to use the rubber bandage in delayed union or non-union of fractures, if there was no reason to believe that the difficulty was due to a mechanical impediment to union, such as interposed muscle or fascia. In the latter event, I examine the relations of the fragments through an incision. If necessary, I then resect the ends and hold them in proper coaptation with nails or staples. As a second step I use chronic hyperemia more or less continuously during the progress of the case. If the resection wound does not heal by first intention, it is probably well to obtain healing of the granulating ulcer before employing the congestion treatment. I think that the passive hyperemia caused by the bandage has a possible tendency to retard healing of the wound of the soft parts, very much as varicose veins of the legs have a tendency to keep chronic ulcers from being readily cured.

I have occasionally employed the congestion method in the treatment of recent fractures of the leg, but I do not know whether it has hastened union. The number of cases of ununited fractures which I see are few, and in both these and in recent fractures it is difficult to ascertain the exact value of the congestion treatment.

Some time after my first experience with this procedure I learned that Helferich had already proposed the identical method. His elaborate article[1] was apparently not very familar to American surgeons at that time, for there was little reference to it in text-books or journals. Helferich, by the way, says that Dumreicher used a similar method, but by a more complicated dressing a number of years before his own paper was published. My moderate advocacy of the method was likewise ineffective in securing clinical reports of cases. In recent years, however, I have noticed in

[1] Ueber künstliche Vermehrung des Knochenneubildung in Archiv für klinische Chirurgie, 1887, xxxvi, 873.

Digitized by Google

American as well as in German literature rather frequent allusions to Helferich's suggestion. More interest has been felt in the subject no doubt because of the universal attention given to Bier's writings on congestion therapy.

The books familiar to American students in which accounts of the procedure are found are Stimson's edition of Tillmans' *Surgery*,[1] Bloodgood's edition of Helferich's *Atlas and Epitome of Traumatic Fractures and Dislocations*,[2] and Da Costa's *Modern Surgery*.[3]

Helferich's technique is rather different from that which I have used. He applies a flannel bandage to the limb from the toes or fingers upward to nearly the level of the fracture. Then he adjusts the rubber bandage around the limb a short distance above the fracture. These devices cause an engorgement of venous blood only in the vicinity of the fracture. My method has been to place the rubber bandage around the limb above the fracture, and permit the whole distal portion of the leg or arm to become engorged, except in so far as the gypsum splint or other apparatus interferes with that effect of the rubber constriction above.

It is interesting to observe how slowly this method of dealing with delayed union has attracted the attention of surgeons. When I made the suggestion I thought it was novel, yet Helferich had written on the topic years previously. Nicoladoni, moreover, as Helferich states, had written on von Dumreicher's similar method as far back as 1875.[4] Von Dumreicher's reasoning was founded on the same physiological premises as were Helferich's and mine. He, however, placed four wedge-shaped compresses on the limb over the two fragments, two just above and two below the line of break, with the bases of the wedges toward the fracture. These were held in place by strips of sticking-plaster and splints of wood adjusted on top of them. The local hyperemia so obtained was used intermittently, for the wedges were removed from time to time. Curiously enough Nicoladoni, who describes the method, suggests the possibility of using the Esmarch elastic bandage for the

[1] Vol. i, p. 624. [2] Edition 1902, p. 53. [3] Edition 1907, p. 466

[4] Von Dumreicher's Methode zur Behandlung drohender pseudarthrosen, Wiener med. Wochensch., 30 Jänner, 1875, p. 80.

Digitized by Google

production of the local hyperemia. He also employed the von Dumreicher dressing to hasten the formation of bone in a cavity of the tibia left by an abscess.

That congestion of the bones and surrounding soft parts conduces to consolidation of the fracture in cases of delayed union is difficult to prove at this time with mathematical certainty. I have thought that it was a valuable method and have used it on various occasions. Da Costa quotes Buechner as stating that ten days of almost continuous application of the rubber bandage cures most cases of delayed union. He himself thinks that he has seen the procedure do good. L. M. Kommel[1] reports a case of fracture of the tibia and fibula where no union existed after eight weeks. Venous hyperemia was obtained by roller bandages applied above and below the seat of fracture for two hours daily and phosphorus was administered internally. Union occurred within a month.

Tomaschewski[2] says that the congestion method of Bier has given him brilliant results in various inflammatory affections and in defective consolidation after fracture.

I have of late employed this congestion method in recent fractures of the extremities with the hope that the ordinary period of consolidation may be shortened. My observations, however, have not been extensive or accurate enough to warrant a decided opinion as to its value. It is believed by some, I think, that fractures in which there is a good deal of blood effused in the soft tissues about the seat of osseous injury unite more quickly than similar lesions not so complicated. If this be true, passive congestion by damming blood in the injured region with a bandage would seem a rational procedure.

Wessel[3] has confidence in this way of treating fractures. At first he applies the bandage for twenty-two hours every day or so; during the second week on alternate days, and during the third week on every third day.

[1] Medical Record, December 16, 1905, lxviii, 980.

[2] Centralblatt f. Chirurgie, xxxiii, No. 27. (Abstract in Journal American Medical Association, 1906, ii, 1141.)

[3] Hospitalstidende, xlix, No. 30. (Abstract in Journal American Medical Association, December 22, 1906.)

Digitized by Google

Those especially interested in the topic will find much information in Bier's book on *Hyperämie als Heilmittel.*[1] He quotes especially the researches of Bum as showing that hyperemia from damming up the venous blood was efficient in producing callus in experimental fractures.

Although delay in union of fractures is not of very frequent occurrence, it is satisfactory to have at our service for such cases so simple a method of treatment as that under discussion. The evidence seems to show that artificial hyperemia is valuable when there is no actual mechanical hindrance to union, such as entanglement of the ends of the fragments in the muscles, interposition of fascia or necrotic bone, and malignant disease.

During the use of the elastic bandage the patient should be given the benefit of good diet and fresh air, and of exercise out-of-doors, if possible. I always administer internally in delayed union of fractures, and also in actual non-union, calcium carbonate and calcium lactophosphate. My custom is to give five or ten grains of each in powder three or four times daily. Iron, quinine, and strychnine are frequently used coincidently as tonics. I believe that constant, or almost constant, out-of-doors life is of the greatest value, as is a happy and contented state of mind. Any special diathetic deviation from health should be efficiently treated.

A true pseudarthrosis may demand resection of the ends of the fragments and mechanical fixation with nails, staples, plates, or suturing. So soon as the operation wound is closed, or nearly closed, the congestion method with the elastic bandage may be instituted. Its use immediately after operation might induce bleeding. In about a week union of the soft parts has been obtained and there is no such danger. When there remains a superficial granulating ulcer after resection, I think that I have seen delay in its cicatrization from the continuous hyperemia. This may be more true when compression of the distal parts with a gypsum splint or a bandage compels the granulating surface over the seat of fracture to be unduly engorged with venous blood.

[1] Leipzig, 1903, p. 161. Bum's articles will be found in Archiv f. klinische Chirurgie, 1902, lxvii, 652, and Centralblatt f. Chirurgie, 1901, xlvii.

Digitized by Google

Helferich thought it unwise to use the elastic constriction to produce local hyperemia, when inflammatory symptoms are present. If, however, Bier's use of this method in inflammation and other infections becomes an established procedure for their cure, it would seem that, even in fractures with infection, continuous hyperemia would not be contra-indicated. At any rate the consolidation of callus is of more importance in delayed union than the inconvenience resulting from a retardation in the healing of a coincident ulcer of the soft parts.

Care must be exercised not to make the elastic bandage too tight. It should be applied just firmly enough to induce a little bluish swelling of the limb below. It should give no pain. I usually wrap it about a half-dozen times around the limb, protecting the skin from the irritation of sweating by applying first a few turns of a cotton bandage. The patient is instructed to loosen it if it hurts. The surgeon must supervise the matter a little, lest the patient make it so loose that no hyperemia is maintained. After the latter has had the limb hanging down for a few hours the bandage may become too tight and need to be relaxed a little. After lying down for a time the patient may need to tighten it.

The bandage should be from two and one-half to three inches wide and from two to four feet long, according as it is to be used for wrist, arm, leg, or thigh. A bandage of good flannel cut bias, or a pair of elastic suspenders which are moderately elastic, will probably answer as well as a pure rubber bandage. The place of constriction may be shifted from time to time, and the underlying skin may be rubbed with alcohol occasionally. The bandage may have eyelets in it to enable the patient to fasten the terminal tape at definite places. I have used the congestion method more or less continuously. Others seem to prefer to remove the bandage occasionally. Which method is preferable is not known. It should be remembered that the bandage dams up the lymph as well as the blood, and that edema of the distal parts is not desirable. A slight bluish venous congestion is all that is desired.

Digitized by Google

DISCUSSION.

MR. ROBERT JONES, of Liverpool (by invitation).

Mr. H. O. Thomas some eight years ago read a paper entitled "The Treatment of Ununited Fractures," and the burden of his lay was passive congestion. It was my privilege in my youth to be with him when he was investigating this subject, and I think I must have seen 40 or 50 cases treated in the way Dr. Roberts suggests, some not merely delayed union, but what would now be called ununited fractures. Since Mr. Thomas died I have treated at least 70 or 80 cases.

I am quite in accord with Dr. Roberts upon the great advantage accruing from such a simple method. Mr. Thomas' habit was to tie India rubber, starting the bandage pressure at a few hours, and then prolonging it for longer. In cases of ununited fracture of the femur the patient was put in a splint with India rubber tied above and below the fracture.

Digitized by Google

RESECTION OF THE SOUND FEMUR IN GIGANTISM AND ASYMMETRY.

A PROPOSITION.

By ROBERT W. JOHNSON, M.D.,
BALTIMORE.

It is with a marked degree of hesitancy that the writer ventures to take the valuable time of this Association to present a proposition whose only virtues may be its novelty and brevity.

As our commission calls on us to relieve pain as well as cure disease, this new idea may not be *ultra vires*.

No doubt most of you have observed that a woman over six feet in height is more or less an afflicted woman. She may enjoy perfect health and yet have not the same chance for average happiness as her sister of five feet seven or even ten inches. In society she is more or less gawky, more or less handicapped by her height and shunned by the average man, who hates to be looked down on. When she dances she towers over most of her partners and is a living picture of the caricatures of Thackeray or Du Maurier or Gibson. She endeavors to meet this misfortune by stooping to conquer. Her shoulders fall and her neck cranes out. She recognizes that she is ostracised by her friends, beaten by a neck, until finally she settles down with a five-foot-three husband, if any, who has not sense enough to see how ridiculous they will appear together for the rest of their pilgrimage.

To put it mathematically, such a woman's chance for happiness is inversely in proportion to the square of the distance from her trochanters to her external condyle.

Occasionally there will be an Empress born who can carry her

Digitized by Google

magnificent height like a queen and command the admiration and devotion of men of the same ilk; but I am thinking of the gawk one sees from time to time, especially in society, who is hopeless and impossible, largely because she is afflicted with height.

Now can nothing be done for their relief? They suffer as much as bow-legged men, and yet *they* have found help in McEwen; or broken-nosed women, who look to paraffin as their savior. Nature has been holding out a helping hand for ages, but surgeons have not grasped it. Every fracture of the thigh has told us that legs may be shortened and yet not lose their function. Now I do not propose subcutaneous fracture of the femur, because that is unscientific, inaccurate, and liable to wound important structures; what I do propose is, that after one's patient has accepted the operation with a full knowledge of its possibilities, pro and con, we, under the most rigid asepsis, after careful constitutional building up, cut down on the femur at the junction of its middle and lower third, and from that region excise from two to two and a half inches from the shaft; then bring the proximal and distal ends together with chromicized catgut, silk, or silver wire, and having dressed the wound with or without catgut, drain, encase the limb from pelvis to toe in plaster of Paris or some fixed dressing, therein to remain until union has become firm. The bone may be cut square across at both ends, or obliquely, or mortise-shaped ends may be made, though I am inclined to the square ends brought thoroughly together by the sutures, as less liable to necrose and forming a firm support rather than the sliding of an oblique incision in the bone or the manipulation involved in the mortise effect. Without infection such a limb should unite in from eight to ten weeks. After some three months, during which time the patient shall have recovered from hospital confinement, the same may be repeated on the other leg with a like result. I do not advise the double operation at the same time, for in case of failure the patient's condition would be pitiable.

Again, in those cases of asymmetry, from whatever cause, when one leg is shorter than the other, when a limp or a high-soled shoe must equalize matters, as from hip-joint disease, fracture of thigh

Digitized by Google

or deformity, will not the patient be more comfortable with two even legs than with one shorter than the other? Is it not better to be an inch or two shorter than have the extra height half the time if it means a hobble all the time? If your patient feels that he will take the risk of resection of the long, sound thigh in order to bring about his comfort and usefulness, is it not fair to propose this operation, which under asepsis and good judgment should not offer much risk?

I shall not worry you with statistics or experiments. First, because I am making a new proposition and have no statistics except those of fractures of the thigh to refer, with which you are familiar, and no animals with femora like men to experiment on.

I know, too, the very narrow margin between pathos and bathos in this proposition, and thank you for your kind attention to my suggestion.

Digitized by Google

DISCUSSION.

DR. JOHN B. ROBERTS, of Philadelphia.

I have been intensely interested in this short paper, because about eighteen months ago I proposed just such an operation to a young army cadet who was liable to be discharged from the service because one leg was shorter than the other as a result of a fracture of the tibia and fibula. I suggested that I should be allowed to do this operation, which Dr. Johnson has so earnestly put before us, upon the femur of the sound limb. This femur was normally longer than that of the injured limb.

It seems to me that we have neglected this particular branch of work. I suggested that I cut this young man's long femur and thus secure symmetry for him, but thus far the operation has not been done.

Digitized by Google

A NEW METHOD OF RHINOPLASTY BY MEANS OF ONE OF THE FINGERS.

By J. M. T. FINNEY, M.D.,
BALTIMORE.

THE object of this communication is to report two cases operated upon by me for reconstruction of noses that had been lost as a result of congenital lues. The method employed in these two cases differs from any hitherto described in the particular manner in which the finger is utilized, and in that it gives rise to no external scar.

The bony support of the nose, including the septum, was entirely destroyed in both cases. The integument remained, but was retracted and distorted. In each case, instead of the usual prominence of the nose, there was a depression.

In considering the possible methods of operative relief, it was evident that the classical methods familiar to all surgeons, namely, the Tagliacotian, the Indian, and the French, or modifications of them, all of which have to do only with a restoration of the integument, were not applicable in these cases. Other methods involving a reflection of periosteal and bony flaps from the forehead or cheeks, as suggested by König, Langenbeck, Ollier, and others, have the great disadvantage of giving rise to extensive scar formation and possible necrosis. Gold and silver wire, amber, and other substances which have been from time to time recommended for use in forming a framework for the new nose, were discarded because of the fact that, as foreign bodies, they give rise to more or less irritation and sooner or later have to be removed. The injection of paraffin was clearly inapplicable on account of the absence of any bony framework and the thinness of the overlying integument.

Digitized by Google

The grafting of bone from animals, as suggested by Watson Cheyne, was not employed because of its evident liability to failure. The only remaining available source that suggested itself from which to secure the necessary bony bridge for the nose, without causing great deformity, was one of the fingers. The method employed in making use of it was as follows:

The ring finger of the left hand was selected as being the one best adapted for the purpose, and the one perhaps least missed from the hand. The nail and matrix are completely removed, the dorsum of the finger up to the distal end of the first phalanx denuded of skin. The tip of the finger throughout its entire circumference is also denuded of skin for about the distance of 1 cm., leaving the end of the distal phalanx exposed. All bleeding is stopped. The skin covering the nose, which is retracted and deformed, owing to cicatricial contraction, is then carefully freed from its attachments below without making any external scar. The skin of the nose is then stretched as carefully and thoroughly as possible by inserting the rounded end of a blunt instrument into the nasal opening in order to give as much integument as possible for the new nose. The soft parts are next freed from the nasal process of the frontal bone from within the nose by a knife or scissors passed up through the nasal opening. The inner surface of the skin forming the nasal covering should be denuded on the inner side in the middle line, in order that a raw surface may be opposed to the denuded surface of the dorsum of the finger described above, which is now inserted into the nasal opening, until the tip of the distal phalanx rests upon the nasal process of the frontal bone. The finger is held in place by sutures through the free border of the tip of the nose and the edge of the skin over the dorsum of the first phalanx. Thus, we have raw surfaces opposed where we wish to obtain our new blood supply for the finger, namely, on the tip and dorsum, while the skin covering the palmar surface of the finger, which is to form the inner lining of the nose, remains undisturbed. The hand is held in this position by adhesive strips and plaster-of-Paris bandages for two weeks, after which time the finger is disarticulated at the metacarpophalangeal joint

Digitized by Google

and left for another week, at the end of which time the tissues in the middle line over the nasal spine of the superior maxilla are split and the finger flexed at right angles at its proximal phalangeal joint.

The free end of the first phalanx is then inserted into this opening and held there by stitches through the soft parts. The

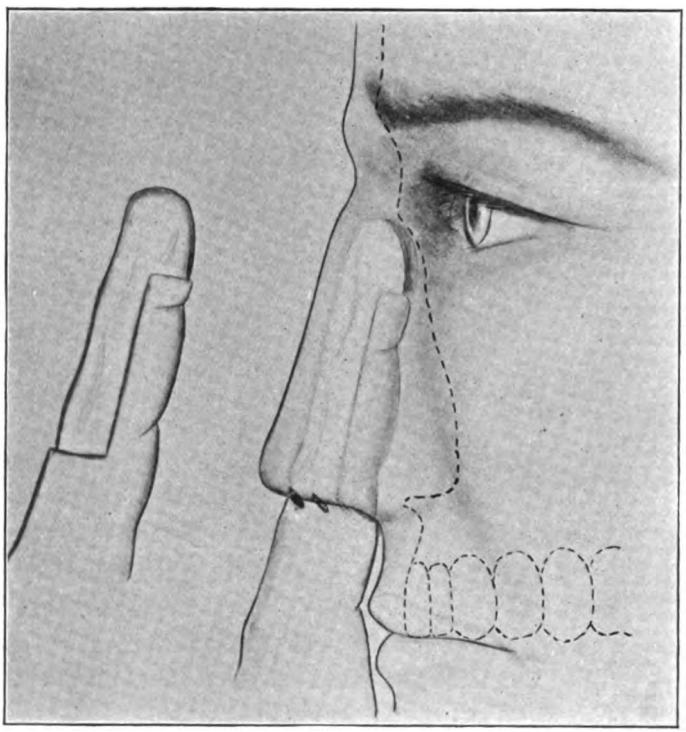

FIG. 1

first phalanx now forms the columna of the nose, while the second and third form a very satisfactory support for the dorsum. Later, smaller operations under cocaine are performed to improve the appearance of the columna, which, of course, is too large, and if needed, upon the alæ as well.

Since bone has not been apposed to bone the nose is freely

Digitized by Google

movable from side to side, which is of advantage in case of injury. The results in both cases have been very satisfactory.

My first case, a man, was operated upon in 1902; my second case, a girl of sixteen, six months ago.

In 1875, James Hardie reported a case of a young girl for whom

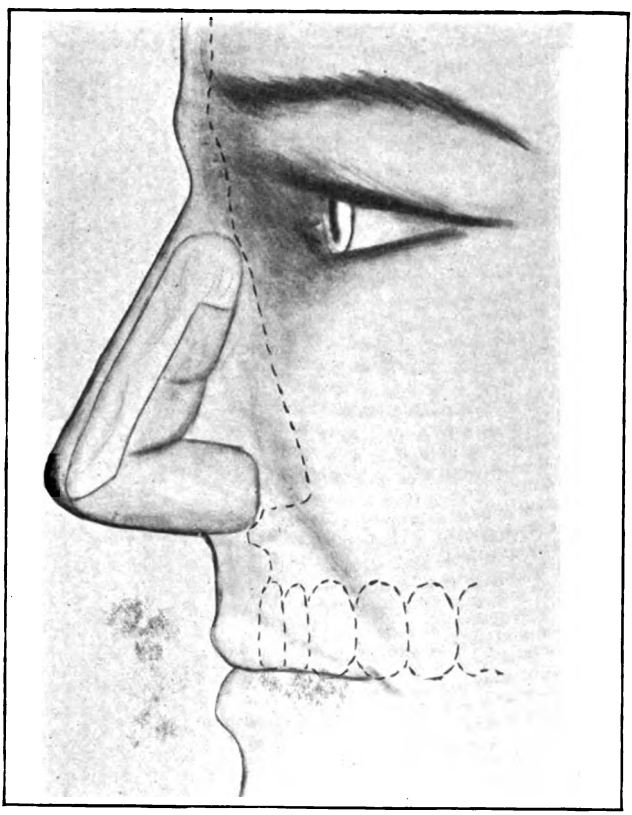

FIG. 2

he reconstructed a nose by making use of one of her fingers. This is the earliest recorded instance that I can find in which a finger was utilized for this purpose. His method in brief is as follows:

An incision is made on the palmar aspect of the distal phalanx of the left forefinger, with transverse incisions at its base. Two

Digitized by Google

FIG. 3.—Photograph of patient before operation.

FIG. 4.—Photograph taken after operation.

Digitized by Google

lateral flaps are thus reflected. The margins of the nasal cavity having been denuded, the flaps from the finger are applied to the edges and held in place by sutures, reinforced by adhesive straps. The patient was left in this position for three months, when the finger was amputated and the free end covered with the soft parts. Later the alæ were separated from the cheeks and attached to the lower end of the finger. The result in this case was not wholly satisfactory, as the healing was not per primam and the finger later receded somewhat into the nasal cavity, so much so that the author proposed to cover it with a flap from the arm or cheek.

In 1879, Dr. Thomas T. Sabine, of New York, operated upon another case somewhat similar. This was reported by his house surgeon, Dr. Vanderpool, in 1881. His operation was very similar to that employed by Hardie, namely, after a middle palmar incision, lateral flaps of the skin were dissected up from the finger and attached on either side of the nose to the skin edges, which had been freshly denuded for the purpose. The tip of the finger rested on the nasal process of the frontal bone giving support to the bridge of the nose. A through-and-through silver wire was used to hold the tissues in place. The finger was amputated after seven weeks and the nose completed.

In 1895, J. A. Bloxam, of London, operated upon a case of marked deformity. This had already been operated upon by the Indian method, with only slight success. An attempt was next made to graft a recently amputated finger, but this also failed. Lateral flaps were reflected from the finger as in the other methods. The nose was split down the centre and the finger inserted, the lateral finger flaps being stitched to the nasal flaps. The finger was subsequently amputated in two stages after four weeks. The finger did not adhere well and a subsequent operation was necessary. The result was not entirely satisfactory.

In 1897, Dr. J. P. Tunis, of Philadelphia, reported a case of a woman suffering from the loss of a large portion of the right ala and a small portion of the left, due to the application of cancer salves. The right ring finger was used in this case in a manner similar to that described in the preceding cases. The finger

Digitized by Google

was amputated at the end of three weeks and the result was satisfactory.

In 1902, Vredena, a Russian, described an operation which resembles very closely that described by Sabine. It differs from this, however, in that Vredena makes use of the entire finger, flexing the first phalangeal joint at right angles and using the proximal phalanx as the columna. This procedure also resembles our own method, except that in our method no incision is made through the skin, while in Vredena's the nose is split in the middle line.

Volkovich, also a Russian, in the same year, reported two cases operated upon by a similar method, but no detailed description of the operation is given.

BIBLIOGRAPHY.

Hardie. On a New Rhinoplastic Operation. British Medical Journal, September 25, 1875, ii, p. 393.

Sabine. Plastic Operation for Restoration of a Nose. Medical Gazette, New York, 1881, vol. viii, p. 269.

Bloxam. Restoration of a Nose. Transactions Medical Society, London, 1895, vol. xviii, p. 392.

Tunis. Rhinoplasty with a Finger. International Clinics, 1897, vol. iv, s. 6, p. 197.

Vredena. Formation of a Nose from a Finger. Russk. Vrach., St. Petersburg, 1902, i, 717.

Volkovich. Apropos of Vredena's Essay. Russk. Vrach., St. Petersburg, 1902, i, 1178.



Digitized by Google

DISCUSSION.

DR. CHARLES A. POWERS, of Denver.

Since Dr. Finney has referred to Dr. Sabine's early case it may not be amiss to say that I remember him very well. He was a familiar figure about Bellevue Hospital in the eighties; the cosmetic result was a very satisfactory one.

Digitized by Google

TREATMENT OF THE POSTERIOR CAPSULE OF THE GLAND IN THYROIDECTOMY, BASED ON 375 OPERATIONS FOR GOITRE.

By C. H. MAYO, A.M., M.D.,
ROCHESTER, MINN.

THE thyroid gland presents the most interesting of problems to the anatomist, physiologist, and surgeon. From an anatomical standpoint the gland is intimately associated with most of the important structures of the neck. Anteriorly, it is beneath the group of sternohyoid and thyroid muscles. It covers a considerable portion of the trachea in front and laterally, is closely attached to this structure, as well as to the cricoid and thyroid cartilages.

What was known of the thyroid and associated ductless glands has been greatly advanced in the last few years by numerous contributions from physiologists and scientists, yet our present knowledge concerning them is undoubtedly still limited, although the importance in maintaining the metabolism of the body has been proved beyond question.

To the surgeon, the thyroid and associated structures are of intense interest from an operative standpoint. While aseptic and antiseptic methods have removed one of the most serious of former risks of surgery, that of infection, we have in this local field so many other dangers and complications which must be constantly guarded against that the operation for goitre will always rank high in major surgery.

The thyroid gland is entirely enclosed by a fibrous capsule. Posteriorly this capsule divides into layers, one of which passes behind the esophagus, to unite with that of the opposite side, while

Digitized by Google

another layer does the same between the trachea and esophagus. The recurrent laryngeal nerve arising from the pneumogastric passes up by the side of the trachea behind the gland and next to the esophagus, to enter the cricothyroid membrane. On the right side this nerve is intimately associated with the inferior thyroid artery, passing either under or over it. On the left side it is somewhat more deeply situated and less often associated with the artery. From the various layers of fascia which enclose all of these structures and the intimate relation of the thyroid to the trachea, larynx, and esophagus we can readily see the possibility of serious pressure effects caused by a growth of the gland or a development of tumors within its substance.

The common carotid and jugular veins may become greatly distorted and displaced by growths of the gland. Nerve trunks, such as the recurrent laryngeal and vagi, occasionally become paretic from continued pressure. Paresis of one or both recurrent laryngeal nerves affecting the voice may be one of the symptoms caused by the pressure of goitre. All cases should be examined with the laryngeal mirror before the operation to determine this point, as, if the paresis is on one side only, the sound vocal cord may possibly compensate by advancing across the midline. Otherwise, in such cases the paretic condition may be temporarily so increased following operation as to lead the operator to think that he has injured a nerve.

The parathyroid bodies are four little gland-like structures usually situated behind the thyroid gland, two on each side. The upper one is most commonly at the side of the larynx, close to the esophagus and superior thyroid artery. The lower one is located close to or below the inferior thyroid artery. These glands may be displaced, increased, or decreased in number, and, while usually behind the intimate capsule of the gland, they may be enclosed with it in the capsule, in which case an ordinary extirpation would remove these glands with the thyroid.

We know that a most unfortunate complication—tetany—which occasionally follows removal of goitre, is caused by the loss of or injury to the parathyroids. These bodies can usually be

Digitized by Google

recognized, small, pinkish, or yellow fat in color, flattened ovoid bodies, ranging in size from minute structures to 1½ cm. in length.

All cases in which the thyroid glands are increased in size, whatever their pathology, are known as goitres. They may be classified in two varieties—diffuse and circumscribed. The diffuse

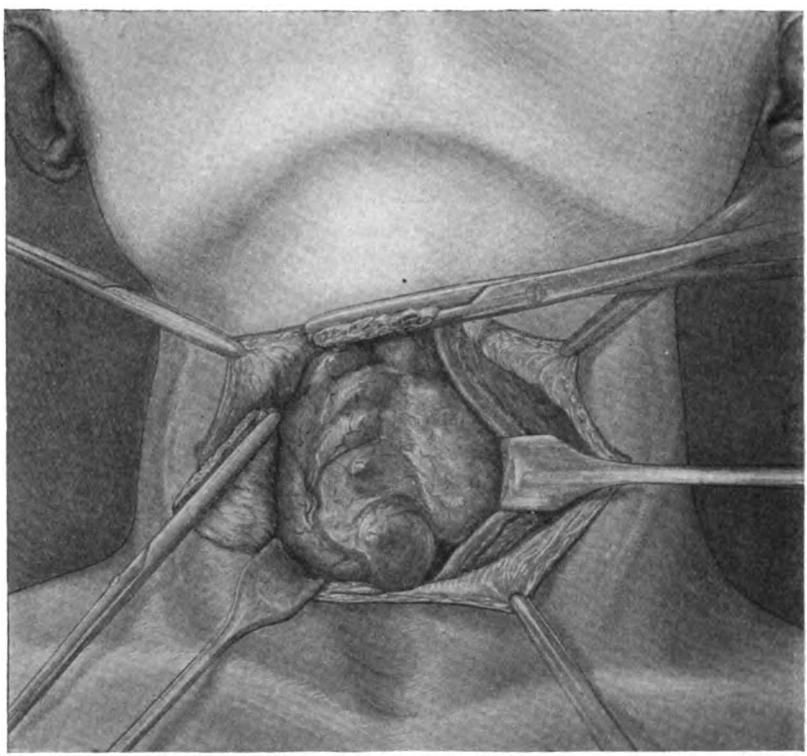

FIG. 1.—Greatest exposure of the gland. High muscle section on one side.

variety usually retain the general conformation of the normal gland with the right lobe somewhat larger. Such enlargement is often seen in hyperthyroidism, general colloid and diffuse adenomata.

The circumscribed growths may be single or multiple nodules developing in one or more lobes. Incapsulated growths are fre-

Digitized by Google

quently seen, such as fetal rests, adenomata, and cysts which have developed round tumors, having grown within the capsule of the gland proper, which may be destroyed or greatly injured by pressure atrophy.

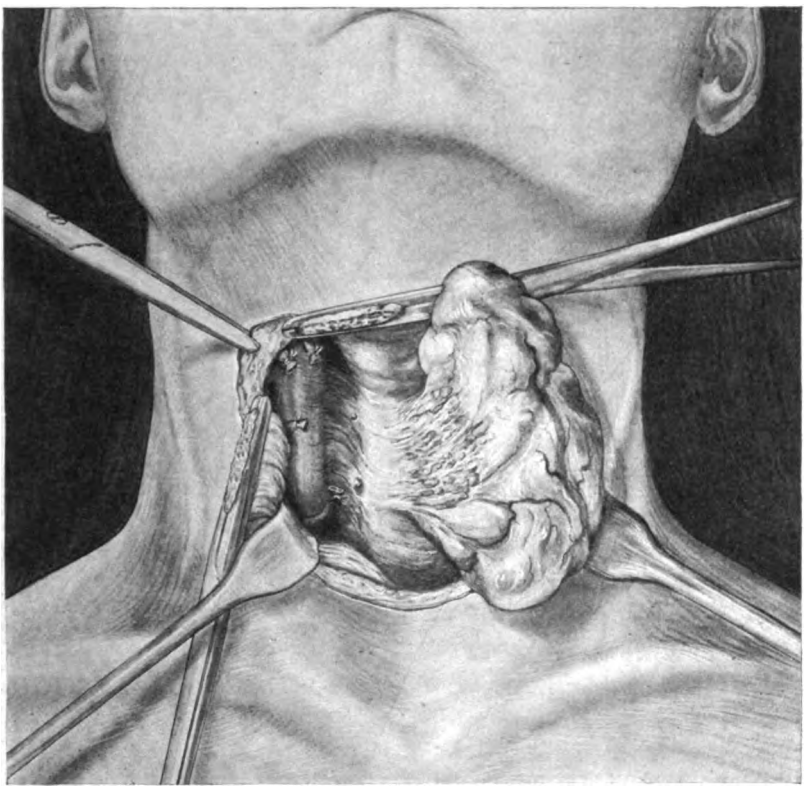

FIG. 2.—Showing position of vessels and rotation of gland over and across trachea. Posterior capsule in the field of vessels.

Local anesthesia is occasionally indicated in special respiratory difficulties complicated by myocardial lesions.

General anesthesia is preferred and is aided by previously administering $\frac{1}{4}$ gr. morphine and $\frac{1}{100}$ gr. atropine about twenty or thirty minutes before the patient is brought to the operating-room.

Digitized by Google

The patient is placed in the reverse Trendelenburg position, head up, with shoulders elevated, to expose the operative field. Ether is then administered by the open-drop method.

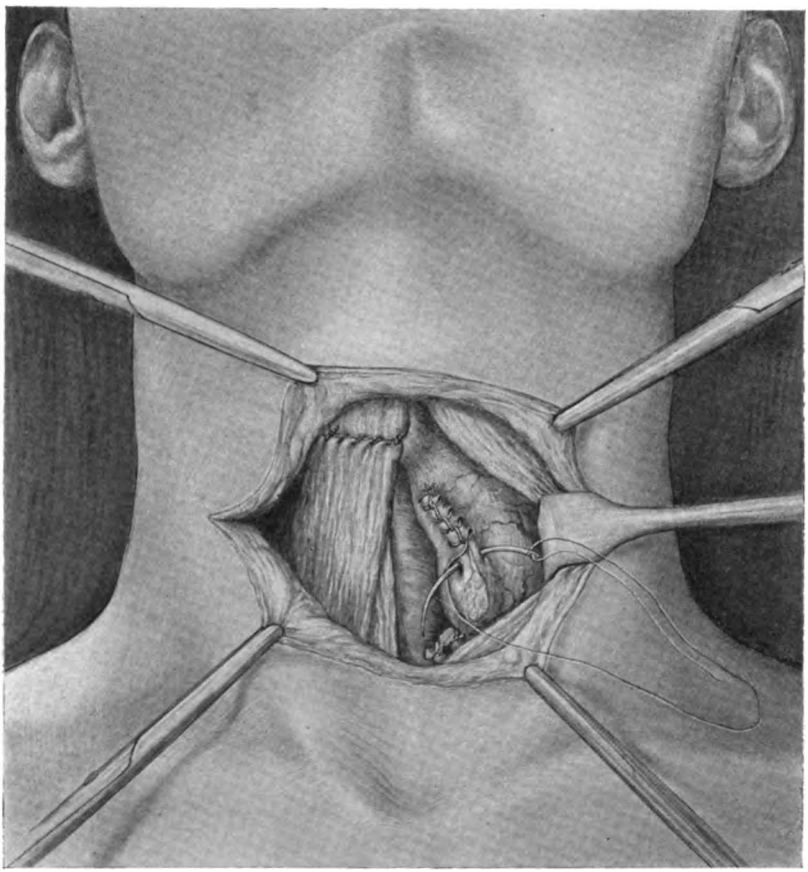

FIG. 3.—Showing muscle suture near attachment and interlocking suture of cut gland.

The Kocher transverse collar incision gives good exposure, with few disadvantages. The platysma myoides muscle is turned above and below with the skin. If muscle section of some of the sternohyoid and thyroid group is necessary they are cut between forceps placed upon them near their upper insertion.

Digitized by Google

Those cases which present encapsulated tumors or cysts are usually removed by perforation of the gland substance and enucleation of the tumor, hemorrhage being controlled by upward lifting of the capsule and gland. The cavity left is closed and obliterated by a running locking suture of catgut. While myxedema might follow by this method, should all of the gland substance be

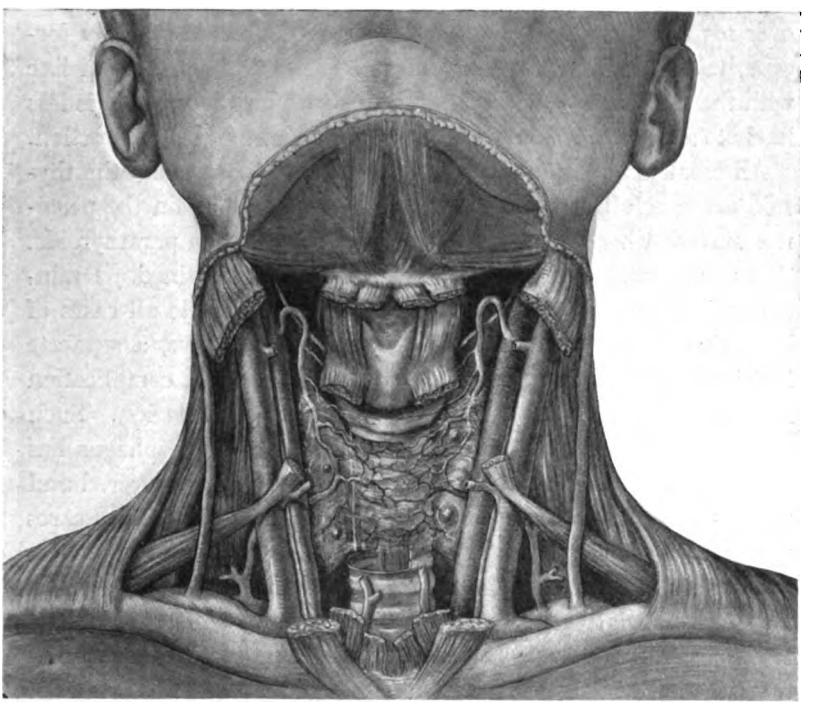

FIG. 4.—Showing blood supply and anastomosis of vessels. Parathyroids behind capsule. Trachea sectioned, showing recurrent laryngeal nerve.

removed as well as the tumor, there will be no danger of injury to those important structures situated behind the capsule, such as the parathyroids, recurrent laryngeal nerves, and esophagus.

In diffuse adenomata, Mikulicz advocated a resection of large portions of the gland, often on both sides. This method also saves the posterior capsule. We have usually favored extirpation

Digitized by Google

of one lobe in such cases and also in hyperthyroidism. The gland is elevated; all vessels entering and leaving the thyroid are double clamped and cut between the forceps, as seen in the dissection, the most important ones being ligated at the time. The whole lobe is finally elevated, with the fingers slipped behind it from the side. The capsule is opened along the side of the gland and brushed back with gauze into the wound, as the gland is lifted and rolled over toward the midline. All vessels are caught at once by forceps, taking care in applying forceps to grasp the tissues in line with the long axis of the body. In this manner the surgeon is less likely to accidentally include nerves which run in the same direction.

All small bodies of a gland-like appearance seen about the thyroid are carefully preserved; especially is this done on the posterior surface where there are a few glands other than parathyroids. The wound areas left from small growths are not drained. Drainage is instituted after removal of large tumors, while all cases of hyperthyroidism are drained from one to three days, a separate incision being always provided for that purpose. A complication in the form of tracheal injury may occur during operation. Such an accident usually causes wound infection. The esophagus has also been opened in removing goitre, but if this is discovered and the opening closed at once, it is not so serious, according to cases reported, as that of perforation occurring at a later period.

There is not much danger in this operation from air embolism, as the superficial venis are early clamped in dissection, or cut between ligatures. Should a vein be injured in the deeper dissection there is usually sufficient free blood to cover any opening. One of the great dangers, however, is secondary hemorrhage, usually from the slipping of a ligature of the superior thyroid artery. One can readily see that with a dilated artery, and a circulation much above normal in rapidity, that a most alarming hemorrhage may occur in a very brief period.

In our experience, derived from 375 operations for goitre, we have seen but 1 case develop tetany, and that only in the slightest degree. Some myxedema or other evidences of hyperthyroidism have been present in a few cases before operation; in none has

Digitized by Google

the condition been increased. In five cases we have increased the hoarseness previously manifest from the effects of pressure.

From practical experience we believe that the preservation of the posterior capsule of the thyroid, whatever the method of its accomplishment, protects against many of the dangers of thyroidectomy.

Digitized by Google

DISCUSSION.

DR. W. S. HALSTED, of Baltimore.

The cause of tetany at the hands of well-versed operators is, I believe, less often removal of the parathyroids than interference with their circulation; and I am inclined to feel that the procedure of stripping the posterior capsule so beautifully executed by Dr. C. H. Mayo, does not guarantee the safety of the parathyroid bodies. To assist in determining this point the removal of one lobe furnishes no evidence whatever. It is only from the results of operations on both lobes that we can base an opinion. But who, in order to decide the question, will take the risk of causing tetany? I fear to do an operation, even on one side, except in quite ill cases, which does not contemplate the leaving of a slice of the thyroid gland in the region of the ultimate distribution of the inferior thyroid artery. I avoid, also, ligation of the trunk of the superior thyroid artery, for fear of injuring the tiny branch to the superior parathyroid, and hence usually slice through the gland a little below the superior pole.

A parathyroid situated from 1 to 3 cm. below the inferior pole is in particular danger from the operation, for it is likely to receive its blood supply from a branch of one of the ultimate divisions of the inferior thyroid artery just before it enters the thyroid gland. Ligation of this division of the inferior thyroid artery even at the termination of its visible portion quite surely cuts off the barely visible branch to this parathyroid. There is often not room, even if the tiny parathyroid branch were discovered, for the application of the artery forceps distal to the point of origin of the parathyroid artery.

My knowledge of these facts is obtained from the beautifully injected specimens and drawings of Mr. H. M. Evans, who has taken great interest in the study of the vascular supply of the parathyroid glands, particularly with reference to the feasibility of saving the parathyroids by the operation of stripping the capsule of the thyroid gland.

One of three plans may, so far as I am able to foresee, be followed by the surgeon who desires to save the parathyroids: (1) Slice through the thyroid gland in such a manner as to leave *in situ* and with intact blood supply the area in which the parathyroids usually lie. This does not absolutely guarantee the life of the parathyroids. (2) At the preliminary operation ligate the superior and inferior thyroid arteries with the expectation that the parathyroids will receive a peripheral (extrinsic) blood supply, and a week or two later perform the subcapsular operation. (3) Search for the parathyroids before ligating any vessels of the thyroid gland; demonstrate the precise origin of each parathyroid artery; continue in such manner as not to imperil the circulation of the parathyroid. For this procedure much practice on the cadaver is essential.

Digitized by Google

THE RESULTS OF RADICAL OPERATIONS FOR THE CURE OF CANCER OF THE BREAST

By WILLIAM STEWART HALSTED, M.D.,
BALTIMORE.

It is especially true of mammary cancer that the surgeon interested in furnishing the best statistics may in perfectly honorable ways provide them. The most conscientious man may refuse to operate upon any but favorable cases, and, by performing an incomplete operation, exclude from his list of complete operations such bad ones as he finds himself operating upon. Or the pathologist on whom he relies may classify as carcinoma the tumors which on microscopic examination show dangerous spots, *i. e.*, a few epithelial cells here and there escaping into the stroma.

But you will concede that little notion of the value of an operative procedure can be gained unless some attempt be made to exclude or consider apart cancers so far advanced that, however radical the operation, only a portion of the disease can be removed.

The Results. As affecting the ultimate result, the variety of the cancer, the time elapsed since its appearance, the degree of outlying involvement, the activity of the gland (lactation, age of patient), the thoroughness of the operation, are important factors.

There will not be time in this discussion to consider in detail each of these influences. It is the particular wish of the Society, as I have understood it, to learn the results obtained by the modern, so-called complete, operation for the cure of cancer of the breast, and it affords me the greatest pleasure to express anew my obligations to Dr. Bloodgood for his efficiency and inexhaustible zeal in collating facts year after year for so many years, and to thank Mr. Schapiro for his invaluable assistance in tabulating from many points of view our results. I am exceedingly indebted, also, to the many physicians who have ardently assisted us in the search for data concerning their patients.

Digitized by Google

I ask your attention to the tables. According to the plan of operation the cases have been divided into five groups: of these, only three concern us today. In Group I are the cases in which, at the one occasion, the complete subclavian and neck operations were performed; in Group II the cases in which, at the first operation, the complete pectoral or subclavian, and at a second the supraclavicular or neck part was performed; in Group III those in which only the complete pectoral operation was done, the neck being unexplored. The small letters, *a*, *b*, *c*, *d*, indicate, approximately, degrees of axillary involvement; *a*, signifying that the base or lowest part only of the axilla was implicated; *b*, involvement of the midaxilla as well as of the base; *c*, involvement, in addition, of the highest glands of the surgical axilla; and *d*, that the subclavian vein was involved or intimately adherent to the glands.

In the tables here presented are included only the cases in which nothing less than the complete subclavicular operation was done and only those operated upon three or more years prior to the last news received of them. Excluding 65 cases in which, necessarily, an incomplete operation was performed there remain for study of the cases operated upon at the Johns Hopkins Hospital, 232. The result in 18 of these we have been unable to determine. In calculating the percentage of cures, untraced cases should be figured as dead of the disease.

In Tables II and III the ultimate results are considered in relation to the glandular involvement, and in Table II in relation also to the particular operation performed. In 64 of the 232 cases glandular involvement was not discovered; nevertheless, in 15 of these (23.4 per cent.) there was metastasis or recurrence of some sort sooner or later; in 6, metastasis three years after operation. It is interesting to note how late the metastasis occurred in these cases with undetected axillary involvement; another argument for wide operating. Forty-five of the 64 (or 70 per cent.) of the cases with undemonstrated glandular involvement are tabulated as cured, and 51 of the 64 (or 80 per cent.) were free for three years from signs of the disease. We must bear in mind, however, that surely in some, and probably in many, if not in most, of the axillæ recorded as negative there was disease.

Digitized by Google

TABLE I.

Carcinoma of the breast. Pathological varieties.

	Cases.	Cured.	Per cent
Cancer cysts	6	2 (1?)	33.3
Adenocarcinoma	32	24	75.0
Medullary carcinoma	25	12	48.0
Circumscribed scirrhus	28	13	46.4
Small infiltrating scirrhus	80	30	35.5
Large infiltrating scirrhus	39	8	20.5
Total	210	89	

SYMBOLS USED IN THE TABLES.

Complete axillary operation { Group I, Supraclavicular glands removed at 1st oper.
Group II, Supraclavicular glands removed secondarily.
Group III, Supraclavicular glands not removed.

Letters *a*, *b*, *c*, *d* indicate degree of axillary involvement:

a, Base of axilla only.
b, Base and midaxilla.
c, Base, midaxilla and apex.
d, Veins intimately adherent.

TABLE II.

Carcinoma of the breast. Cases operated upon three or more years prior to last news of them.

Ultimate result as affected by degree of axillary involvement.	Axilla only involved.				Axilla and neck involved.				Totals.
	a	*b*	*c*	Total	*b*	*c*	*d*	Total	
Cured, living 1906–7	6	..	..	6	..	..	1	1	7
Cured, living in 1905	3	3	..	6	..	..	..	..	6
Cured, dead of other causes 3 years +	..	2	2	4	1	1	..	2	6
Cured, dead of other causes 3 years —	..	..	1	1	..	..	..	..	1
Actual cures	9	5	3	17	1	1	1	3	20
Well 3 years, metastasis later	1	4	..	5	..	1	1	2	7
Cured 3 years and over	10	9	3	22	1	2	2	5	27
Dead, local recurrence	1	3	3	7	1	6	1	8	15
Dead, regionary recurrence	5	4	6	15	2	7	2	11	26
Dead, internal metastasis	5	13	5	23	1	9	5	15	38
Cases not cured	11	20	14	45	4	22	8	34	79
Cured 3-year cases	10	9	3	22	1	2	2	5	27
Postoperative deaths	..	..	..	3	..	..	..	1	4
Untraced	..	..	..	11	..	..	..	3	14
No data as to extent of axillary involvement	..	..	..	43	..	..	..	1	44
	21	29	17	124	5	24	10	44	168

Digitized by Google

TABLE III.

Carcinoma of the breast. Cases operated upon three or more years prior to last news of them.

Ultimate result as affected by axillary and neck involvement.	Glands of axilla and neck negative.				Glands of axilla positive, glands of neck negative.				Glands of axilla and neck positive.			Totals.
	I	II	III	Total.	I	II	III	Total.	I	II	Total.	
Cured, living: heard from 1906-1907	4	1	20	25	4	..	5	9	..	1	1	35
Cured, living: heard from 1905	4	2	7	13	4	..	3	7	..	..	..	20
Cured, dead of other cause more than 3 years postoperation	4	..	3	7	4	..	3	7	1	1	2	16
Cured, dead of other cause less than 3 years postoperation	..	..	..	..	1	..	3	4	..	..	..	4
Cases actually cured	12	3	30	45	13	..	14	27	1	2	3	75
Cured 3 years after operation, metastasis later	1	..	5	6	3	..	4	7	1	..	1	14
Cases cured not less than three years	13	3	35	51	16	..	18	34	2	2	4	89
Dead, local recurrence	..	..	..	..	5	..	11	16	6	4	10	26
Dead, regionary recurrence	1	..	3	4	13	1	7	21	5	5	10	35
Dead, internal metastasis	2	..	3	5	15	1	23	39	14	2	16	60
Cases that have not been cured	3	..	6	9	33	2	41	76	25	11	36	121
Cases cured 3 years and more, as above	13	3	35	51	16	..	18	34	2	2	4	89
	16	3	41	60	49	2	59	110	27	13	40	210
Postoperative mortality	..	..	..	..	2	..	1	3	1	..	1	4
Untraced	..	..	4	4	3	..	8	11	3	..	3	18
	16	3	45	64	54	2	68	124	31	13	44	232

Digitized by Google

TABLE IV.

Carcinoma of the Breast. Study of cured 5-year cases. (To January, 1907.)

	Cases.	P. O. D. and lost.	No. of cases.	Cured, living.	Cured, dead.	Metast. after 5 years.	Total.	Per cent.
Group I . . .	96	8	88	13	6	5	24	27.27
Group II . . .	16	..	16	3	1	1	5	31.25
Group III . . .	92	5	87	23	3	4	30	34.48
	204	13	191	39	10	10	59	30.89

Of 110 cases with axillary involvement and negative neck, 27 cases, or 24.5 per cent., are cured for periods ranging from sixteen to three years. Adding 11 untraced cases with axillary involvement to the 110 in which the result is definitely known, reduces the percentage of cures in this category to 22.4 per cent.

The fact that in this country, at least, a number of the leading surgeons of the generation prior to mine made the pronouncement that they had not in their lifetime cured a single case of breast cancer, notwithstanding the fact that they removed the entire breast, a liberal piece of skin, and, after a fashion, some axillary glands, is strong presumptive evidence that in almost every instance the cancer, as then recognized, had entered the lymphatic vessels. As proof of this is our observation that, even in the cases with microscopically negative axilla, and notwithstanding our extensive operation, there is death from metastasis in 23.4 per cent.

Fortunately, we no longer need the proof which our figures so unmistakably give, that the slightest delay is dangerous, and that, other things being equal, the prognosis is quite good in the early stage of breast cancer, two in three being cured; and bad, three in four succumbing, when the axillary glands are demonstrably involved. We find encouragement for our operative and laboratory labors and to increased endeavor quite as great from the relatively poor results obtained in the advanced cases as from the more favorable outcome in the cases in which no involvement of lymphatic glands was detected.

Digitized by Google

The neck operation was done in 101 cases primarily, and in 18 secondarily. In 113 of the 232 cases the supraclavicular operation was omitted. In 44 patients the glands of the neck, as well as of the axilla, were involved. Three of these, or 7 per cent., were, it seems, definitely cured. One is still living, twelve and one-half years since the operation; a second lived six years and died of diabetes; a third, three and three-quarter years without signs of return, died of acute pneumonia; and in a fourth, after three years of apparent freedom, the disease remanifested itself. We have reason to be quite certain that there was also involvement in some of the necks reported as negative.

Before accepting the statement of anyone that he has cured a case of breast cancer with neck involvement, incontrovertible proof should be demanded. I confess that even if the microscopic findings were confirmed by an able pathologist, I should stiil feel that an error might have occurred, for example, in the labelling of the specimen. The naked-eye diagnosis of the surgeon should count for nothing unless he is a sound pathologist, and the macroscopic findings are specifically detailed. Inflammation may produce appearances in lymphatic glands quite indistinguishable macroscopically from carcinoma, whether medullary or scirrhous. If the deposit is described as sharply outlined against the more normal portions of the gland, particularly if cortical, the observation deserves consideration. We should demand as further proof of cure, in these positive neck cases, that the patient live at least five years after the operation, or negative autopsy findings, a year, or perhaps even two years thereafter. With these stipulations fulfilled, I should still be skeptical as to the cure. Cancer was diagnosticated, both macroscopically and microscopically, in the three cases of cure claimed by us. But, even without the proof which we offer, it is, I think, incumbent upon the surgeon to perform in many cases the supraclavicular operation. He should surely perform it, barring, of course, special contra-indications (1) in all cases with palpable, operable neck involvement; (2) when the apex of the surgical axilla is involved. When midaxillary involvement is demonstrable at the operation apical implication is almost certain, and hence (3) in these cases also the neck should be typically cleaned of

Digitized by Google

its lymphatics, as high, at the very least, as the bifurcation of the carotid.

We find ourselves for the past two years again performing the neck operation in most cases. We omit it in hopeless cases, in most "duct cancers," and in some carcinomata of emphatically adenomatous type in which the axilla at operation is not macroscopically involved.

To determine the relation of supraclavicular to subclavicular involvement detailed observations at the operating table with special reference to this point must be made; and almost endless laboratory work is necessary. To be able to assert with any degree of positiveness that the axilla and neck are negative involves infinite toil. The findings at operation should be recorded on charts designed especially for this purpose; and a laboratory enthusiast of a rare type is indispensable.

For the greater convenience of the reader the following summary is given. Of the 232 cases considered, 18 remain untraced. Of the 210 traced cases, we accept as *cured:*

35 cases reported living in 1906–7	16.6 per cent. of 210
20 cases reported living in 1905	9.5 per cent. of 210
16 cases known to have died of causes other than carcinoma of the breast three or more years after the operation	7.9 per cent of 210
4 cases dead of other disease less than three years after operation, in which the cure was demonstrated by autopsy.	1 9 per cent. of 210
Total cured } 75 cases = 32.3 per cent. of 232;	and 35.6 per cent. of 210

In 14 cases metastasis appeared after three years, in one instance manifesting itself as late as eight years, and in two instances more than six years after the operation. Thus, 89 cases (42.3 per cent. of 210, and 38.3 per cent. of 232) were apparently cured for three or more years.

In the 210 traced cases the condition of the axilla and neck, as regards glandular involvement, was as follows:

Digitized by Google

	Cured.	Per cent.	Cured 3 years.	Per cent.
Axilla and neck negative . . . . . 60 cases	45	= 75	51	= 85
Axilla positive, neck negative . . . 110 cases	27	= 24.5	34	= 31
Axilla and neck positive . . . . . 40 cases	3	= 7.5	4	= 10
Total 210				

THE MORTALITY. Four of the 232 patients died in the hospital, a mortality of 1.7 per cent. The group apportionment of the deaths is as follows:

Group I . . . in 101 cases, 3 deaths = 3.00 per cent.
Group II . . . in 18 cases, 0 deaths = 0.00 per cent. } 2.5 per cent.
Group III . . . in 113 cases, 1 death = 0.88 per cent.

Thus, it would seem, without particulars, that the neck operations were responsible for the greater mortality, Groups I and II yielding a 2½ per cent. death rate, and Group III, in which the neck operation was omitted, a mortality of hardly 1 per cent. But two of the deaths in the neck cases were clearly due to an avoidable error, quite independent of the operation. These two patients, operated upon just twenty-four hours apart, were convalescing normally until the first dressing, which was made in both cases the same day and hour, respectively, eight and nine days after the operation. Within a few hours of the dressing each patient had a chill, with high temperature. The skin grafts and wound, which in each had a perfectly normal appearance at the time of the dressing, rapidly acquired the features so characteristic of general infection. Excluding these two cases, the mortality in the patients with neck operation becomes 0.99 per cent., only a shade more than in the cases with axillary operations alone, in which it is 0.88 per cent.

RECURRENCE AND METASTASIS. We know little of what is going on under the skin along the fascial planes even when our attention is drawn to the disease by the appearance, here and there, of cutaneous or subcutaneous nodules at long distance from the pri-

Digitized by Google

mary tumor. I recall distinctly one case, and less distinctly one or two other cases, of intestinal and peritoneal cancer in which general metastasis was believed, erroneously, I think, to have occurred by way of the bloodvessels, although the only evidence of metastasis were numerous subcutaneous and fewer cutaneous nodules, situated chiefly over the abdomen and confined altogether to the trunk, or to the trunk and its immediate vicinity. Although it undoubtedly occurs, I am not sure that I have observed, from breast cancer, metastasis which seemed definitely to have been conveyed by way of the bloodvessels; and my views as to the dissemination of carcinoma of the breast accord so fully with Handley's[1] that I may, in justice to him, who has formulated and expressed them so well, quote now and again from his admirable chapters. "In showing that cancer cells in blood excite thrombosis, and that the thrombus as it organizes usually destroys or renders them harmless, Goldmann and Schmidt seem to have established a fact of primary importance, and one which is strongly opposed to the embolic theory as applied to carcinoma." We believe, with Handley, that cancer of the breast, in spreading centrifugally, preserves in the main continuity with the original growth, and before involving the viscera may become widely diffused along surface planes.

Statistics obtained from many sources indicate that bone metastasis in cases of breast cancer occur, as phrased by Handley, very rarely in areas not actually invaded by the subcutaneous nodules. As is well known, the sternum, ribs, spinal column, femur, and humerus, and, perhaps, also the skull, are the bones most frequently attacked in cases of breast cancer. Distal to the elbow and knee the bones escape, except in rare instances, cancerous invasion. We have in our cases no record of bone involvement below these joints. "The liability of a bone to cancerous metastasis increases with its proximity to the site of the primary growth." The illustration on the next page graphically represents the coincidence of the areas liable, respectively, to bone metastases and to subcutaneous nodules.

In that metastases occur both in general and in the special case

[1] Handley. Cancer of the Breast and its Operative Treatment. London, 1907 (W. Sampson).

Digitized by Google

only in bones which lie in the area invaded by subcutaneous nodules there is signified a relationship between the two, "between the bone deposits and the subcutaneous nodules." The dissemination probably takes place by way of the lymphatics—not by the bloodvessels—and the disease holds together without important inter-

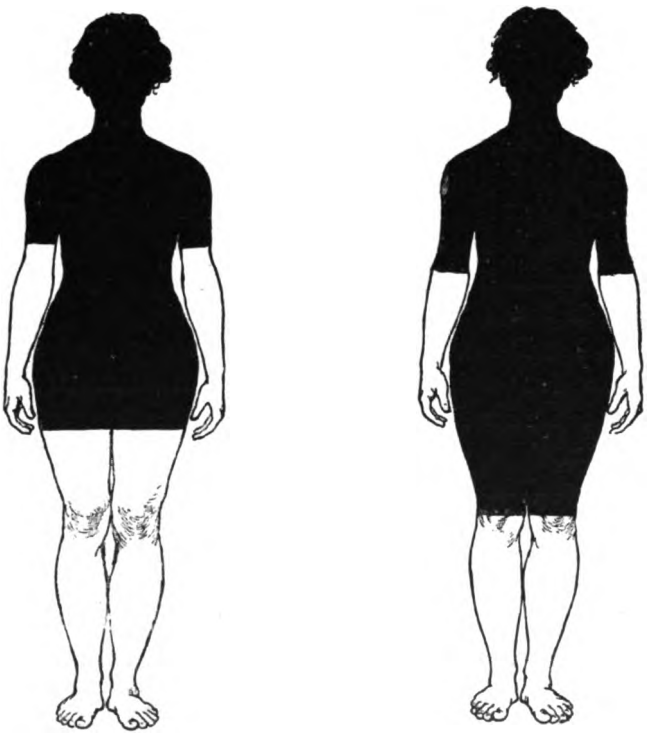

A *B*

Diagrams showing the maximal distribution areas of subcutaneous nodules and of metastases in bone in cases of mammary carcinoma. The black area in *A* is the area liable to subcutaneous nodules, that in *B* is the area within which bone metastases occur. (After Handley.)

ruptions. It permeates to the bone rather than metastasizes to it, and, by way of the lymphatics, along fascial planes. Much evidence has been adduced by others, and most convincingly by Handley, to indicate that the centrifugal spread of breast cancer takes place primarily in the plane of the deep fascia. If the bones are invaded

Digitized by Google

by way of the lymphatic plexus of the deep fascia the first attack should fall on the spot nearest the deep fascial lymphatics—nearest the surface; in the case of the femur, at the great trochanter; of the humerus, at or below the insertion of the deltoid; and such seems actually to be the case.[1]

There is then a definite, more or less interrupted or quite uninterrupted, connection between the original focus and all the outlying deposits of cancer, "the centrifugal spread annexing by continuity a very large area in some cases." Thus the liver may be invaded by way of the deep fascia, the linea alba, and round ligament,[2] "the brain by the lymphatics accompanying the middle meningeal artery."

CANCER CYSTS. At some other time we may consider in detail the cancer cysts, but at present can only speak of the difficulty in recognizing them and the hopelessness of the prognosis if their character is not suspected by the surgeon at the operating table. "By the surgeon," I say, for unless the operator espies the hardly discernible changes in the delicate wall of the cyst it will not occur to him that it is worth while to submit a piece for immediate examination by the pathologist. If he is able to recognize the barely perceptible thickening, the slight lack of lustre, the faintest possible difference in color and in texture, he will probably make the diagnosis without microscopic assistance. Blood-stained fluid should arouse one's suspicions, but there may be no staining of the cyst-content. Every portion of the wall should be scrutinized, particularly the base of the not infrequent papilloma. The prognosis is quite hopeless if the diagnosis is not made at the operating table. I failed to make it in the first case and possibly in the second, although I have the impression that my suspicions were aroused in the second case, operated upon many years ago. In all the clinically undiagnosticated cases the nature of the cyst was soon discovered by the microscope, and in all, more or less promptly, a second operation performed; but, alas, performed in vain. The

[1] Handley, loc. cit.

[2] Handley furnishes convincing proof that the liver may be invaded by way of the linea alba and round ligament.

Digitized by Google

cases saved are only those in which, at the operating table, the correct diagnosis was made. Further proof of the necessity of making the correct diagnosis at the time of operating is not needed. The prognosis in these cases of cancer cyst, the earliest recognizable cancers, perhaps, is excellent if the nature of the disease is perceived at the table; hopeless, so far as our statistics are concerned, if it is not. Do we require more definite proof than this, that the first operation is responsible for the inefficacy of the second? The precise means by which the first renders the speedily following second operation futile, is not perhaps altogether clear. The partial operation (the first) certainly disseminates the cancer, which the complete operation (the second) in the primarily diagnosticated cases of cancer cyst has not, in our experience, done. Furthermore, dissemination takes place probably by routes not already travelled by the cancer cells and not commonly travelled by them in the early unoperated cases. Probably by these unusual routes the disease soon reaches parts outside the domain of the operation and so escapes eradication.

THE DIAGNOSIS. It is not expected of me in this report to touch upon the diagnosis of breast cancer; furthermore, it is considered a trite subject—one to which little can be contributed. But for me, interest in the diagnosis of difficult cases increases, and with it the conviction that really something remains to be said and done. It well repays the experienced surgeon to spend perhaps an hour in the examination of certain breasts. The diagnosis has usually and unfortunately been exceedingly simple. But women are now presenting themselves more promptly for examination, realizing that a cure of breast cancer is not only possible, but, if operated upon early, quite probable. Hence, the surgeon is seeing smaller and still smaller tumors—cancers which give not one of the cardinal signs. About as difficult a case as any, excepting, of course, the adenoma in a transitional stage, is a tiny retromammary adenocarcinoma, or a colloid carcinoma, in a breast covered with one or more inches of fat. If in such a case there should be no shortening whatever of the trabeculæ, the diagnosis could hardly be made. The fat, on pressure being elastic, and the tumor so deep, the dif-

Digitized by Google

ferential diagnosis from cyst might not be possible. But, given even very slight shortening of the trabeculæ from tumor to skin, this fact might be determinable by making both breasts take the widest possible excursions on the chest wall under the skin. The faintest conceivable trace of a difference on the two sides, in a minor pectoral crease, for example, may suffice for the diagnosis. Raising the skin over the tumor with the fingers, to ascertain the relative length of the trabeculæ, is too crude a method, and in no case serviceable unless the tiny growth is directly under or close to the nipple; for, if the test applied in this way gives a positive result, there is so much shortening of the trabeculæ that the slightest displacement of the breast would reveal it. I have occasionally noticed that of my assistants perhaps one or two will see a trace of asymmetry in the skin tug on extreme displacement which the others are wholly unable to make out; and I have more than once in just such case of difference of opinion performed the complete operation for very small, deep-seated cancers, without exploratory incision. Frequently there is no sign, but this almost imperceptible suggestion of pull, which, when the faintest possible, is, of course, elicited by dislocation in one direction only. This sign, however slight, is all that is needed for the diagnosis. Practice in the examination of such cases, doing one's utmost to get such evidence, is highly rewarding. Any breast, if displaced far enough, will, of course, tug, in a way, on the skin; it is only under the most accurate control with the other breast that its significance in difficult cases may be estimated. It will seem to some that I am wasting many words to tell what every surgeon knows; but to me, at least, the extreme possibilities of this test were not fully realized a decade, perhaps, ago, and each year, I believe, it develops a little in refinement. The ability to determine elasticity, the elasticity of a small cyst, as hard, almost, as bone, comes to some earlier than to others; but to me, if it has come at all, it came only with long practice. In the breast a difficulty arises from the fact that a tense cyst makes itself felt such considerable distance in the surrounding mammary tissue, particularly if the breast is very fibrous. A nodule seemingly as large as a pea to palpation may be caused by a

Digitized by Google

cyst no larger than a small pin-head, and a cyst almost microscopic may, by the pressure which it exerts in the dense fibrous tissue of the breast, occasion a definitely palpable, quite circumscribed hardness. It should impress the uninitiated to witness the ability of the demonstrator to diagnosticate with the fingers through considerable fibrous tissue these hardly visible cysts yielding, on puncture, the tiniest fraction of a drop. The general nodular feel of a fibrous mamma in situ or on a tray depends largely upon small to tiny foci of parenchyma, which are most readily recognized by the finger when a little fluid (the minutest particle suffices) is retained under tension.

The firm, circumscribed pressure exercised in the effort to determine the elasticity of a tumor occasionally ruptures, I believe, the capsule of a fat lobule. In three instances, while making this test, a peculiar sensation has been communicated to the fingers, which I attributed, in the first instance, and with considerable apprehension, to rupture of a cystic portion of a colloid cancer which I believed to be under examination. The cause of this perfectly unmistakable sensation, which must, one feels, be accompanied by a non-audible sound (onomatopoetically, geräusch), we have been unable definitely to determine. It is due to the crushing or rupture of something, certainly not of a cyst, and I have noted this sign only in fat people.

The size of the breast, relative to that of the other side, should, of course, be determined; but it is important to note most carefully the relative amount of uninvolved mammary gland remaining—relative to the amount in the other breast and to the size of the new-growth.

Given a carcinoma, say one-half or one-quarter as large as the palm of the hand, if this tumor has grown not at all or little at the expense of the breast—and this is ascertained by making the comparison just advised—the prognosis is relatively good; for the tumor in such case is quite surely of a definitely adenomatous type, and not of the scirrhous variety.

There can be little doubt, in my opinion, that a scirrhous cancer represents only a part of what has existed. The struggle against

Digitized by Google

the cancer cells, resulting in fibrous-tissue production, is quite surely not always futile, and when the minute foci of cancer epithelium have been destroyed, the new fibrous tissue may, in part, be absorbed also. Thus the scirrhous disease may be active and metastasis take place a long time before the visible or palpable tumor is developed. It would undoubtedly be possible for the expert to discover of the scirrhous growth earlier stages than he encounters, but unfortunately the tumor must first be recognized by the patient, and a scirrhous cancer large enough to attract her attention has quite surely already gone afield. Our problem, therefore, is to discover these tumors before the afflicted one can do so. Shall we let women know that a dangerous process may be going on which they cannot detect, and keep them constantly in a state of apprehension, or shall we encourage them to seek "expert" advice, which may be insufficiently expert, and expose them to the annoyance of repeated and useless examinations, each of which for only a brief period, if at all, would bring a measure of reassurance?

THE OPERATION. Though the area of disease extend from cranium to knee, breast cancer in the broad sense is a local affection, and there comes to the surgeon an encouragement to greater endeavor with the cognition that the metastases to bone, to pleura, to liver are probably parts of the whole, and that the involvements are almost invariably by process of lymphatic permeation, and not embolic by way of the blood. If extension, the most rapid, takes place beneath the skin along the fascial planes, we must remove not only a very large amount of skin and a much larger area of subcutaneous fat and fascia, but also strip the sheaths from the upper part of the rectus, the serratus magnus, the subscapularis, and, at times, from parts of the latissimus dorsi and the teres major. Both pectoral muscles are, of course, removed.

A part of the chest wall should, I believe, be excised in certain cases, the surgeon bearing in mind always that he is dealing with lymphatic, and not blood, metastases, and that the slightest inattention to detail, or attempts to hasten convalescence by such plas-

Digitized by Google

tic operations as are feasible only when a restricted amount of skin is removed, may sacrifice his patient to the disease.

It must be our endeavor to trace more definitely the routes travelled in the metastases to bone, particularly to the humerus, for it is even possible in case of involvement of this bone that amputation of the shoulder-joint, plus a proper removal of the soft parts, might eradicate the disease. So, too, it is conceivable that ultimately, when our knowledge of the lymphatics traversed in cases of femur involvement becomes sufficiently exact, amputation at the hip-joint may seem indicated. The operation might with advantage be considered in greater detail, and I hope in the near future to have the opportunity to do so.

As to the closure of the wound, I should not care to say, "Beware of the man with the plastic operation." The surgeon should familiarize himself with the principle of the one or two particular plastic operations which make the best use in the simplest manner of any redundant or easily glideable skin, as of the axillary flap, that he may be prepared in any case to utilize in combination with skin grafting such features as seem applicable. But to attempt to close the breast wound more or less regularly by any plastic method is hazardous, and, in my opinion, to be vigorously discountenanced. The oval flap, whatever the direction of its long axis, removes, so far as the cure of the disease is concerned, a circle of skin whose diameter is not greater than the short axis of the oval. I still believe in the removal of a very large circle of skin, and indorse the remark of my ex-house surgeon, Dr. Follis, that the operator whose duty it is to close the wound should not be intrusted with the planning of the skin incision. Skin-grafting, well done, consumes few minutes; as a method, it adds little, if at all, to the period of convalescence, except so far as very early arm movements are concerned, and nothing to the mortality. I grant that to cut the grafts well, much practice is necessary, and the skill acquired by some is so great that I intrust this part of the procedure to the dextrous house surgeon. Thiersch grafts from the thigh are commonly cut as large as a good-sized hand. One such graft may be sufficient to cover the defect; more than two large grafts

Digitized by Google

are not often required. The silver-foil dressing for the grafts, used at the Johns Hopkins Hospital for so many years, seems quite ideal.

Occasionally, and happily with increasing frequency, an incision for diagnostic purposes has to be made. Great care should be exercised to make these exploratory cuts no deeper than is absolutely essential. Very rarely is it necessary to carry the knife *into* a cancer, for on exposure of the subcutaneous fat the tell-tale drawing of the fibrous tissue is revealed; sometimes the fat must be cut into for a little distance. If the growth is not malignant the incision should usually pass through it.

CAUSTICS. I am indubitably convinced that the local and regionary recurrences after incomplete operations, which come, as a rule, with amazing rapidity when the knife has been used, are, to say the least, relatively late in making their appearance when chemical or actual cauterization has been employed. I have several times had occasion to operate upon cancers which had been vigorously and repeatedly treated with caustics, and to note the comparatively admirable condition, the freedom from cancer permeation, of the surrounding tissues and of the axilla; whereas, after incomplete operations with the knife the local manifestations of recurrence were almost invariably deplorable and the prognosis, of course, invariably hopeless.

It was my practice at one time in making the exploration in doubtful cases to excise a portion of the breast tumor with the Paquelin cautery to prevent the wound inoculation which I feared might take place if the knife were used. The excision of a specimen for macroscopic or microscopic examination is never resorted to except just before operation. If the actual cautery for any reason is not used, the wound is immediately cauterized with carbolic acid. All incomplete operations for cancer should, when feasible, be made with the Paquelin or actual cautery.[1] The

[1] I was greatly pleased to note, during a recent visit to Rochester, Minnesota, that Drs. William and Charles Mayo make extensive use of the actual cautery in operations upon cancers incurable by the knife, and to have them indorse the view, so long maintained by me, that there is relative immunity from local metastasis with the employment of the cautery.

Digitized by Google

Paquelin is ideal for the removal of cutaneous nevi, particularly of the melanotic variety. I doubt if any melanotic tumor of the skin should be removed with the knife.

Cancerous Axillary Glands, with Non-demonstrable Cancer of the Mamma.

I have twice seen extensive carcinomatous involvement of the axilla due to mammary cancer, which latter in neither instance became palpable or demonstrable for a considerable period after the axillary glands had attained conspicuous dimensions. In each case the "axillary tumors" had been removed, in one of them a year before, and in the other perhaps two years prior to my first examination, which, though made in the most careful manner, failed to find the slightest evidence of cancer of either breast. In the course of a few months thereafter the mammary disease manifested itself in both patients.

A third patient was operated upon, for enlarged glands of the axilla, about two and one-half years before she consulted me concerning the local axillary recurrence of the disease, and more especially to be relieved of severe neuralgic pains in the arms and legs. In this woman I found a large mass of axillary glands, which proved to be cancerous; but nothing in the breast except a quite definite parchment-like induration at the base of the nipple, which was retracted not at all, or merely to a barely appreciable degree. With performance of the complete breast operation the pains in the extremities, which distressed her greatly, vanished.

Disseminated Pains, which Would Seem to be Caused Occasionally by the Toxins Generated in the Course of the Growth of Cancer. Distressing pains in the knees, the legs, the back, the arms, so severe and so located as to suggest cancerous involvement of the vertebræ, have in two cases operated upon by me at the Johns Hopkins Hospital disappeared on removal of the growth, which in one instance was large, ulcerous and foul-smelling; in the other (the case cited at the end of the preceding paragraph) consisted merely of a large mass of glands in the axilla.

Digitized by Google

Reactionary Edema in Mammary Cancer. Quite recently I was privileged to see a condition of board-like edema, limited, in a general way, to the pectoral region of one side. There was no definitely appreciable abnormality of the mamma other than the edema, in the area of which it was included; otherwise, not until perhaps six months after the first manifestation of this edema was there the least evidence of neoplastic disease of the breast. Then, as, in my experience, is usually the case in the presence of extensive and great edema of reaction, the cancer made very rapid strides.

Digitized by Google

THE RESULTS OF OPERATIONS FOR CANCER OF THE BREAST AT THE MASSACHUSETTS GENERAL HOSPITAL FROM 1894 TO 1904.

By ROBERT B. GREENOUGH, M.D.,
CHANNING C. SIMMONS, M.D.,
AND
J. DELLINGER BARNEY, M.D.,
BOSTON.

At the request of Dr. R. G. Le Conte, the Secretary of the American Surgical Association, and of Dr. J. Collins Warren, and with the assent and approval of the surgeons of the hospital, the writers have attempted to trace and to report the cases of cancer of the breast which entered the Massachusetts General Hospital during the ten-year period from January 1, 1894, to January 1, 1904. The latter date was selected in order that a period of at least three years should have elapsed after operation in every case. It is with great pleasure that the writers acknowledge their appreciation of the cordial coöperation they have received from all of the members of the Hospital Staff, and especially from the administrative officers of the hospital, who have contributed much to the success of this rather arduous undertaking.

The Massachusetts General Hospital may be taken as a type of the larger American general hospitals where operations are performed by a considerable number of surgeons, each one being on service for only a small portion of the year; in contrast to the special or university hospitals, where one surgeon is continuously on duty for many years, and specialization in the different branches of surgery is a possibility. It is to be supposed that the statistics of the general hospitals can never equal those of the special hospital; but it is fair to say that they do represent more accurately the

Digitized by Google

average results of surgery in a given community, and thus give, perhaps, a more correct indication, from the patient's point of view, of the average expectation of cure. The 416 operations of this series were performed by twenty different surgeons,[1] and the greatest number performed by any one surgeon was 51.

The methods employed in tracing cases were those which have proved efficient in other investigations. The hospital record of each case was first abstracted on a card of convenient size. (See figure.) These cards were numbered consecutively, and re-entries, out-patient records, and letters from patients were attached. A letter was then sent to each patient or to her friends. When no reply was received from patients or friends, letters were sent to attending physicians, postmasters, police departments, city and town clerks, and Boards of Health. Many of the fatal cases were found in the excellent records maintained by the Massachusetts State Board of Health, and a few from the Bureaus of Vital Statistics of other New England States. Finally, a certain number of cases were traced by personal interview with neighbors, relatives, and friends; by reference to city directories and by the use of registered letters, 378 of the total 416 (or over 90 per cent. of the cases) were followed to a definite end-result, and the writers feel compelled to acknowledge that without the courtesy and coöperation of many persons whose interests were in no way involved, this report could not have been prepared. In making a study of hospital records, it is essential that a uniform interpretation be placed upon the data obtained.

The record of the operation performed in each case was studied and the operation was classed in one of the four following groups:

1. *Complete Operations.* In which the tumor, the breast, the sternal portion of the pectoralis major muscle, and the entire axillary contents were removed, and the pectoralis minor muscle either divided or removed. Exploration *above* the clavicle was

[1] Drs. C. B. Porter, J. C. Warren, John Homans, H. H. A. Beach, A. T. Cabot, J. W. Elliot, M. H. Richardson, F. B. Harrington, S. J. Mixter, W. M. Conant, C. L. Scudder, J. G. Mumford, W. A. Brooks, Jr., C. A. Porter, F. G. Balch, G. W. W. Brewster, Farrar Cobb, E. A Codman, R. B. Greenough, and D. F. Jones.

Digitized by Google

not considered essential. This interpretation of the essentials of a "complete" or "completed" operation was accepted as the opinion of a majority of the visiting surgeons of the hospital.

2. *Semicomplete Operations.* Those in which the whole of the complete operation was done, with the exception of the division or removal of the pectoralis minor.

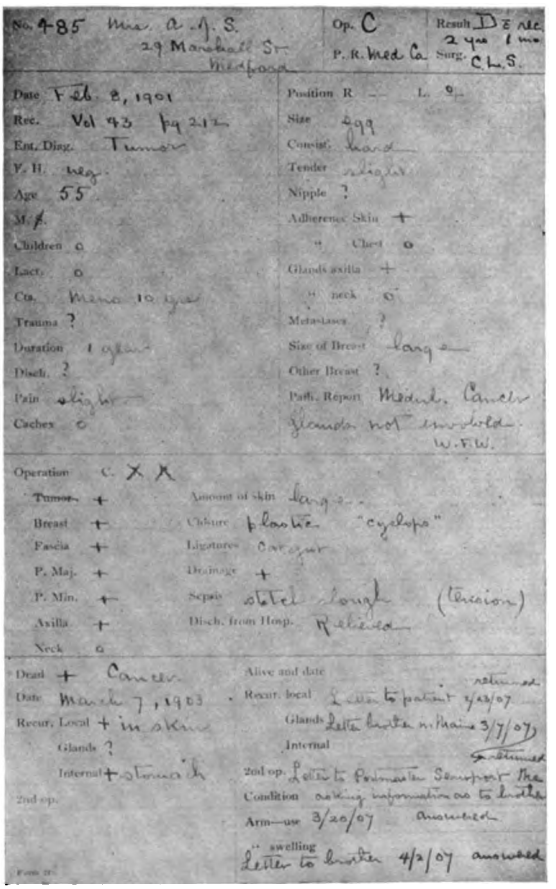
No. 485 Mrs. A. J. S. 29 Marshall St. Medford
Op. C
P. R. Med Ca
Result D E rec. 2 yrs 1 mo.
Surg. C. L. S.

Date Feb. 8, 1901
Rec. Vol 43 pg 212
Ent. Diag. Tumor
F. H. neg.
Age 55
M. S.
Children 0
Lact. 0
Cts. Meno 10 yrs
Trauma ?
Duration 1 year
Disch. ?
Pain slight
Cachex 0

Position R — L. 0
Size 299
Consist. hard
Tender slight
Nipple ?
Adherence Skin +
" Chest 0
Glands axilla +
" neck 0
Metastases ?
Size of Breast large
Other Breast ?
Path. Report Medul. Cancer glands not involved. W.F.W.

Operation C. X X
Tumor +
Breast +
Fascia +
P. Maj. +
P. Min. +
Axilla +
Neck 0

Amount of skin large
Closure plastic "cyclops"
Ligatures Catgut
Drainage +
Sepsis stitch slough (tension)
Disch. from Hosp. Relieved

Dead + Cancer
Date March 7, 1903
Recur. Local + in skin
Glands ?
Internal + stomach
2nd op.

Alive and date
Recur. local Letter to patient 2/23/07 returned
Glands Letter brother in Maine 3/7/07
Internal
2nd op. Letter to Postmaster Seaport Me returned
Condition asking information as to brother
Arm—use 3/20/07 answered
" swelling Letter to brother 4/2/07 answered

3. *Incomplete Operations.* Those in which an attempt at radical cure of the disease was made, but the pectoralis major, a portion of the breast or of the axillary contents, or other parts essential to the complete operation were left behind.

Digitized by Google

4. *Palliative Operations.* Those in which no hope of radical removal of the whole disease was entertained, and cancerous tissue was supposed to remain in the wound at the end of the operation.

It has been the custom of the hospital since 1885 for all material obtained at operations to be examined by a clinical pathologist, Dr. W. F. Whitney. The pathologist's report is filed by the house officer, and bound up with the patient's clinical record; but reports are sometimes lost. Of the 376 cases which form the basis of this report, in 39 no pathological report was found. In 337 cases the report of the gross and microscopic examination of the tumor (and usually of the axillary and supraclavicular glands, when removed) was present. It is probable that a pathological examination of every case was made.

In the interpretation of causes of death and their relation to possible recurrence, the writers have endeavored to err on the side of safety, and to accept no case as dying free from recurrence which was not above reproach. For this reason, 28 cases dying of "apoplexy," "paralysis," "multiple neuritis," "pleurisy," "pneumonia," "inanition," "gastro-enteritis," etc., have been arbitrarily assigned to the "died with recurrence" class. The 7 cases which have been admitted to the "died without recurrence" group will be discussed in detail in another place. Two patients who died within three years of operation, of diseases other than cancer, have been thrown out entirely as giving no data of value in determining the success of the operation. In this way a uniform interpretation of results was obtained, which, it is to be hoped, may be employed in the publication of statistics of other series of cases.

The information with regard to the 64 cases, here reported as alive and well, was obtained from the following sources: Letters from the patient were accepted as evidence in 38 cases where the patient lived too far away to come to the hospital for examination. Letters from acquaintances and relatives were received in 5 cases. Letters from physicians were received in 8 cases, and 13 patients came to the hospital for examination.

During the ten years from January 1, 1894, to January 1, 1904, 613 cases of breast cancer were entered on the records of the

Digitized by Google

Massachusetts General Hospital. Of this number 416 were cases of primary operation; 80 were re-entries of the above 416; 52 cases were discharged untreated, by or against the advice of the surgeon; 45 were patients first operated upon elsewhere and admitted for recurrence; and 20 were cases operated upon in the Massachusetts General Hospital before 1894 and readmitted with recurrence.

TABLE I.

1894–1903, *inclusive.*

Primary operations	416
Re-entries	80
Untreated	52
Recurrence from operation elsewhere	45
Recurrence from operation before 1894	20
Total cases	613

Of the 416 cases of primary operation, 376 were traced to a conclusive end-result. 38 could not be traced, and in 2 cases the results were inconclusive.

These 376 end-results have been divided into 5 groups as follows:

TABLE II.

Year.	Alive and well.	Alive with recurrence.	Died of operation.	Died without recurrence.	Died with recurrence.	Total for year	Total free of recurrence.	Per cent. free from recurrence including palliative cases and deaths from operation.
1894	3	...	...	2	27	32	5	
1895	2	1	...	...	41	44	2	
1896	10	1	7	1	32	51	11	
1897	5	...	1	1	25	32	6	
1898	4	...	3	...	27	34	4	
Total for 5 years, 1894–1898, inclusive.	24	2	11	4	152	193	28	14.5 per cent. (omitting palliative operations = 16 per cent.).
1899	7	3	...	...	28	38	7	
1900	7	...	2	1	28	38	8	
1901	4	2	...	2	32	40	6	
1902	10	1	1	...	28	40	10	
1903	12	...	1	...	14	27	12	
Total for 5 years, 1898–1903, inclusive.	40	6	4	3	130	183	43	23.5 per cent. (omitting palliative operations = 26 per cent.).
Total 10 years, 1894–1903, inclusive.	64	8	15	7	282	376	71	18.8 per cent. (omitting palliative operations = 20.9 per cent.).

Digitized by Google

The 64 cases reported alive and well have all passed the three year period without evidence of either local recurrence or internal metastasis, with the single exception of 1 case. This case had a recurrence in the axillary portion of the scar two years after the primary operation; the recurrent nodule was removed four years and eight months ago, and has not returned. The duration of life of these 64 cases is as follows:

TABLE III.

Duration of Life in 64 Cases Alive and Well.

3-4 years	9 cases.	9-10 years	4 cases.
4-5 "	13 "	10-11 "	8 "
5-6 "	5 "	11-12 "	6 "
6-7 "	6 "	12-13 "	2 "
7-8 "	7 "	13-14 "	1 "
8-9 "	3 "		
	43 "		21 "

Average of 64 cases equals 6 years and 10 months.

The oldest patient in this group was seventy-six and the youngest twenty-nine years of age. The consideration of the prognostic importance of the age of the patient, the duration of the disease and its situation in the breast will be taken up in connection with the data obtained from the study of all five groups.

Disability. It has been most gratifying to observe how little disability was produced, even by the most complete operation, when both of the pectoral muscles were removed. Reports upon this point were given in 53 of the 64 cases: 26 had "full" or "perfect" use of the arm, 20 had good use, 4 "fair," 2 only "a little," and in 1 case, in which sepsis and erysipelas occurred after operation, the arm was described as "stiff." It has been our experience that the functional impairment of the shoulder, which may be pronounced immediately after operation, disappears during the first and second year, and rarely causes any difficulty after that time. With regard to swelling of the hand and arm, as a result of the dissection of the axillary lymphatics and obstruction to the axillary veins, the results were found to be less satisfactory. In 48 cases information upon this point was available, and in 17 of

Digitized by Google

these cases swelling of the hand or arm was spoken of. It is probable that swelling of the upper arm is to be regarded as the direct result of the removal of the axillary lymphatic trunks; but swelling of the hand and fingers may probably be attributed to cicatricial pressure upon the vein. It is reassuring, however, to find that swelling of the arm occurs so commonly in cases without recurrence; and that it is not to be regarded necessarily as evidence of axillary recurrence.

Alive with Recurrence. Eight cases. Six of which have recurrent nodules in the scar, one in the spine and one in the ribs. The length of life, after the original operation in these cases, is as follows:

TABLE IV.

3– 4 years	1 case.
4– 5 "	1 "
6– 7 "	2 "
7– 8 "	2 "
10–11 "	2 "

One of the patients operated upon eleven years ago for colloid cancer had recurrence immediately after operation, which has slowly increased in size up to the present time, but has not yet been operated upon, causes no disability and has shown no evidence of generalization—a relatively non-malignant cancer. Two of the alive, with recurrence, cases are examples of so-called "late" recurrence—one being a case of adenocarcinoma, free from recurrence for seven years, and then developing symptoms of spinal recurrence; the other a case of medullary cancer, examined and found free from recurrence six years and nine months after operation, but developing a recurrence in the scar before the next report six months later.

Died without Recurrence. Seven cases died without signs of local or internal recurrence at a period more than three years after operation. These cases were as follows:

Two died of "debility and old age," at seventy-one and seventy-four years of age; nine years, and seven years and eight months, respectively, after operation. Two died of "consumption"—four and one-half and five and one-half years after operation. One case died of apoplexy six years after operation. This case was

Digitized by Google

not classed as an example of cerebral metastasis, as the patient was seventy-eight years of age, and had had already one attack of cerebral hemorrhage with almost complete recovery, three years before.

One patient died of acute renal disease four years and three months after operation, and was reported by her physician as free from local or internal recurrence, and the last of the 7 cases died of acute lobar pneumonia in the hospital four years and four months after operation, and a complete autopsy revealed no evidence of carcinoma.

Died of Operation. Fifteen cases died as an immediate result of the operation—14 in the hospital and one immediately after leaving. This gives an operative mortality of 15 in 416 cases—3.6 per cent. Eleven of these deaths occurred in the first five-year period, out of 215 operations (5.1 per cent.), and four deaths in the last five-year period (2 per cent.).

The causes of death were as follows:

Pneumonia	6
Pulmonary embolism	2
Hemorrhage and shock	4
Sepsis	3
	15

The pneumonia cases occurred during the months of March, April, June, and August. Three of the 6 pneumonias were in septic cases, and may possibly have been of embolic origin. Two of the pneumonia cases came to autopsy. Of the three deaths from sepsis, 2 were due to erysipelas.

Died with Recurrence. Two hundred and eighty-two patients died with symptoms of local or internal recurrence. Of this number 254 are reasonably certain to have had return of the disease, while 28 cases have been classed as probable recurrence, though not entirely beyond dispute. These cases were referred to in the beginning of the paper, and it was stated that it was our intention to err on the side of safety, and to class as recurrences all cases that were not above reproach. The causes of death given in the 28 disputable cases are as follows:

Digitized by Google

TABLE V.

28 Cases Dead with Probable Recurrence.

	Number of cases.	Duration after operation. Years.	Months.
Arteriosclerosis[1]	1	1	11
Paralysis and apoplexy[1]	7	0	9
		1	5
		2	5
		3	0
		3	2
		7	7
		11	0
Meningitis	1	1	2
Brain tumor	1	0	9
Heart and kidney disease	1	3	7
Cardiac hypertrophy	1	0	5
Cardiac insufficiency	1	0	6
Mitral stenosis	1	2	3
Pneumonia	4	(3–2) (0–3)	(0–7) (0–3)
Consumption	2		(2–7) (1–3)
Bronchitis	1	0	7
Pleurisy	1	3	4
Gastro-enteritis	1	1	3
Dysentery	1	1	5
Cancer of uterus	1	2	1
Multiple neuritis	1	0	10
Erysipelas	1	2	0
Inanition	1	2	11
	28		

Seven of these doubtful cases are known to have passed the three-year period without local recurrence in the scar.

With regard to the remaining 254 cases, dead with recurrence, a more detailed account will be given under the heading of recurrences. It is sufficient here to say that of the whole 282 cases dead with recurrence, the recurrence was local in the scar in 120 cases, and no recurrence in the scar was present in 65 cases. In the other 97 cases data upon this point were not obtainable.

The total number of cases free from recurrence over three years after the operation is obtained by adding to the 64 cases alive and

[1] The 8 cases of "apoplexy," "paralysis," and "arteriosclerosis" died at 36, 62, 69, 70, 75, 76, and 77 years of age, respectively.

Digitized by Google

well the 7 cases which died of other diseases without signs of recurrence over three years after operation—a total of 71 cases in which the operation may be presumed to have been successful. In view of the possibility of late recurrence, however, we do not wish to describe these cases as "cures."

The statistics for successful operations at the Massachusetts General Hospital for the ten-year period are thus: 376 cases of primary operation for breast cancer, with 71 cases free from recurrence three years or more after operation—18.8 per cent. (This includes palliative operations and deaths from operation.) Fifty-six of these cases had only palliative operations performed, and although 4 of these palliative operations were unexpectedly successful, they should not be counted in an estimate of the success of operations for radical cure of the disease. Leaving out the palliative cases, therefore, but retaining the cases which died of operation, we have 320 cases of radical operation with 67 successful results—20.9 per cent. for the whole ten-year period. The results during the last five-year period, when the more extensive operations have been performed, are better than those from 1894–98, inclusive. During the first period there were 160 operations for radical cure, with 26 successful results—16.2 per cent. During the last five-year period, from 1899–03, inclusive, there were 157 operations for radical cure, with 41 successful cases—or 26 per cent. It should be noted that the 15 cases of death due to operation have been counted as unsuccessful cases in these estimates, and have not been taken out from the entire number, as has been done in a certain number of other reports upon the end-results of cancer operations. We have wished to give a fair estimate from the patient's point of view, and to the patient the operation is equally a failure whether it causes her death immediately or fails to remove the whole of her disease. Such facts as we have been able to collect will be arranged under four main headings:

1. Extent of involvement.
2. Variety of cancer.
3. Duration of the disease.
4. Magnitude of the operation.

Digitized by Google

The extent of involvement is perhaps the most difficult point to determine, from a clinical point of view, as the symptoms do not invariably agree with the underlying pathological conditions. We have not attempted to make any study of the size of the tumor, as stated in the clinical examination of the patient, as these data were considered to be of significance only in connection with the variety of cancer present. The extent of involvement has been considered under the following headings:

1. Adherence to skin.
2. Adherence to chest.
3. Enlarged glands in axilla.
4. Enlarged glands in neck.
5. Cancer of both breasts.
6. Cancer of special anatomical structures.
7. Ulceration.

Adherence to Skin. Clinical records with regard to the adherence of the tumor to the skin were given in all but 41 cases. The skin was adherent in 262 cases, of which 42 remained free from recurrence—16 per cent. The skin was not adherent in 71 cases, with 23 free from recurrence—37 per cent. It is obvious, therefore, that the absence of this symptom is of relatively good prognostic import.

Adherence to Chest Wall. The tumor was recorded as adherent to the chest wall in 45 cases, of which 5 were free from recurrence—11 per cent. No adherence to the chest wall was recorded in 194 cases with 41 successful results—21 per cent. Another point of relative prognostic value that again bears out the accepted symptomatology of this disease.

Enlarged Glands in Axilla. Glands were felt in the axilla in 236 cases, of which 28 were successful results—12 per cent. The records state that no glands were felt in 117 cases, 34 of which remained free from recurrence—29 per cent. This fact is made more emphatic when we consider that it is the greatest exception for the glands removed as a routine from the axilla to be found free from cancer on microscopic examination. It is, therefore, obvious that the presence of palpable axillary glands is indicative of such a degree of involvement of those glands with cancer as to make the complete removal of the disease far more difficult than

Digitized by Google

in earlier and less extensive cases. It is quite possible that in early cases, without palpable enlargement of the glands, the disease is entirely within the glands, and can be readily removed, whereas in glands which are palpably enlarged the disease has extended through the capsule and along the lymphatic trunks, and become disseminated through the axillary fat to such an extent and in such minute strands that complete removal is very difficult, if not impossible, of achievement.

Enlarged Glands above the Clavicle. In 40 cases enlarged glands were felt above the clavicle before the primary operation, and of this number only 2 cases survive; in neither of these 2 cases were the glands removed found to be cancerous on pathological examination. Thus, not a single case in this series with palpably enlarged cancerous glands above the clavicle before the primary operation has been cured of the disease. This confirms the idea that cancerous glands above the clavicle practically contraindicate an operation for radical cure.

Cancer of Both Breasts. Both breasts were involved in 6 cases. In 4 both breasts were amputated. In 2 one side alone was removed. Five cases died with recurrence and 1 of sepsis following the operation. It is not probable that radical operation will succeed in saving many cases of double cancer of the breast.

Involvement of Exceptional Anatomical Structures. In three cases the axillary vein was involved in the disease, or was seriously torn, and had to be removed—all of these patients died with recurrence. In one patient, who unfortunately could not be traced, the mediastinum was opened, and cancerous glands removed by the resection of the second and third rib cartilages on the right side. In another case cancerous portions of the ribs and of the sternum were removed with a chisel and curette, but without success, and in a third the brachialis anticus muscle was found infected, and removed.

Ulceration of the tumor was present in 60 cases, of which 4 (6.6 per cent.) were free from recurrence. No ulceration was present in 316 cases, of which 67 remained well—21 per cent. The deduction is obvious that ulceration is of bad prognostic import.

The varying degrees of malignancy of the different varieties of

Digitized by Google

cancer form one of the most interesting features of the study of cases of cancer of the breast. In this series of 376 cases, pathological reports were not obtainable in 39, and the report gave the diagnosis of "cancer" only, without specifying the variety, in 127 cases. In the other 212 cases detailed reports were available.

Medullary Carcinoma. There were 137 cases of medullary carcinoma, of which 105 survived the operation for radical cure. (In estimating the malignancy of the different varieties of cancer, palliative operations and cases dying of operation have been excluded as contributing in no way to information upon this point.) Of these 105 cases, 20 were free from recurrence, *i. e.*, 19 per cent.

There were 46 cases of scirrhus carcinoma—43 of which survived the operation for radical cure; of this number 10 were successful cases—23 per cent.

Of adenocarcinoma, there were 24 cases, of which 21 survived the radical operation. Ten of the cases are free from recurrence—47.6 per cent.

There were 4 cases of colloid carcinoma—1 of which was a palliative operation. Of the 3 other cases, 1 died without recurrence at seven years, eight months; 1 is now alive with recurrence eleven years after the operation, and 1 is alive and well three years and two months after operation, giving 66 per cent. of successful operations.

TABLE VI.

Variety of Carcinoma.

	Cases.	Cases surviving radical operation.	Cases free from recurrence.	Per cent.
Medullary	136	104	19	18.2
Scirrhus	46	43	10	23.0
Adenocarcinoma	24	21	10	47.6
Colloid	4	3	2	66.0
Cancer, variety not specified	127	107	18	16.8
No pathological report	39	31	8	25.8

From these facts it is clear that of the four main varieties of carcinoma of the breast, medullary carcinoma is the most grave. Scirrhus is less serious, and adenocarcinoma and colloid carcinoma are relatively the least malignant varieties of cancer. This is in

Digitized by Google

accord with the experience of other writers, and is, in fact, the generally accepted belief.

Other rarer varieties of cancer have occurred in this series of cases, but in numbers scarcely large enough to justify definite conclusions. Thus, there was 1 case of "cancer cyst" alive and well four years after operation. There were 8 cases of Paget's disease of the nipple, of which only 1 survives—12½ per cent. There were 7 cases of radical operation for cancer in the lactating breast (commonly regarded as one of the gravest possible conditions), and of these 2 are now alive and well—28.5 per cent.

The duration of the disease, as estimated from the clinical history of the patient, gives very unsatisfactory data for the formation of an opinion as to the probability of successful operation. No constant increase or diminution of successful operations is observed with increasing duration of the tumor. It is probable that the duration is not estimated accurately by the patient in many cases, and it is certain that other considerations, such as the variety of the tumor and the extent of involvement of the tissues with disease, are of far greater significance than the mere duration of the tumor taken by itself. It would be futile to deny that in the individual case the longer the duration the less the expectation of cure; but in a collection of many cases this fact is of relatively minor significance as compared to other considerations. It is true that the percentage of successful cases was somewhat greater when the disease was of from one to six months' duration than when it had lasted from six to twelve months, but the percentage of recoveries was greater in the long-standing cases of from two to fifteen years' duration. Of the 375 cases, in which we have collected these statistics, the results appear in the following table:

TABLE VII.

Duration.

Time.	Number of cases.	Number of successful cases.	Per cent.
1 to 6 months	148	30	20.0
6 to 12 months	108	18	16.6
Up to 1 year	256	48	18.7
1 to 2 years	70	13	18.5
1 to 15 years	41	10	24.0

Digitized by Google

The Magnitude of Operation. The extent of the operation performed upon these 376 cases was indicated by the classification into four groups of operations. *Complete*, *Semicomplete*, *Incomplete*, and *Palliative*. Each of these groups will now be taken up for detailed consideration.

TABLE VIII.

Operations.

	Total cases.	Alive and well.	Alive with recurrence.	Died of operation.	Died without recurrence.	Died with recurrence.	Successful cases.	Percentage successful.
Complete operation . .	160	24	4	7	2	123	26	16%
Semicomplete	75	18	0	3	1	53	19	25%
Incomplete	85	20	4	1	2	58	22	25%
Palliative	56	2	0	4	2	48	4	7%

Complete Operations. One hundred and sixty cases had a complete operation performed, including the removal of the whole breast and axillary contents the removal of the pectoralis major muscle and either division (4 cases) or removal (156 cases) of the pectoralis minor. The results of these 160 operations were as follows: 7 died of operation; 123 died with recurrence; 2 died without recurrence; 4 are alive with recurrence, and 24 alive and well. There were thus 26 successful cases—16 per cent.

In 26 cases the neck was dissected for the removal of glands above the clavicle. In 7 cases the glands were felt before operation. In the other cases the neck was dissected as part of the routine operation. Of all the 26 cases, 3 survive; 1 in which the glands removed as a routine measure were found to be cancerous; the other 2 were cases in which enlarged glands were felt and removed, but were not found to be infected.

The question of whether removal or division of the pectoralis minor is the safer procedure cannot be answered by these statistics, as division of the minor without removal was done in only 4 cases. These cases all died, with recurrence.

The amount of skin removed with the breast has seemed to the writers a matter of great importance, and yet accurate data can-

Digitized by Google

not be obtained for the comparison of results from the hospital records. It was possible, however, to contrast the cases in which the wound was closed directly by suture with those in which so large a skin defect was made that a plastic operation or skin graft was required to close the wound. In 67 of the complete operations, a plastic operation (either the flap operation of Dr. J. Collins Warren, or the sliding over of the other breast—after the method of Dr. S. J. Mixter) or a skin graft was performed. Of this number 13 were successful cases—19 per cent. Whereas, in the 98 complete operations in which the wound was sutured directly, there were only 11 successful cases—11.7 per cent. The difference between these cases was even more marked when local recurrence was considered. Of the 67 cases with plastic operation or skin graft, statements with regard to the presence or absence of local recurrence were available in 52 cases, and in 30 of these (57.6 per cent.) no local recurrence in the scar took place. Of the complete operations in which the wound was sutured directly, data were available in 68 cases and 30 remained free from local recurrence—44 per cent. This, we believe, is good evidence of the importance of removing a very generous amount of the skin over the breast in radical operations.

Seventy-five operations were classed as *semicomplete.* In these cases the complete operation was performed, as detailed above, with the exception of the division or removal of the pectoralis minor. In these cases the minor was not disturbed. Of the 75 cases, 18 are alive and well, and 1 dead without recurrence; 19 successful cases—25.3 per cent. The greater number of these semicomplete operations (46 out of the 75) were performed in the five-year period from, 1899 to 1904.

Incomplete operations include those performed, with a view to radical cure, but in which the requisites of the complete or modern operation were not complied with. In the majority of these operations the pectoralis major was not removed; in some the whole breast was not taken, and in others, the dissection of the axilla was incomplete. There were 85 such operations, the greater number of which came in the earlier years, from 1894 to 1898.

Digitized by Google

The results, however, were surprisingly good, as there were 22 cases free from recurrence—25.9 per cent.

These percentages are somewhat disconcerting, and suggest, at first sight, that better results are to be expected from the less radical operations. This supposition, however, is not to be entertained, and another explanation must be sought. After some consideration we have come to the conclusion that the explanation of this apparent paradox lies in the choice of cases for operation. Before the complete operation came to be generally practised, surgeons performed an incomplete operation, to be sure, but they performed it only in such cases as by the small size of the tumor and freedom from attachment to the skin and to muscle, gave promise of possible cure. As the complete operation developed, there appeared to be hope of saving cases of a more advanced character, and the complete operation has undoubtedly been performed in many cases of this series in which the wide extent of the disease made a successful result a practical impossibility. This fact has been appreciated by a number of the surgeons at the hospital, and the complete operation is now applied by them more conservatively, and only to the early cases in which a cure may reasonably be expected; while other surgeons perform the complete operation in nearly every case, with the idea of giving every chance for cure, however remote that chance may be.[1] It is due to these facts, we think, that the results of the complete, as compared to the incomplete, operations make so poor a showing. So far as the semicomplete operation is concerned the removal of the pectoralis minor, except for allowing easier exposure of the axilla, does not, in our opinion, remove tissue which is especially liable to cancerous infection, and is not, for that reason, a detail to be insisted on.

Palliative operations were performed in 56 cases (or 15 per cent.) of the cases operated on. These operations were done without hope of radical cure, and cancerous tissue was believed to have been left in the wound at the close of the operation. Four of these cases, however, were free from recurrence; 2 alive and well

[1] Lazarus-Barlow and Campiche, Archives of Middlesex Hospital, 1905, vol. v. and Meissl, Wiener klinische Wochenschrift, December 22, 1904.

Digitized by Google

nine years and nine months, and five years and nine months, after operation. Two others died without recurrence—1 nine years after operation, of old age and debility, at seventy-one years; 1 four years and three months after operation, of renal disease. In 1 of these cases, now alive and well, a supposedly benign tumor was excised under cocaine and found to be a carcinoma. The patient refused operative treatment, and has had no return of the disease. The operative mortality of the palliative operations, 4 cases out of 56 (7 per cent.), was higher than with any other class of operation, but is attributable, in our opinion, to the feeble condition of patients with advanced cancer, rather than to the severity of operation. At this point it may be reasonable to call attention to the fact that the cases we are reporting have not been selected in any way, but are given as they are recorded consecutively in the hospital records. Thus 85 per cent. of our cases have been subjected to an attempt at radical cure, whereas the number of cases really entitled to expectation of benefit from a radical operation was probably much less. We would suggest that statistics of end results could be judged more fairly if the number of cases rejected as unfit for radical operation, during the same period, were also published.

Recurrences. The many different forms in which cancer makes its reappearance after attempted radical operations for its removal, are one of the most interesting features of that disease. In 178 of 290 cases the site of recurrence could be determined, and in several cases the disease returned in two or more different portions of the body.

Site of Recurrence. Data upon the presence or absence of recurrence in the scar, or in internal organs, were available in 264 cases and the organs and regions involved appear in the following table:

TABLE IX.

Site of Recurrence in 264 Cases

Local in scar	126	Other bones	14
No local recurrence in scar	138	Cranial	13
Lymphatic glands	58	Lung and mediastinum	65
Other breast	15	Abdomen	51
Spinal	19	Disseminated	11

Digitized by Google

It is of interest to note the fact that of 264 cases in which data were obtainable no local recurrence took place in the scar in 138—52 per cent. In over one-half of the cases operated upon the local disease was removed, and the patient would have been cured if metastasis in internal organs had not already taken place, or did not result, as seems possible in certain cases, from the manipulations of the operation. It is to be remembered also that the proportion of cases free from local recurrence after complete operations with plastic or skin graft (57.6 per cent.) was greater than when other less extensive operations were performed.

The relative frequency of metastasis in the chest, and in the abdomen, is to be attributed, we believe, to the predisposition of the tissues of the lung and of the liver to cancerous metastasis. It is apparent that the substance of the lungs, the liver, and the bony skeleton are especially fertile soil for cancer growth. The lymph glands affected in recurrence are those especially of the axilla, the supraclavicular region, and the mediastinum. Recurrence in the other breast occurred in 15 cases. The number of spinal recurrences is notable (19) as being greater in number than all of the other bones. It is not proved by autopsy examination, but probably the majority of recurrences in the spine are due to bone metastasis, rather than to recurrence directly in the spinal canal or in the cord.

The 14 cases of recurrence in other bones are divided as follows: In 1 case both the sternum and ribs and humerus were affected; in 11 cases the sternum and ribs were involved, and in 2 cases recurrence took place in the femur.

The cases of cranial recurrence are mainly those of death with symptoms of cerebral hemorrhage; in this group have been included, also, cases dying of "meningitis," "brain tumor," and "arteriosclerosis." The occurrence of symptoms of apoplexy as a terminal phenomenon, due to hemorrhage into the tumor, in cases of metastatic cancer of the brain has been so constant in our experience as to give little room for discussion on the propriety of classing cases of apoplexy as cranial metastases unless proof to the contrary can be presented.

Digitized by Google

The exact date of appearance of recurrence after operation could not be obtained in the majority of the cases here considered. The duration of life after operation, however, gives some light upon this point, and has been arranged in the following table:

TABLE X.

290 *Recurrences.*		*Duration of Life after Operation.*	
Not stated	16	6– 7 years	9
Up to 1 year	83	7– 8 "	5
1–2 years	88	8– 9 "	2
2–3 "	44	9–10 "	1
3–4 "	25	10–11 "	1
4–5 "	11	11–12 "	2
5–6 "	3		290

Forty-one of the 290 recurrent cases (14 per cent.) lived over three years after the operation, and of this number 13 never showed any local recurrence and 28 had recurrence in the scar. It is clear that the statement that a case survived three years after operation, even without a local recurrence, does not indicate in the least that this will be a successful result; although such evidence has been offered in many different reports of the results of operations for cancer of the breast.

Late Recurrence. As has been stated in the preceding paragraph, 13 cases lived over three years without local recurrence, only to die later of internal metastasis. Four other authentic instances of late recurrence occur in this series of cases. Two of these had local recurrence in the scar of operation which did not appear until eight years and eight years and five months, respectively, after operation. One was free from signs of recurrence for seven years and then developed evidence of recurrence in the spine, and another for six years and nine months, and then developed evidence of recurrence in the abdomen. Thus 17 cases out of 290 had recurrences, either internal or in the scar, which did not appear until over three years from the data of operation; or, otherwise expressed, of 38 cases (64 alive and well, 7 dead without recurrence, and 17 late recurrences) which survived the three-year period without evidence of recurrence, 17 showed later recurrence or metastasis (19 per cent.). This is the exact percentage

Digitized by Google

of late recurrences given by Schröder[1] as a result of the study of 347 cases of cancer of the breast from the Rostock clinic.

Age of Patients. The age of the patient has been considered by a number of writers to be of some value in prognosis on account of the supposed virulence of cancer in younger women. This, however, is not borne out by our statistics, and in fact no regular increase or diminution of successful results is found with advancing years.

TABLE XI.

Age of Patients.

Ages.	Number of cases.	Number free from recurrence.	Successful cases.
20–30	5	1	20 per cent.
30–40	56	4	7 "
40–50	120	29	24 "
50–60	107	16	15 "
70–80	21	2	9 "
Not stated	2		

It is probable that the variety of cancer and its extent is of much greater importance than the mere age of the patient. Possibly the occurrence of scirrhus cases late in life has given rise to the supposition that patients of advanced years were entitled to a more favorable prognosis. This we do not believe to be the case.

Situation of Tumor in the Breast. We have believed that tumors situated in the inner hemisphere of the breast were, as a rule, more likely to produce mediastinal metastases than those in the outer quadrants which spread more directly into the lymphatics of the axilla. (Oelsner.)[2] With this in mind, we have divided the 376 cases into three groups, as follows:

TABLE XII.

Inner vs. Outer Hemispheres.

	Number of cases.	Free from recurrence.	Per cent. of successful cases.
Inner hemisphere	43	10	23
Outer hemisphere	160	43	27
Central location, whole breast, or situation not stated	173	18	10

[1] Beit. z. klin. Chir., Band xlv, H. 3, p. 659. Compare, also, Curtis, Annals of Surgery, xliii, p. 216.

[2] Archiv. f. klin. Chir., 1901, Band lxiv, p. 134

Digitized by Google

The difference, though slight, is in favor of the tumors in the outer hemisphere. The extreme gravity of the last group (the tumors situated in the central portions or involving the whole breast) is undoubtedly due to the advanced stage of growth at which most of these cases came to operation.

Oöphorectomy. Before proceeding to summarize the results of this investigation, it is to be noted that 3 of the cases in this series had the operation of oöphorectomy performed (Beatson's operation) for inoperable recurrence. One patient lived three years, 1 eight months, and 1 only one month after the operation, and all died of recurrence. Another case, which was not operated upon in this clinic, entered for recurrence, and had Beatson's operation performed at the Massachusetts General Hospital, but died a few months later. It was not shown in any of these cases that oöphorectomy delayed in any way the progress of the disease, even in the case which lived three years; for two operations for local recurrence were required during that time.

SUMMARY.

1. Out of 416 cases of primary operation for cancer of the breast at the Massachusetts General Hospital, from 1894–1903 inclusive, 376 were traced to a conclusive end result at an average period of eight years after operation.

2. Sixty-four cases were alive and well and 7 died without recurrence over three years after the operation.

3. Counting in the operative mortality, there were 320 attempts at radical cure, 67 of which, or 20 per cent., were successful.

4. During this same period palliative operations were performed on 56 patients (15 per cent.) and 52 cases were discharged untreated.

5. Cases in which the tumor was ulcerated, or was adherent to the skin or to the chest wall; and cases in which the axillary glands were palpably enlarged, gave notably less promising results than when these conditions did not exist.

Digitized by Google

6. No case with palpably enlarged cancerous glands above the clavicle, and no case of cancer of both breasts, was cured.

7. Medullary carcinoma was more grave than that of the scirrhus type, and adenocarcinoma and colloid were relatively of a far less malignant type.

8. The duration of the disease, and the age of the patient, other than in the individual case, exerted little influence on prognosis.

9. Extensive operations, with wide removal of skin, gave the greatest freedom from local recurrence. Removal of the pectoralis minor appeared to be of slight significance. Incomplete operations on early cases yielded better results than extensive operations on cases which were well advanced.

10. Recurrence in the scar occurred in less than one-half of the cases. Internal metastasis was most frequent in the lungs, mediastinum, in the axillary and supraclavicular glands, the liver, and the spine.

11. Seventeen out of 88 cases, or 19 per cent., of those passing the three-year limit without evidence of recurrence showed recurrence later, and 4 cases developed recurrence six years or more after the operation.

Digitized by Google

CARCINOMA OF THE BREAST.

A STUDY OF THE PATHOLOGICAL CONDITIONS AND THEIR RELATION TO THE QUESTION OF RECURRENCE.

By ARTHUR TRACY CABOT, M.D.,
BOSTON.

My hospital cases have been included in the report made from the Massachusetts General Hospital. The following report concerns only my private cases down to the year 1904. In this series were many advanced cases in which the operation was a desperate effort to prolong life. There was no selection of cases, operation being done in every case that offered except in one, where the coexistence of advanced heart disease and a large adherent carcinoma led to palliative efforts with the *x*-rays. The cases were all carefully studied pathologically and the after-history has been closely followed. There were 42 cases. All recovered from the operation, and of these 9 are entirely free from recurrence. The time elapsed since operation in these 9 cases has been: in 1 case, four years; 1 case, five years; 1 case, seven years; 1 case, eight years; 2 cases, ten years; 1 case, eleven years; 1 case, fourteen years; 1 case, nineteen years; 5 other cases are still living, though they have had a recurrence of the disease; 1 of them was operated upon three years ago, 3 of them four years ago, and 1 five years ago. The remaining 28 cases have died of the disease. Of these, 17 died in one year, 2 lived two years, 1 lived three years, 2 lived four years, and 6 lived five years. Of the 9 cases that are well without recurrence, the pectoral muscles were removed in 2. In the remaining 7 the breast and axillary contents were removed without removal of the muscles. In the 5 cases still living with

Digitized by Google

recurrence, the muscles were removed with the breast and axillary contents. Of the 28 cases that have died, the muscles were removed with the breast and axillary contents in 12 cases. In the remaining 16 cases the breast and axillary contents alone were removed.

NATURE OF GROWTH. In the 9 non-recurrent cases the disease was usually of a mild type. In Case 1 it started as Paget's disease of the nipple, and at the time of removal a cancerous nodule was appearing in the breast beneath; 3 of the other cases had carcinoma of adenomatous type; 3 had small scirrhous cancers; 1 had a small plexiform medullary carcinoma, and in 1 case of unmistakable carcinoma the pathological report has been mislaid and cannot be found. In 6 of these cases careful search failed to show any infected lymph nodes. In the other 3, moderate infection of lymph nodes was found. In 2 cases (Nos. 1 and 7) of the non-recurrent series, a little epithelioma of the face coexisted with the breast cancer. In Case 1 after fifteen years a second epithelioma appeared on the opposite side of the face. In the 32 cases where the disease recurred the pathologist failed to report condition of glands in 3 cases. In the remaining 29 cases there were but 3 cases in which at the time of the first operation the pathologist reported a failure to find infected glands. From this it will be seen that the instances of non-recurrence were in cases of localized disease which had not or had only just begun to invade the lymphatic system. On the other hand, in the recurrent cases, with but three exceptions, the lymphatic system was already seriously involved. It is interesting to note that in 2 of these 3 cases in which infected lymph nodes were not found there was no local recurrence nor involvement of neighboring lymphatics, but the symptoms pointed to a distant internal secondary growth. In the third of these cases the recurrence was in the supraclavicular glands.

Case 19 was interesting from the fact that this patient had had the other breast removed thirty years before for what was believed to be a cancer; and this belief was strengthened by the fact that recurrent nodules had been removed on three occasions since,

Digitized by Google

the last one fourteen years before the second breast developed the disease. Unfortunately, no microscopic examination had been made of any of these specimens.

From this study it appears that in this small series of cases the question of recurrence depended more on the character of the growth and the degree of involvement of the lymphatic system than upon the thoroughness of removal. If the disease had affected many lymphatic glands it was sure to recur, even after a thorough removal of all of the muscles and axillary contents. On the other hand, in the 9 cases that did not show a recurrence the lymphatic involvement was slight in all, while in 7 out of the 9 the muscles were not removed. These facts give us a basis for a somewhat greater accuracy in prognosis, but should not be used as arguments against extensive radical operations, for it is impossible in any given case to tell how far the cancer cells have penetrated the surrounding lymphatics, and the chance of getting ahead of the disease is improved when the efferent lymphatics have been removed to as great a distance as possible.

In Case 12 the nodule in the breast was small and so situated in the centre of the gland that I felt safe in leaving the pectoral muscles. The recurrence occurred in the muscle thus mistakenly spared, and since that experience I have removed the muscle in all cases.

Digitized by Google

Table of Recurrent Cases.

No.	Age.	Name.	Extent of involvement.	Duration.	Date of operation.	Magnitude of operation.	Variety of carcinoma.	Recurrence.	Result.
1	28	Mrs. P.	Lump as large as hen's egg over edge of sternum, skin adherent. Glands in axilla.	2 to 3 years.	1885.	Breast and axilla.	Border line between medullary and scirrhous cancer. Infected glands found.	Local recurrence.	Died, no date.
2	About 42	Mrs. G.	Tumor beneath nipple, which was retracted and hard. Axillary glands.	6 months.	May, 1889.	Breast and axilla.	Cancer with implication of axillary glands.	Op. again in Oct., 1899. Local recurrence in axilla.	Died in 1890.
3	48	Mrs. H.	Small nodule in outer part involving skin, two pea-sized nodules near by. In axilla small mass of medullary looking glands.	4 months.	March, 1890.	Breast and axilla.	Scirrhous cancer of breast and axillary glands.	Probable.	Died in 1892, in England, of pleurisy.
4	About 60	Mrs. S.	Nodule size of pecan nut. Glands in axilla.	3 months.	1890.	Breast and axillary contents.	Scirrhous cancer. Glands in axilla affected.	Probably first in lung.	Died in 1891, of recurrence.
5	60	Mrs. L.	Dense retracting nodule outside of nipple.	Just noticed.	1891.	Breast removed; axilla dissected.	Medullary cancer. No infected glands found.	Oct., 1905. Operated for recur. Supraclavicular.	Died in 1897 from recurrence.
6	...	Miss F.	Large retracting nodule. Axillary glands much enlarged.	.....	Nov., 1891.	Breast removed; axilla dissected.	Cancer enlarged and infected axillary glands found.	Dec., 1894. Probably in mediastinum.	Died in 1895.
7	60	Mrs. H.	.....	.....	July, 1892.	Breast removed; axilla dissected.	Carcinoma.	Feb. and July. Op. for recurrence.	Died(?)
8	40	Miss B.	Nodule beneath nipple entire thickness of breast and through into fascia. Glands in axilla.	Some mos.	Sept., 1892.	Breast removed; axilla dissected.	Carcinoma. Numerous infected glands in axilla.	Small cancerous part removed f'm axilla in 1897.	Died.
9	About 50	Mrs. M.	Nipple retracted. Implication of lymph glands.	8 months.	1894.	Breast removed; axilla dissected.	Diffuse scirrhous cancer with implication of the lymphatic glands.	Recurrence in liver and elsewhere.	Died 1 yr. later.
10	54	Mrs. G.	Large retracting nodule. Axillary glands enlarged.	9 months.	1894.	Breast removed; axilla dissected.	Cancer. Glands infected.	Op. for glands above clavicle in 1895.	Op. in angle of jaw. Died in 1895.
11	...	Mrs. D.	Contracting nodule size of large-cherry beneath nipple. Several glands in axilla.	.....	.....	Breast removed; axilla dissected.	Medullary cancer with secondary implication of lymph glands.	Op. for recurrence, March, 1898, probably in chest.	Died 1 yr. after recurrence.
12	48	Mrs. H.	One small nodule of carcinoma in middle of breast.	Recently discovered.	March, 1896.	Breast and entire axillary contents removed.	Typical carcinoma.	First in pect. mus. April, 1897. Nodules removed at different times. Metastases stomach and brain.	Died April, 1901.

Digitized by Google

13	60	Mrs. M.	Diffuse fibrous thickening throughout gland. Small retracting nodule near nipple. Gland in axilla.	Few weeks.	June,	1896.	Breast and axillary contents removed.	Scirrhous cancer. One small infected gland found.	Sept., 1896. Nodules removed.	Died Fall of 1897.
14	45	Miss P.	Diffuse and ill-defined growth occupying considerable part of breast.	Recently noticed.	Dec.,	1897.	Breast removed and axilla dissected.	Medullary cancer. Numerous lymph glands infected.	Sept , 1899, in chest	Died in 1899.
15	58	Mrs. L.	Extensive hard mass in middle of breast.	Some mos.	July,	1898.	Breast removed and axilla dissected.	Carcinoma with metastases in axillary fat tissue.	Recurrence within a year. Local and general.	Died in 1899.
16	45	Miss G.	Large nodule in breast and palpable glands in axilla.	Some mos.	Sept.,	1898.	Breast removed and axilla dissected.	Typical carcinoma. One small nodule carcinoma tissue found in neighborhood of large artery.	Recurrence in pleura.	Died Oct., 1899.
17	50	Mrs. P.	Diffuse infiltrating growth occupying greater part of corpus mammæ. Axillary glands enlarged.	Some weeks.	Jan.,	1901.	Breast and costal portion of pectoralis major completely removed. Axilla dissected.	Medullary cancer with lymphatic and probably venous infection.	July, 1904, in edge of sternum and rib.	Died Aug., 1906.
18	52	Mrs. A.	Diffuse thickened area occupying about 6 cm. in generally fibrous breast. Lymph nodes in axilla.	Just noticed.	Oct.,	1901.	Breast and costal portion of pectoralis major removed. Axilla dissected.	Scirrhous cancer with secondary infection of the lymph nodes.	Op. for recurrence in skin May and Oct., 1902, 1903, 1904.	Died Mar., 1906.
19	71	Mrs. B.	Small breast with retracting nipple, 2 flat elevated infiltrations from skin. Other breast removed in 1872.	Some mos.	Feb.,	1902.	Breast and pectoralis major removed. Axilla dissected.	Scirrhous cancer with secondary infection of skin.	Dec., 1904. Many supraclavicular glands.	Died Oct., 1906.
20	48	Mrs. E.	Beneath nipple retracting fibrous growth about 2 cm. in greatest extent.	.....	April,	1902.	Breast and both pectoral muscles removed. Axilla cleaned.	Scirrhous cancer and secondary infection of axillary lymph glands.	Soon.	Died Oct., 1902.
21	About 68	Miss N.	Dense nodule 1.5 cm. in diameter. No glands found in axilla.	.....	June.	1902.	Breast and pectoralis major and minor removed. Axilla cleaned.	Cancer of scirrhous type. No infected lymph nodes found.	Recurrence probably in spinal column, 1904.	Died soon after in 1904.
22	About 58	Mrs. R.	Diffusely fibrous breast and in it a dense nodule 2 cm. in diameter. Glands in axilla.	Some mos.	Oct.,	1902.	Breast with pectoralis major and minor removed. Axilla dissected.	Scirrhous cancer and secondary infection of axillary lymph nodes.	June, 1903, local recurrence.	Died.
23	About 50	Mrs. B.	Hard, diffuse, ramifying growth. Axillary glands.	Some weeks.	Dec.,	1902.	Breast with pectoralis major and minor removed. Axilla dissected.	Diffuse adenocarcinoma with infection of axillary glands.	Aug., 1904. Several large glands in neck.	Died 1907.
24	42	Mrs. H.	A hard nodule about 2 to 3 cm. in diameter.	10 months.	Dec.,	1902.	Breast with axillary contents removed with sterno portion of pectoralis major.	Adenocarcinoma of rather a scirrhous type with commencing axillary infection.	May, 1907, recurrence along axillary vein and at root of neck.	Living.
25	75	Mrs. S.	Breast almost entirely occupied by a hard tumor. Axilla contained several hard nodules.	3 months.	March,	1903.	Breast and pectoral muscles removed. Axilla cleaned.	Medullary carcinoma with secondary involvement of lymph channels and pectoral muscles	July, 1903. Local recurrence.	Died Dec., 1904.

Digitized by Google

TABLE OF RECURRENT CASES.—*Continued.*

No.	Age.	Name.	Extent of enlargement.	Duration.	Date of operation.	Magnitude of operation.	Variety of carcinoma.	Recurrence.	Result.
26	51	Mrs. D.	Hard tumor 4 cm. in diameter and second nodule 1 to 1½ cm., near axilla border. Several glands in axilla.	.....	March, 1903.	Breast and pectoral muscle removed. Axilla cleaned.	Carcinoma. Several infected nodules found in axilla.	July, 1906. Arm much swollen. Much pain.	Living.
27	About 63	Miss H.	.....	.....	April, 1903.	Breast and pectoralis major and minor removed. Axilla cleaned.	Carcinoma.	Sept., 1905, recur. nodules in skin and lymph node removed in 1905 and twice in 1906.	Living.
28	About 58	Mrs. C.	Tumor about 4 cm. in diameter beyond limit of mammary gland in direction of axilla.	Some weeks.	June, 1903.	Breast and pectoral muscles removed. Axilla cleaned.	Typical carcinoma. A small metastases in one lymph gland.	First in Sep., 1905. Operation in 1905 to 1906.	Living.
29	65	Mrs. S.	Outer side of nipple hard tumor 10 to 15 cm. in diameter, not adherent. Several nodules in breast.	2 years.	Oct., 1903.	Breast removed with pectoral muscles. Axilla cleaned.	Adenocarcinoma with involvement of axillary glands. Gland under pectoral muscle.	Dec., 1904, much pain in chest both sides.	Died.
30	57	Mrs. DeW.	Large pendulous breast with hard lump in upper part. Glands in axilla.	7 months.	Jan., 1904.	Breast removed with pectoral muscles and axilla dissected.	Scirrhous cancer with cancerous axillary lymph nodes.	Aug., 1904, local and general recurrence.	Died.
31	About 65	Miss C.	Ulcerated surface over tumor about size of five-cent piece. Several enlarged glands in axilla.	.....	Jan., 1904.	Breast and pectoralis major removed, pectoralis minor cleaned on both surfaces. Axilla dissected.	Scirrhous carcinoma. No infected glands found.	Jan., 1907, suspicious rheumatic pain & cachexia. No local recur.	Living.
32	About 36	Mrs. H.	Indurated growth about 3 cm. in diameter. Breast tissue everywhere enlarged and fibrous. Several large lymph nodes.	Few weeks	Feb., 1904.	Breast and pectoralis major and minor removed, and tissue in subscapular and subclavicular regions dissected and axilla cleaned.	Medullary cancer with general epithelial proliferation. Secondary infection of lymph nodes.	May, 1906, beneath clavicle.	Died Jan., 1907.
33	...	Mrs. B.	Outer portion breast occupied by diffuse hard growth infiltrating the tissue in all directions. Glands in axilla.	.....	July, 1904.	Breast and pectoralis major and minor, glands removed from apex and surface of subscapular.	Diffuse medullary carcinoma with involvement of axillary glands.	Recurred locally.	Died 1905.

Digitized by Google

Table of Non-recurrent Cases.

No.	Age.	Name.	Extent of involvement.	Duration.	Date of operation.	Magnitude of operation.	Variety of carcinoma.	Time elapsed.
1	About 50	Miss H.	.....	Some months.	Nov., 1888.	Breast removed and axilla cleaned out.	Paget's disease.	19 years.
2	54	Mrs. S.	Nodule size of horse-chestnut. No glands in axilla.	10 years.	Dec., 1893.	Entire breast, axilla cleaned out, and connective tissue between breast and axilla removed.	Scirrhous cancer. No infected glands found.	14 years.
3	60	Miss S.	Small nodule.	Recently discovered.	April, 1896.	Breast removed and axilla cleaned out.	Scirrhous cancer. No infected glands found.	10 years. Died in 1906 of pneumonia.
4	About 36	Sister A.	Chronic fibrous thickening; one point size of pea showed scirrhous cancer.	Just discovered.	July, 1896.	Whole breast and axillary contents removed.	Scirrhous cancer. No infected glands found.	11 years.
5	52	Mrs. W.	Small nodule in breast.	Some weeks.	July, 1897.	Breast removed and axilla cleaned out.	Carcinoma of adenomatous type. Two lymphatic glands show metastases.	10 years.
6	About 55	Mrs. B.	Irregular rounded growth 2.5 to 3 cm. in diameter. Skin not involved. No glands in axilla.	Recently discovered.	April, 1899.	Breast and axillary contents removed.	Plexiform medullary cancer. No infected glands.	8 years.
7	About 67	Mrs. M.	Nodule deep in upper outer quadrant 1.5 cm. in greatest diameter. No glands in axilla.	Recently discovered.	Feb., 1900.	Breast removed and axilla cleaned out.	Adenocarcinoma of mild type. No affected lymph nodes found.	7 years.
8	32	Mrs. P.	A dense nodule about 2 cm. in diameter. Commencing infection of lymph nodes.	Few months.	Oct., 1902.	Breast and pectoralis major removed, axilla cleaned out, dissection carried as far as subscapular vessels.	Early cancer of tubular type of alveoli. One lymph node affected.	5 years.
9	About 45	Mrs. W.	.....	.....	April, 1908.	Breast and axillary contents removed with pectoralis major and minor and all glands and tissue up to clavicle.	Carcinoma. Lymph nodes enlarged.	4 years.

Digitized by Google

Attention should, I think, be directed to the danger of recurrence from the self-inoculation of the wound with cancer cells set free during operation. This danger is to be reckoned with when a doubtful growth has been cut into for the purpose of establishing the diagnosis before proceeding to its thorough removal. If the lymphatic channels between the breast and the axillary glands or the muscles have been cut across during operation there is danger that during subsequent manipulations cells contained in those channels may be pressed out into the wound. The possibility of this occurring is a reason for removing breast, muscle, and axillary contents in one mass and for keeping the dissection outside of the lymphatic distribution as far as possible. When a cancer has been cut into for purpose of diagnosis the opening should be tightly closed before further operation is undertaken, and every precaution should be taken by changing instruments, etc., to avoid inoculation. Irrigation of the wound may be used on such occasion as an additional safeguard, and in cases where the operation has gone close to the cancer, or through suspicious tissues, I have applied tincture of iodine to the surface of the wound after the manner more commonly employed in the presence of tuberculosis; and this procedure has seemed to me to prevent a quick recurrence when such appeared otherwise inevitable.

X-RAY TREATMENT OF MAMMARY CANCER. In one case, above alluded to, an inoperable cancer was treated by the *x*-rays for nearly two years, and it was the opinion of those who watched the patient that the growth was checked and delayed by this treatment.

In Case 18 several little nodules appeared in the skin six months after operation. These were promptly removed, but others soon appeared, and were again removed, only to be followed by still others.

The *x*-ray treatment was then adopted, and under it several nodules disappeared and further reappearance was distinctly checked. For three years, under intermittent periods of *x*-ray treatment, the disease made little appreciable progress, but then evidence of deeper trouble in the chest and back appeared, and she died four years and a half after the operation.

Digitized by Google

Case 27 is another in which the *x*-rays seemed to have a decided effect in retarding the growth. It is now my practice to give each patient a course of *x*-ray treatment immediately after the operation, with the idea of destroying any bits of cancer that may have escaped removal. For this the exposure to the *x*-rays are made twice a week for three or four months after operation. The cases treated in this way have occurred within the past three years and are not included in this report, as the time elapsed is too short to judge of results.

Digitized by Google

REPORT ON ONE HUNDRED CASES OF CARCINOMA OF THE BREAST.

By JOHN C. MUNRO, M.D.,
BOSTON.

The bulk of the cases reported here came in the service of my colleague, Dr. J. T. Bottomley, and myself, at the Carney Hospital, between the years 1903 and 1906. On this account the favorable short-limit results are misleading in estimating the true value of operating in cancer. All operations, unless otherwise indicated, were radical in the sense that the breast, both pectorals, and lymphatic tissue below the clavicle were removed en masse as a rule. Rarely has it seemed advisable to dissect out the cervical lymph nodes. All raw surfaces were covered by plastic flaps or allowed to heal by granulation. Practically no case has been refused, the operation being done in a fair proportion of cases to prevent the expected distress and suffering of sloughing tumors. In a third of the cases the type of carcinoma was not specified in the pathological report, and it has been impracticable to determine it with exactness. The macroscopic description would suggest the medullary form in most instances, but, lacking accurate histological data, it has seemed best to leave the cases undetermined in this regard.

Cases of Scirrhous Carcinoma. One case each is well at the end of one, two, and four years.

The result is not known in six cases, but as one of these came to us originally for operation for recurrence, it is probable that she has died. One patient died two years after operation of acute hyperthyroidism without any evidence of recurrence. Another patient (a partial operation) died one year after operation of acute pneumonia. Two had local recurrence one and two years, respectively, after operation.

Digitized by Google

One patient died of acute lobar pneumonia while in the hospital. It is interesting to note that two other deaths from the same disease, and reported in the later sections, came within a few days of each other, suggesting a definite air-borne infection. One patient died within two years of operation, probably from recurrence, as the cervical nodes had been included in the dissection, but the details of her death could not be learned.

Six cases died of recurrence, the locality of which could not be definitely learned from the friends or physicians. Of these, one had three operations in the region of the breast and one intra-abdominal operation, but there is no history that would lead us to infer that the abdominal lesion was associated with that of the breast. The second case had had the opposite breast removed for cancer before she came to us. She died four years after our operation, but the locality of the recurrence could not be learned. The third case, with mediastinal invasion at the time of operation, died presumably of intrathoracic or intra-abdominal infection. The fourth case came to us with local recurrence six months after an operation and died six months later. The fifth and sixth cases died two years after operation, the locality of recurrence being undetermined.

Two patients died within two years of intra-abdominal metastasis, one of these being reported by the pathologist as a rare type of scirrhus.

CASES OF MEDULLARY CARCINOMA. Four cases are well at one year, three at two years, and four at three years. In the first group one patient had cerebral hemiplegia shortly after returning home but as she is recovering, the paralysis is probably not due to cerebral metastasis. Another patient in this group was eighty-four years old, and the muscles were not removed at operation. In one case in the second group the malignant focus was found in the wall of an abscess, with metastasis in the axillary nodes. In the third group one patient was too old and feeble to allow complete extirpation. Another had necrosis of the tumor and malignant metastasis in the axillary nodes. In still another a nodule appeared in the scar at the end of eight months. Under *x*-rays this disappeared and the patient remains well. One patient died after two

Digitized by Google

years from acute pulmonary and cardiac disease; another died suddenly three months after operation without evidence of recurrence. One patient, in whom the pectorals were not removed, is living eleven years after operation. In this case an axillary node was removed at a preliminary operation for diagnosis. Although the muscles were not removed, the axilla was dissected from above downward, together with the fascia of the pectorals, subscapularis, and part of the oblique.

In four cases the results are unknown. One patient had a carcinoma engrafted on a lactating breast and an adenoma of the thyroid, which was removed at the same sitting. After leaving the hospital she could not be traced. One case, where the vessel sheath was infiltrated, had recurrence in the axilla and subscapular region within a year. The vessels were not excised at the first operation. A second case had thoracic symptoms within a year. A third case has recently died three years after operation with symptoms of metastasis in the chest and spine; but our operation was for recurrence five years subsequent to a partial amputation. A fourth case, with symptoms of mediastinal invasion, at the time of operation, has been lost sight of, but is probably dead. A fifth case died in the hospital of acute lobar pneumonia. Three patients died from recurrence, the exact locality of which could not be learned, all within a year. One of them suffered from a greatly swollen arm, and another had only a palliative operation, on account of the extensive involvement.

Cases of Scirrhous-medullary Carcinoma. Two cases in which sections showed both histological types are living one year after operation. A third, for whom partial excision of a large ulcerating tumor was done, died at the end of a few months.

Cases of Adenocarcinoma. One case (cystic type) is alive at one year. A second case, seventy-seven years old, with circumscribed tumors of both breasts, had the breasts, with the fasciæ only, removed. She lived three years, dying of some acute renal lesion, but her physician writes me that just before death she discovered a tender tumor in the abdomen, which presumably was cancer of the liver.

Digitized by Google

CASES OF CYST WITH MEDULLARY CARCINOMA. One patient is well at three years. Another patient came to us with a nodule in the left breast at the end of a scar, following amputation of the right breast, two years previously, for cancer. Four years after complete excision of the left breast there is no recurrence. One case, with malignancy starting at one point in the cyst wall, has remained well for ten years. Another similar case of blood cyst, and without glandular invasion, lived four years, when she died suddenly of apoplexy.

CASES OF CARCINOMA, TYPE UNDETERMINED. We have been unable to trace the specific type of carcinoma in about 30 cases. Two in which the process was not advanced far enough to allow differentiation are well at the end of one year. One patient had incomplete excision of the breast six years before she came to us. At that time we performed the complete operation for a recurrent nodule that had existed for three years. Two years later she returned,with cancer of the remaining breast, without recurrence on the side of the original operation. Since the last operation we have been unable to trace her.

One patient is well at two years, two at four years, one at seven years, and one (a partial operation) at fourteen years. One patient after operation died elsewhere after hysterectomy for cancer of the cervix, without evidence of recurrence of the mammary growth. One died in the hospital of acute lobar pneumonia, and another died four years after operation of acute miliary carcinoma.

Of the remaining 18 cases, 1 with partial operation had recurrence in the neck, midiastinum, and opposite breast; another, with cancer (macroscopically of the medullary type) of one breast, developed sarcoma of the opposite breast and died within a year. The remaining 16 cases with advanced disease, in some of whom only a partial operation was possible, died within two years, generally with intrathoracic or intra-abdominal metastasis. Finally, one patient, whose breast had been previously removed for cancer, came to us with lymphoma of the remaining breast, which required only a partial operation.

Digitized by Google

REPORT OF END RESULTS FOLLOWING OPERATIONS FOR CANCER OF THE BREAST.

By FREDERIC S. DENNIS, M.D.,
NEW YORK.

In 1891 I read a paper before the American Surgical Association and reported 116 cases of cancer of the breast with less than 1 per cent. mortality for the operation, which was due to hemophilia with 5 per cent. of local recurrences and 45 per cent. of permanent cures taking three years' limit of time as the then generally accepted standard.

In 1895 I read another paper before the same Association and reported a smaller series of cases, and in the list there was another fatal case from hemophilia in which all the major joints were filled with blood and the greater part of the body affected with subcutaneous hemorrhages. In this smaller series two cases had not reached three years' limit of time and with no mortality save the one case of hemophilia just mentioned, and 77 per cent. of permanent cures.

These two series of cases show results as to mortality, as to local recurrences, and as to permanent cures as satisfactory as any that have been heretofore published. The percentage of permanent cures, while high in this series, does not represent the truth when viewed later or after three years, as I shall presently show.

In this present contribution I propose to select 50 cases from these two series of cases which were formerly reported permanently cured, according to the three years' standard, and discuss such cases whose subsequent histories are known and follow the end results after many years. These 50 cases have been selected solely upon the ground of personal knowledge to as their present

Digitized by Google

condition, and they are as a rule private and not hospital cases. In all of the cases the histories have been kept for many years and nearly all of the patients have been seen or heard from recently. Now, studying these cases in the light of the subsequent histories, after many years, the aspect of the whole picture changes. In other words the three years' limit is too short a period to predict a permanent cure.

I am convinced that a thorough investigation of a limited number of individual private cases is the only way to arrive at a proper conclusion as to the value of operation in cancer of the breast. This is evident because it is impossible to follow the history of hospital cases many years subsequent to the operation as so many cases in this category must be eliminated from the list as unknown factors. In other words, reliable and absolute knowledge as to a given number of private cases, that can be followed for many years subsequent to the operation, reveals in the only way possible the true status of this important question of permanent cures. In an indiscriminate report of a large series of hospital cases the elimination of so many, from lack of knowledge, renders of necessity the report of little value. It is the study of a number of cases about which there is positive information that enables one to draw conclusions which are of intrinsic value in arriving at the true status of the question involved in this most important discussion. I have selected these 50 cases to study and report the subsequent histories with a view of establishing some opinion as to the value of operation and cure. In the study of the end results, after many years, of these 50 cases selected in order to have the time of the operation date back many years, the final results reveal some facts of great clinical importance. In some respect the subsequent history of these cases is most satisfactory and in other cases the end results are discouraging as to the question of permanent cures.

In this list of 50 cases I have divided the entire number into three groups in order to study them in separate classes after the expiration of many years. I desire to show that surgeons have reported cases as permanently cured, according to an accepted standard established a few years ago, which have not been followed

Digitized by Google

long enough after the three years' limit of time to state positively that they are permanently cured. By studying the cases in separate groups a better understanding can be reached as to the real condition of the patients in each class, and at the same time the grouping of the cases in this way gives general information as to the condition of the sum total of cases and a more intelligent knowledge of what can be expected in the future.

The *first* group comprises cases all of which have been cured beyond the three years' limit of time and a few even twenty-five years, including a few with local recurrences in which secondary operations were performed with no subsequent recurrences.

The *second* group comprises cases which have been cured beyond the three years' limit of time but which have died many years after the operation from causes entirely independent of carcinoma.

The *third* group comprises cases all of which have been cured beyond the three years' limit of time, but which have died many years afterward from metastasis in the internal viscera.

In the first group there were 39 cases reported in the list of 50 cases that carcinoma of the breast has been permanently cured. A few of these cases have lived twenty-five years with no evidence of return, including, however, a few cases with local recurrences in which a subsequent operation has been performed and the patients immune from any further extension of the disease. All of these 39 cases lived from five to twenty-five years and all have been watched from time to time, and nearly all of the 39 cases have either been seen or heard from recently.

This group of cases affords much encouragement as to the possibility of permanent cure. It proves beyond all peradventure that a cure can be established in some cases, which fact can always be a source of hope to those suffering from this much-dreaded disease. It yet remains a mystery as to what constitutes the essential conditions to obtain this result. From the character of the operation performed nearly a quarter of a century ago it follows that the operation itself was not the only factor involved. The morphological condition of the tumor has much to do with the prognosis, for in no other way can the permanent cure in these

Digitized by Google

cases be explained. The peculiar histological type of the carcinoma seems to have an influence on the prognosis. There is much to learn in regard to this phase of the subject and modern scientific investigation will be certain to throw a flood of light upon this dark subject. It is, however, established beyond doubt that the more embryonic the cells are the more malignant the cancer.

The second group comprises cases which have been cured beyond the three years' limit of time, but which have died many years after the operation from causes entirely independent of carcinoma. In this group there were 4 cases out of the 50. These cases for many years after the original operation were in perfect health. They finally died from acute diseases, so that while they may be said to have been cured no one can state, owing to the intervention of death, whether in later years a return might not have occurred if they had lived. All that can be said is that no return did occur for many years, and that death resulted from special causes wholly disconnected with carcinoma.

The *third* group comprises cases all of which have been cured beyond the three years' limit of time, but which have died many years afterward from metastasis in the internal viscera.

There were 7 cases in this group in the 50 cases where the patients lived for many years after the original operation, and who died subsequently from metastasis in the internal organs. The site of the metastasis was not the same in all the cases. In 4 cases the metastasis was in the lung and pleura, in 2 other cases it was in the abdominal cavity, and in another case it was in the pelvic glands and femur.

No better illustration of the uncertainty of permanent cures can be adduced than by a reference to a single case in which for eight years the patient was presumably cured.

In this case I removed a carcinoma and no return occurred in the breast. The patient was over seventy years old and enjoyed immunity from the disease for a period of eight years following the operation, when she began to fail in general health and complained of more or less intestinal disturbance. This condition

Digitized by Google

increased for a year, more or less, when a small growth made its appearance in the right iliac region. She died about six months later or about eighteen months from the beginning of the appearance of the growth. No autopsy was permitted; but it seemed certain that the growth was a metastasis from the breast, though it occurred eight years after the original operation. This was a case where the patient had lived many years after the standard time and finally succumbed to the disease, when, according to our accepted standard, she was supposed to be cured. Even if the time had been extended to five years she was not cured with that standard. This case, as well as others in the list, illustrates the important clinical lesson that we must extend our period of time to feel in a measure more certain of a permanent cure, and that five years is a period where one can be nearly certain, from a study of these cases, that a permanent cure is obtained. So few cases have a return after five years immunity, that this period of time seems a standard which would include nearly all cases of permanent cure.

In this list of 50 cases each had reached the three years' limit of time and were all cured in accordance with the standard. In reviewing, at the present time, these 50 cases reported to have been cured, some interesting facts have been revealed. The result of this thorough investigation has demonstrated the important clinical fact: (1) That cancer of the breast is sometimes permanently cured, or at least that twenty-five years have elapsed with no evidence of a return; (2) that cases may go as long as eighteen years and yet finally have a return in some other organ; (3) that in the cases in which no return has been observed the operation was performed almost without exception within six months from the incipiency of the disease, thus showing the great importance of early operation; (4) that the more radical the operation within reasonable limits the better the prognosis; (5) that in some cases in which the outlook was most unfavorable as manifested by extensive ulceration, hemorrhage, widespread axillary involvement the end results have been entirely satisfactory.

1. Cancer of the breast is sometimes permanently cured, or at least twenty-five years have elapsed with no evidence of a return.

Digitized by Google

The 39 cases which were permanently cured, a very few of which have been followed for a quarter of a century, clearly points to the conclusion that surgeons have obtained a mastery over this disease. This is especially true because cancer appears as a rule late in life and immunity for many years entitles us to claim a cure in these cases. I am convinced further that with certain types of cancer the present radical operation will ensure a larger number of recoveries than have been established in the past.

2. That cases may go as long as eighteen years and yet finally have a return in some distant organ. A brief report of two cases illustrates the clinical fact more forcibly than by any general deduction.

The first patient suffered from a cancer of the breast upon whom I operated eighteen years ago. The tumor was examined by Professor Welch of Johns Hopkins University. After an expiration of eighteen years, during which time she has been free from the disease, she consulted me in reference to a small induration in her other breast. The lump was small and situated near the nipple. In the light of her previous history I felt justified in recommending the immediate removal of this breast to which proposition she, as well as her husband, offered most serious objections. I advised her to consult another surgeon who would give her an independent opinion. This she did and returned with the verdict of—not malignant. I then advised her to consult a third surgeon who advised delay, but with the understanding that she was to come to see him again in a month as he might change his opinion. She returned to me, however, and finally decided to have the operation, which I accordingly did, and Professor Ewing made a microscopic examination, and pronounced it to be a carcinoma. Two years have now elapsed and she is thus far free from any evidences of a return. It is, however, too soon to predict the outcome in the second operation. This case illustrates the fact that even eighteen years may elapse with no return of the disease in the breast, but that after that long period of time a new outbreak or a new carcinoma may appear in the remaining breast. It shows, moreover, that cases reported cured may in years to come develop

Digitized by Google

a new carcinoma not in the site or region of the first operation, but in the remaining breast.

The second patient was operated upon by me for a sarcoma of the breast, fourteen years ago, and during this time she has been free from all indications of this disease. One year ago she consulted me for some trouble in her remaining breast. While I was not positive as to the precise nature of this new trouble, I advised an immediate removal of the breast, taking into consideration her previous clinical history. Professor Ewing states that this second breast is a carcinoma and not a sarcoma, as was the case in the first breast. We are here confronted with a peculiar history. A sarcoma in one breast, and, after fourteen years of supposed permanent cure, a malignant disease of another type altogether develops in the second breast. The question naturally arises in this case: Was not the sarcoma cured and was not the carcinoma in the other breast a purely incidental outbreak of a new disease and wholly independent of the original disease from which she suffered fourteen years ago and from which she appeared to be cured? The more I study these cases the more I am convinced that our knowledge is still incomplete and that much is to be learned as to the behavior of malignant disease in the individual case.

3. That in the cases in which no return has been observed the operation was performed almost without exception within six months from the incipiency of the disease thus showing the great importance of early operation. This point seems to me of great importance in relation to the prognosis. I have examined my cases and find that in nearly all of the permanent cures the operation was performed within six months of the appearance of the disease. Too much importance cannot be placed upon this fact, because it is without question that the earlier the operation the better the prospects of cure. This is true because glandular infection is not so likely to occur and the patient is in better physical health from absence of worry and pain. This fact should impress the family physician with the responsibility of referring his patient early to a surgeon who then must assume the responsibility of this momentous question. No growth, however small, should be dis-

Digitized by Google

regarded, especially if the patient is approaching the menopause. It is with a view to prophylaxis that the mortality of death from cancer of the breast is to be still further reduced.

In regard to the fourth clinical fact, the more radical the operation within reasonable limits the better the prognosis.

It seems unnecessary and a loss of time to discuss this point, since it is universally admitted that the more radical the operation the less likely it is that the disease will return. The difficulty seems to be as to what constitutes a radical operation. All surgeons agree that all skin over the infected area should be sacrificed, the breast with Sir Astley Cooper's ligaments should be entirely removed, together with the pectoral fascia and muscles, the axillary glands dissected out, and also the perimammary and retromammary fat and the paramammary areolar tissue, as the minimum operation. If the cancer involves the ribs and perforates the thoracic wall, and has already infected the mediastinal glands, no operation, however radical, would be attended with any success. The same rule may also apply to that form of cancer termed encuirass or enplaques, or acute miliary carcinosis.

I am firmly convinced that any radical operation more than has been described will be of no avail. The element of time should be seriously considered, since the performance of any operation which requires the patient to be under an anesthetic for four or five hours is attended with a risk which should, if possible, be obviated. These prolonged operations are sometimes followed by ether pneumonia, acute sepsis, profound shock, suppression of urine, and many other like conditions which jeopardize the life of the patient. In other words, we must not lose sight of some of the general principles connected with surgery at the expense of the elaboration of an operation, the performance of which eliminates some of the best precepts and practice of our art.

5. That in some cases in which the outlook was most unfavorable, as manifested by extensive ulceration, hemorrhage, widespread axillary involvement, the end results have been entirely satisfactory. No better proof of this statement can be made than by a brief reference to 2 cases occurring in the list of 50 cases. It

Digitized by Google

seems pertinent to call attention to these two cases because they demonstrate the possibility of a cure when everything looks hopeless. I admit we cannot place any reliance upon a cure when cases present such a chain of unfavorable symptoms. It only shows that surgeons should not withhold an operation from the patient even when the outlook is most discouraging. If there is a possible chance in any case the patient should have the benefit of the doubt. It is always best, however, to explain to the friends the true situation and then they will not be disappointed if the operation is attended with a quickly fatal result.

The first patient had a foul, ulcerating hemorrhagic and fungous breast with axillary enlargement. I advised the operation, not with the expectation of curing the disease, but purely from a humanitarian point of view. I felt sure that the hemorrhages could be in a large measure controlled, the offensive smell to a greater or less extent be removed, the constant pain at least for a while relieved, and with a view to euthanasia the patient might be made more comfortable while she lived. To my surprise, after eight years, she has been free from disease, and to all intents and purposes is at the present time in perfect health. The operation was radical and I am at a loss to explain the cure under these conditions.

The second patient was the victim of a fungous, hemorrhagic, foul-smelling carcinoma of the breast. I hesitated to operate at all but did so at the request of the husband, with a full understanding that the operation was one to palliate the distressing symptoms and with no expectation of cure. This operation was performed four years ago, and today, to my astonishment, she is perfectly well and has no evidences of any return of the disease. Both of these tumors were examined by microscopists of world-wide reputation, who pronounced them carcinoma. I merely mention these 2 cases in the list of 50 to illustrate the fact that sometimes the most hopeless cases recover, and they appear to me to urge the surgeon to operate in the most desperate cases with the most forlorn prognosis, provided the tumor is not adherent to the chest wall. I can offer no explanation as to the behavior of these two

Digitized by Google

tumors, but they seem to me worthy of record as evidence that our knowledge is still incomplete in regard to the course of certain types of cancer of the breast.

Finally, from a review and study of these 50 cases it follows that surgery has made distinct advances in the cure of this most dreaded disease. It also follows that much is to be learned in regard to the accomplishment of a more uniform percentage of recoveries. It is also obvious that surgery must direct its attention to a study of the factors which influence the results of operative treatment. It is likewise evident that a more unanimity of opinion must be arrived at by surgical pathologists whose work in the histological formation of cancer is yet far from satisfactory, as one pathologist denominates a certain tumor cancerous while another calls it by some other name. This leads to confusion and destroys the value of the results of operative treatment. The question of metastasis, too, demands more careful research, as it is yet far from clear as to where the metastasis is likely to occur in the individual case. The tendency of certain benign breast tumors is not yet understood. The period of time as to what constitutes a permanent cure following an operation is not agreed upon by all surgeons. The radical character of the operation is admitted by all as the one essential factor in the operative treatment. This widespread discussion before this Association today should have an influence for good on behalf of those suffering from cancer of the breast, and in years to come operative treatment in this department of surgery should give satisfactory and brilliant results.

Digitized by Google

END RESULTS FOLLOWING OPERATIONS FOR CARCINOMA OF THE BREAST.

By WILLY MEYER, M.D.,
NEW YORK.

It had been my endeavor to bring a collective report of the final results of operations for carcinoma of the breast, done by the various operators at the German Hospital, of New York City. But this proved impossible, for, with the ever-shifting population of this cosmopolitan centre, attempts at tracing cases to end results usually bring but unsatisfactory returns, and often are connected with unsurmountable difficulties. It took me more than six months of hard work in 1904 to prepare my statistics. I am, therefore, today in a position to present only my personal statistics of cases operated upon by the method first described by me in 1894 (*New York Medical Record*, December 15, 1894), and again more fully in 1905 ("Carcinoma of the Breast; Ten Years' Experience with my Method of Radical Operation," *Journal of the American Medical Association*, July 29, 1905). In order to be able to pass an opinion on final results, obtained with one and the same operative procedure, all cases of carcinoma of the breast, operated on prior to 1894, were not included in the following statistics.

From September, 1894, to April 1, 1907, I have performed the radical operation 86 times in 84 patients, 2 having developed the same disease in the opposite breast not long after the first operation. Of these, 83 were females; 1 male. The youngest case was twenty-eight years of age, the eldest seventy-two; the man was forty-four years old.

Classified into decades, the ages of my patients range as follows: One was between twenty and thirty years of age; 14 were between thirty and forty; 38 were between forty and fifty; 18 were between fifty and sixty; 11 were between sixty and seventy; 2

Digitized by Google

were between seventy and eighty: total, 84, showing the greatest number of cases to have occurred in the fifth decade.

Fifty-three cases were private patients; 31 were operated upon in the wards of the German and Post-Graduate Hospitals. Of the former I have careful records as to their subsequent history; of the latter, 4 could not be traced. One of these, operated upon in June, 1903, at the age of forty-three, was alive and well in January, 1905, but since then has been lost track of.

Again, I am greatly indebted to Dr. Martin Rehling, of New York, who rendered such invaluable assistance in compiling my statistics two years ago, for his efforts in personally ascertaining the present condition of the surviving ward patients.

Deducting the 4 patients who could not be traced, there remain 80 for consideration here.

Sixteen of these were operated upon from ten to twelve and one-half years ago, *i. e.*, between September, 1894, and April, 1897, and of this number 1 died of diabetic coma forty-eight hours after operation; 8 died of recurrence or metastasis from one to three years after operation; 2 lived nearly four years, when they died of internal metastasis; 1 was well for eight years, when she developed regional recurrence; 1 was well and free from recurrence six and three-quarter years, when she died of endocarditis; hence 3 (18.7 per cent. of this series) are alive and well today, from eleven to twelve and one-half years after operation, namely, twelve and one-half, twelve and one-twelfth, and eleven and one-twelfth years, respectively, a total of 16.

Twenty-seven patients were operated upon from five to ten years ago, *i. e.*, between April, 1897, and April, 1902. Of these 17 died of recurrence or metastasis from one to three years after operation; 2 died of recurrence nearly five years after operation; 1 (seventy-two years old) lived in perfect health for six years after operation, when she developed a rapidly-growing cancer of the stomach, in the absence of any local or regional recurrence; 1, a pronounced diabetic at the time of the operation, was well for six years, when she succumbed to diabetes without having developed any signs of a return of the old disease; 6 (22.2 per cent.) are alive

Digitized by Google

and well today, from five and three-quarters to nine and one-half years after operation, viz., nine and one-half, eight, seven and three-quarters, seven, six and one-half, and five and three-quarter years, respectively, a total of 21.

One of these latter was operated upon by me for carcinoma of the right breast in March, 1899. In December, 1900, she returned to me with a carcinoma of the left breast, which I then also extirpated. She has been well and free from recurrence since, six and one-quarter years after the second operation.

From the above it appears that of 43 patients operated upon between September, 1894, and April, 1902, 17 (equal to 39.5 per cent.) have remained free from recurrence from three to twelve and one-half years after operation; or 13 (equal to 30 per cent.) from five to twelve and one-half years after operation; 9 (equal to 20.9 per cent.) being alive and well today.

Twenty patients were operated upon from three to five years ago, *i. e.*, between April, 1902, and April, 1904. Of these 8 died of recurrence or internal metastasis from one to three years after operation; 1 died three and one-quarter years after the same; 1, twenty-eight years of age, the youngest of all my patients, had a regional recurrence two and one-half years after operation, for which she was operated upon and remains in statu quo under continued *x*-ray treatment; 10 (equal to 50 per cent) are alive and well today, from three to four and three-quarter years after operation, *i. e.*, four and three-quarter years (1 patient), four and one-half years (3 patients), four years (1 patient), three and three-quarter years (1 patient), three and one-quarter years (3 patients), and three years (1 patient), respectively, a total of 20.

This latter series includes the only male patient I have had, who is well now, three and three-quarters years after operation.

Seventeen patients were operated upon during the last three years, *i. e.*, from April, 1904, to April, 1907; 1, a ward patient, died two weeks after operation of secondary infection, after the principal part of the wound had healed up by primary union, all grafts having taken, the first dressing having been changed on the sixth day as usual; 5 died of regional recurrence from one to two

Digitized by Google

and three-quarter years after the ablation of the breast; 1, sixty-seven years old, has developed a local recurrence seventeen months after operation (tumor of the right rib beneath the grafted area); 1, forty years old, an advanced case, showed a recurrent nodule surrounding one of the subscapular nerves, eleven months after the operation—immediate extirpation, regional recurrence (multiple) three months later; 9 are alive and well today: total, 17. Of these latter, 1 was operated upon two and three-quarter years ago; 7 between April, 1905, and April, 1906; the remaining 1 within the last year. Thus, of the entire 80 patients, 28 (equal to 35 per cent.) are alive and well today, 9 of these having been operated upon less than three years ago; 4 (equal to 5 per cent.) lived from six to eight years after operation; 1 of these died of a regional recurrence, 1 of metastasis, 2 of diseases not in any way connected with the original trouble; 28 (equal to 44.4 per cent.) lived from three to twelve and one-half years after operation; 5 (equal to 6.25 per cent.) lived from three to five years after operation; 3 others (equal to 3.75 per cent.), though living, have developed either local, regional, or metastatic recurrent growths; 40 (equal to 50 per cent.) have died within three years after operation; 2 of these died shortly after the operation—1 on the second day, of diabetic coma; the other, after two weeks, of secondary infection; 16 within twelve months (equal to 20 per cent.), and 8 within twelve to eighteen months (equal to 10 per cent.); or 24 (equal to 30 per cent.) within one and one-half years after operation.

Reviewing my statistics, I will here refer to a few points in addition to those discussed in my previous paper:

In 8 of the 40 cases that have died within three years after the operation there was neither local nor regional recurrence, death being due to internal metastasis (spinal column, stomach and intestines, mediastinum and brain). It is plausible to assume, I think, that in many of these cases the infection of the respective organs had existed prior to the operation.

With regard to the desirability of cleaning out the supraclavicular space at the time of operation, even in the absence of clinical evidence of the presence of cancerous glands in this region, I can but

Digitized by Google

say that my own experience does not speak in favor of such a procedure. In none of my 13 patients who remained well from five to twelve and one-half years were the supraclavicular glands removed.

The question as to whether the subscapular nerves should be preserved at all hazards, as strongly advocated by Küster twenty years ago,[1] still remains sub judice. Personally, I always try to preserve them. I would say, however, that in three cases I have seen the first regional recurrent nodule embracing, as it were, the second subscapular nerve which ran through its centre. In all three of these cases the disease spread in spite of most thorough excision of this nodule. Of course, to sacrifice one or more of the subscapular nerves in all cases would entail great hardship for the patient, in view of the resulting disability as regards the proper use of the arm.

In three cases the axillary vein was removed, together with the mass, from a point just below the entrance of the cephalic to a place corresponding to about the beginning of the bicipital sulcus. This procedure wonderfully facilitated the otherwise particularly difficult preparation. No disturbing sequelæ were observed. Of course, great care was taken not to interfere with the cephalic vein or with the proximal part of the axillary beyond the entrance of the former.

Edema of the arm has been a rare observation in my cases. I have noted it in a transitory shape in about 10 per cent. The cicatrix has oftener been the causative factor than glands, compressing the subclavian or axillary vein. In only one of my patients did it persist to some extent. This one was operated upon four and one-half years ago.

The postoperative neuralgia, or neuritis, of the brachial plexus has proved to be temporary in every instance. Of the prevention of these sequelæ, by means of Murphy's muscle plastic, I am not in a position to speak, owing to lack of personal experience so far.

I think it worthy of special mention that every one of my patients has full use of the arm.

That the extent of involvement is an important factor regarding

[1] Zentralbl. f. Chirurgie, March 12, 1887.

Digitized by Google

the prognosis of the case, stands to reason. If the disease has reached an advanced stage, especially when there is involvement of the supraclavicular lymphatic glands, there is little hope for a longer freedom from recurrence. Every one of such patients, operated upon by me, died soon after. Eight of these cases are valuable for conclusions. In two of these, glands were primarily removed with the other tumor; in five, secondarily, in the absence of either local or regional recurrence. None of these lived longer than nine months. The eighth patient, in whom another surgeon had done a rather conservative operation two and one-half years before she came to me with local recurrence, and upon whom I then performed my radical operation plus cleaning out of the supraclavicular space, lived twenty-one months.[1]

In spite of the sad prognosis of these cases, I nevertheless think the removal of the glands, if enlarged, should be undertaken in every instance, for I consider it the surgeon's duty to extirpate whatever can be reached with the knife, so long as metastases do not forbid such a procedure. Sometimes life may be prolonged more than seems possible at first sight, as the case just cited well illustrates. This patient lived for one and three-quarter years in the full enjoyment of life; then a tumor in the mediastinum caused death—local and regional recurrence as well having taken place.

It will be interesting to scan the cases with regard to the seat of the primary breast tumor. If the growth is found in the upper two quadrants of the breast, particularly if it involves the skin and the subcutaneous tissue over this region, infection of the supraclavicular glands may be expected (Poirier, Cunéo, and Delamere, *The Lymphatics*, p. 215). This was found true in the great majority of my cases.

Regarding a possible difference in end results between scirrhus or adenocarcinoma of the breast, I can offer no definite conclusions, as the reports with reference to the pathological variety of the growths are not complete in all my cases. However, judging

[1] In this case, as became evident from the symptoms that appeared on the third day after operation, the thoracic duct was injured beneath the clavicle. It closed spontaneously in course of healing.

Digitized by Google

from the cases that can be utilized for this question, the prognosis of adenocarcinoma seems less favorable than that of the scirrhous type.

I consider the *x*-rays valuable in the immediate after-treatment. Every patient is urged to submit to a six to eight weeks' course as soon as healing has been accomplished. I have one case which, at the time of operation, gave a bad prognosis. Here the faithful intermittent use of the *x*-rays, during a number of years, had a most gratifying result. No recurrence for four years.

The duration of the disease prior to operation naturally plays an important role with regard to end results. Let me say here that in no case did I refuse the radical operation, except metastasis forbade it. Of course, the earlier it is done the better for the patient. Still, I believe the degree of malignancy of the disease and its tendency to rapid proliferation often to be the more important factors in determining the patient's fate. I have a number of cases, especially among my younger patients, in whom I operated at what I consider an early stage, and yet they developed internal metastases (brain, spinal column, etc.) with astonishing rapidity, in spite of the same complete operation. But, knowing the treacherous, perhaps even directly infectious, nature of malignant disease, we should, even in the face of such sad experience, not allow ourselves to encroach on the magnitude of the operation. Since a refined diagnosis as to the virulency of the disease in the given case is impossible, radical work is a necessity in every instance, and best, it seems to me, such radical work as does not spare skin,[1] divides the lymphatics first and then keeps outside of the infected area as much as possible, the cuts being made within healthy tissues as far as this can be done. In other words, the operation should consist in removing both pectoral muscles with the diseased breast, glands, and surrounding fat in one mass.

Even doubtful cases will fare better by such a procedure than by an operation of less magnitude or undue temporizing.

[1] Often have I seen local recurrence in the skin closely bordering the grafted area. It is my opinion that sometimes we are induced to save skin in order to be enabled to close the defect without grafting. This is the reason why I would not make up my mind, so far, to adopt Jackson's excellent skinplasty (Jour. Amer. Med. Assoc., March, 1906).

Digitized by Google

END RESULTS FOLLOWING OPERATIONS FOR CARCINOMA OF THE BREAST.

By LEWIS STEPHEN PILCHER, M.D.,
NEW YORK.

In the present communication I wish to emphasize more especially results obtained in cases in which, at the time of operation upon the breast, the lymph nodes above the clavicle were already infected, and the supraclavicular spaces were cleared out in addition to the typical operation upon the thorax and axilla. I do this especially because of the frequency with which I have met expressions of skepticism from men of large clinical experience, as to the value of extending operative attack above the clavicle; their skepticism being based upon their apprehension of the great probability that when the supraclavicular nodes were appreciably affected, the infection had already extended into the mediastinum, so that even after the removal of the supraclavicular masses the operation would necessarily still be incomplete.

No one for a moment would dispute the increase of gravity of prognosis in a case of breast carcinoma in which the transmitted infection had reached the supraclavicular lymph nodes, but that this should always render the prognosis practically hopeless is not in accordance with clinical experience. When, therefore, my colleagues say to me that they never invade the supraclavicular region in their work for breast carcinoma, I am influenced to inquire whether they are not thereby permitting a certain proportion of cases to proceed to a continuance of carcinomatous development which a further extension of their work of eradication might have prevented.

In a study of my results in operations for breast carcinoma,

Digitized by Google

published in 1900, I found that in 10 of the cases in which enlarged supraclavicular nodes were discovered and removed, 3 remained free from recurrence. These I have been able to follow to the present time, May, 1907; 1 case has since died from cardiac failure at the age of seventy-five, more than seven years after operation, without recurrence of cancer; the 2 others are still living, free from recurrence, nine and seven years, respectively, having elapsed.

During the six years, 1901 to 1906, inclusive, 34 additional cases of breast carcinoma have come to operation at my hands; 5 of these were manifestly and unavoidably incomplete operations, the benefit was but partial and temporary and the steady advance of the disease was uninterrupted; 1 of these died on the table.

In 11 instances, application for relief had so promptly followed the discovery of the presence of the disease that in my judgment it was proper to limit the operative attack to the clearing out of the axilla and the removal of the pectoral muscles with the affected breast and its overlying skin. The results in these cases have been so extraordinarily good that I almost hesitate to record them, for they entirely reverse all my previous experience and preconceived opinion; 9 out of the 11 have thus far remained free from recurrence, periods of four years, three and one-half years, two years, eighteen months, in 5 instances, and six months, respectively, having elapsed. In the remaining 2 it is reported that there is now a lump in the other breast, the nature of which has not been determined. My reference to these cases is simply en passant.

It is the remaining group of cases, 18 in number, in which the evident extension of the disease at the time they first presented themselves was great enough to awaken apprehension of possible infection of the lymph nodes above the clavicle that I wish to dwell upon more particularly. In these cases, in 4 instances glandular masses in the neck were distinctly palpable before any section of the overlying coverings was made. Of the 14 cases in which the examining finger could not appreciate the presence of diseased nodes in the neck, the section revealed, nevertheless, that in 11,

Digitized by Google

infected nodes were present, and that in only 3 of the number, appreciable disease was not recognizable upon section.

As to the end results in these cases:

Of the 3 cases in which the neck was opened and the supraclavicular region cleaned out without the discovery of any noticeably infected glands in the neck, all have remained well to date, at periods of five years, one and one-half years, and one year, respectively.

Of the 4 cases in which the supraclavicular glands were palpable ante operationem, 1 case died three months after operation without further external manifestation of disease, but by progressive asthenia doubtless due to internal carcinosis, the operation evidently having been an incomplete one.

The second case one year later had developed multiple recurrent nodules in the thoracic region; these were kept under control by *x*-ray treatment for two years. At the end of four years she had developed a growth in the remaining breast, and was subjected to a complete operation for its removal; later, she developed intrathoracic metastases from which she died five years after the primary operation.

In the third case, a suspicious nodule developed upon the thorax within the first year after operation; this disappeared under the influence of the *x*-ray, and the patient thereafter remained in good health for two years, at the end of which time she died, as reported, from pneumonia. The case is not altogether free from the suspicion of a carcinomatous element in the pulmonary condition.

The fourth case remains well without suggestion of recurrence, two years after operation.

The 11 remaining cases in which the neck was opened and infected glands found to be present although they were not palpable until after the neck was opened, likewise, though in a less degree than those first mentioned, belong to the group of neglected cases which experience has shown may be expected to differ greatly in the operative results obtained from the early attended cases.

Among these 11 women the length of time that had been

Digitized by Google

allowed to elapse after the presence of the growth was known before accepting operation for removal, was two years in 1 case, between one and two years in 4 cases, six months in 4 cases, and one month in 2 cases only. It has been possible to follow the later history of all but 1. One died from myocarditis seven weeks after the operation, leaving 9 cases to be accounted for; of these, 3 developed speedily both regional and distant metastases, the removal plainly having been incomplete, and they all died within the year; a fourth was reoperated at the end of a year for a recurrent nodule in the lateral thoracic region, and no further external metastases became manifest in this case, but carcinoma of the liver developed, resulting in death three years after the primary operation; a fifth case remained well for four years, but during the fifth year—the present year—there have developed both supraclavicular and thoracic recurrences; she is still living. Four cases still remain free from recurrence at periods of three years, three years, two years, and one year, respectively, since operation.

In two previous papers, in 1902 and 1905, respectively, I have dwelt upon the importance of opening the base of the neck as a part of the routine operative procedures in cases of breast carcinoma. Even the limited experience contained in the comparatively small number of cases included in my own statistics is sufficient to indicate that in a considerable proportion of cases the supraclavicular nodes become early infected, so that operations for the removal of carcinoma originating in the breast must often be incomplete if the base of the neck be not cleared of its nodes, as well as the axilla. The point of suspicion—the key to the whole situation, in many cases—is the triangle at the junction of the subclavian and internal jugular veins, where rest the node or nodes which are the sentinels that guard the entrance to the mediastinal lymphatic paths and to which run not only the lymphatics which pass up under the clavicle from the axilla, but also an inconstant but not infrequent set of ducts which run up on the front of the thorax from the mammary region to the base of the neck, down into which they dip after running over the inner end of the clavicle.

When the neck is opened this jugulosubclavian triangle is

Digitized by Google

first to be exposed, explored, and cleaned, and from it, outward, the lymphatic-bearing tissue can be best systematically dissected out en bloc.

So dense is the deep fascia at the base of the neck that, together with the overlying adipose tissue and skin, it forms a covering which renders infected nodes difficult to detect by palpation until they have attained quite a size. When such nodes have become distinctly palpable or visible the presumption is that the infection is of long standing and of considerable extent. They are of ominous portent and fully justify the gravest prognosis. That even then the infection may still be confined to the accessible supraclavicular group, so that their extirpation may ensure a complete removal of all carcinoma-bearing tissue, has been demonstrated in enough instances to encourage surgical attempts in all but the plainly hopeless cases. Of more importance, however, is the practical recognition of the probability of the presence of infection of the supraclavicular nodes in every case of breast carcinoma of much duration or extent, and the incorporation into the general plan of operative attack, in all such cases, of an incision into the base of the neck and a systematic removal of all possibly infected tissue, even though there may be no distinct evidence to sight or touch before such incision, of the presence of such infection.

Digitized by Google

END RESULTS IN OPERATION FOR CARCINOMA OF THE BREAST.

By ALBERT VANDER VEER, M.D.,
ALBANY, NEW YORK.

When I began the preparation of my paper, of which I present only an abstract today, it was my intention to include the histories of cases occurring in my practice during the past twenty-five years, but at this date I find it quite difficult to get so complete a list of end results as I could wish; therefore, it has seemed better for me to continue this line of investigation for a longer period and to give only a few of the conclusions regarding my impressions of the operation for carcinoma of the breast, as I have observed it since moving into our new hospital, from May 1, 1899, to May 1, 1906.

In this period there were 103 cases from which to draw conclusions regarding end results.

As to the relative proportion, in the different decades, they presented as follows:

	Cases.
From twenty to thirty years of age	1
From thirty to forty years of age	15
From forty to fifty years of age	35
From fifty to sixty years of age	32
From sixty to seventy years of age	16
From seventy to eighty years of age	4
Total	103

Family history negative in	53
Family history tuberculous	25
Family history carcinomatous	18
Family history carcinomatous and tuberculous	5
Family history not stated	2
Total	103

Digitized by Google

	Cases.
Left side	60
Right side	41
Both sides	2
Total	103
Deaths	17
Known to be living	70
Not heard from	16
Total	103

Later I hope to give statistics of all of my work in this field of surgery, and in such a manner that more careful and intelligent conclusions, regarding end results, may be reached. Time will not permit of my speaking of any great number of cases referred to in the remarks which this abstract brings out. I may be permitted to observe, in reference to the operation for carcinoma of the breast, as I think of it when I began practice over forty years ago, and now, that it is but another illustration of the impressive manner in which surgery has advanced. The operation has become more and more scientific, more and more thorough, as our knowledge of pathology has increased, and especially would I emphasize the comfort we have at the present time in hospital work in being associated with a laboratory where competent examination of specimens, and original research and investigations can be made.

Forty years ago, and for many years after, there were few surgeons who entered the axillary region and did a complete removal of its contents.

There were too many surgeons who comforted themselves with the belief that this axillary involvement was simply inflammatory, and when once the diseased breast was removed these conditions would improve and disappear. I may be pardoned for referring to this feature of the subject under discussion, for I have watched with so much interest the gradual advances until, at last, we have so thorough a removal as that which many of us do, and in many cases, just emphasized and referred to in so scientific a manner by Dr. Halstead. While it will be noted that in cases of apparently non-involvement of the axillary glands, based upon careful obser-

Digitized by Google

vation, palpation, etc., yet for years, at the time of the operation, it has been my rule, in keeping with my method of operating, to empty the axilla of its lymphatics and contents. Step by step has it been my privilege to increase the thoroughness of the operation, so that I am sure if I were to classify my cases in periods of a half decade each, it would show a marked improvement in the end results and permanent recoveries.

Regarding the diagnosis I should like to emphasize most earnestly the importance and wisdom of our impressing upon the profession at large more thorough work in this direction; that they must not yield to the wishes of the patient that she may not know of any serious trouble that presents, nor comfort her with the thought that there is but a simple mastitis to deal with, but that they must call in consultation the surgeon in whom they have confidence, and then together, the physician and surgeon, they can study the case, employing such excellent methods as have been suggested by Dr. Warren and others, and thus reach as nearly a positive diagnosis as possible. If the case be non-malignant in character let the patient have the benefit of the exhilarating effect by lifting her out of the atmosphere of fear of cancer, which she may have entertained, into the buoyancy of thought that tells her she has had a careful, thorough examination and can believe the statements made to her as the result of the consultation. If, however, the consensus of opinion is in the direction of malignancy, then she should know it, or, a least, her friends, and I wish to emphasize here, as my own experience, and as that of many candid surgeons and careful pathologists, that when once this diagnosis has been made, or there is a suspicion of malignancy, the earlier the operation is done, and the more thorough and complete it is the better for our patient, and for our statistics, as to complete relief. To know that her tumor has been thoroughly removed, to realize that she has made a good recovery, and to be assured that the chances are altogether in her favor, is a prognosis of no mean importance to any patient, whether intelligent or ever so ignorant. It is something she can forget when there is only a painless scar to be observed, which disappears gradually; but to

Digitized by Google

have present a tumor that is ever in her mind is a depressing factor that cannot be overlooked. If there is anything in suggestion upon the nervous system, in these cases, there is no one thing in which it is possible to do so much good as to impress upon the patient that she is well, and that she is to forget her past fears. All her surroundings are to be made such as will eliminate the fear of a recurrence and return to her former atmosphere of despondency.

I have thought much as to the incision, when once the operation is determined upon, and it seems to me that the one which begins well up in the axilla, almost on an oblique line to a point below the nipple, thence along the under surface of the breast to the median line, with a corresponding elliptical incision above, which traverses the upper segment of the breast area, joining with the incision just underneath the outer edge of the pectoralis major, enables me to reach the breast and the lymphatic spaces quite satisfactorily, even to the removal of the pectoral muscles. This is an incision that affords good drainage, and will not be greatly observed by the patient when all is well and recovery has taken place. I am full of faith in the belief that plastic work for covering the area from which we have removed a large amount of diseased tissue, is thoroughly serviceable and I am impressed with the small percentage of return in the scar, in the fatal cases metastases to internal organs being the principal factor causing death.

The benefit of careful laboratory examination, as to the correctness of diagnosis, in the table this paper presents, is instructive, comforting, and tends decidedly to the endorsement of the value that can be placed upon the work of our pathologist.

I quote the following:

CASE I.—Mrs. E. S., aged forty-six years.

Operation, May 28, 1902. Fourteen years ago noticed a bunch in left breast, at the time she was nursing a child. This remained stationary until three months ago, when it enlarged rapidly and was very painful. Growth at first had the appearance of a carcinomatous tumor, and an incision to aid diagnosis was made. The pathologist, from the macroscopic appearance, and hurried

Digitized by Google

examination made at the time, was in doubt. Thorough removal was done, and the pathological report from the laboratory later classed the tumor as an adenoma with lymphangitis.

It seems to me that there is no greater field for the philanthropist than the endowment of pathologial laboratories for just such work as this. I am satisfied that there are degrees of malignancy and that there are associations of one form of malignancy with another that can only be worked out in this manner.

The end results in the 103 cases spoken of in this table bring out a few points of interest.

Of the hopeless or unfavorable cases, where only a temporary relief can be afforded, I am satisfied that many are benefited by an operation, it being well understood at the time, by the patient and her friends, that it is only to relieve her from suffering, and from the distress to which her associates may be subjected in coming in contact with an ulcer that is likely to be so exceedingly offensive and difficult to keep in an antiseptic condition. My experience impresses me with the belief that although such operations bring little, if any, credit to the surgeon, they do relieve the patient of much physical and mental distress.

I can say very little permanent good has resulted from the use of the *x*-rays, except the relief from pain it affords. I can endorse the comfort patients have received from this line of treatment, and must say that I have seen cases in which life seemed to have been prolonged; but then there is always the element of chronic carcinoma to be considered when we say that this or that patient's life has been lengthened by such treatment.

When I consider the treatment of tumors of the breast today, especially carcinomata, as compared with that of forty-five years ago, I must endorse the emphatic language in which the layman expresses himself, *i. e.*, "What wonderful progress surgery has made," yet, at the same time, how far short we have come of that success so much desired, and how selfish for us to appropriate such an expression when we carefully review the great progress that has been made in medicine, in the knowledge of cholera, typhoid fever, and other diseases.

Digitized by Google

I fancy that if such men as Parker, March, the elder Gross, the senior Warren, and others could look in upon an operating-room today when an operation was being done for removal of carcinoma of the breast, there would be a look of interest and of surprise not unlike that to be noted in their expression could they see the advances made in abdominal surgery at the present time.

Referring to the methods of operation and period of time after the discovery of the tumor, I would say that in the cases that are reached early I am not yet convinced that the very radical operation of removal of the pectoral muscles is called for, but cannot be too emphatic in impressing upon the younger men the necessity of careful examination and dissection of the axillary spaces.

In this report will be noted a few cases where tumor was noted early in the breast, which did not worry the patient, yet later developed carcinoma.

CASE II.—I believe this was the case with Mrs. H. B., aged forty-three years, and who gave a negative family history, aside from maternal aunts who had died from tuberculosis. Patient always well in every respect, with the exception of psoriasis since twelve years of age. Twenty-three years ago, first noticed small, hard tumor in right breast above nipple. No known traumatism. Size increased slowly up to two years ago; some pain, but never severe. Tumor, size of a hen's egg two years ago, then increased rapidly and painful. Six months later began to have pain under arm, and noticed small lump there. Patient in good physical condition. Examination at hospital showed large, hard mass in upper half of right breast, one large, and several small nodes in axilla, and in left axilla is one large indurated gland. Operation February 26, 1901. Amputation right breast, removal of axillary glands with pectoralis major and minor muscles, and left axillary space thoroughly dissected out. Patient left hospital in good condition and has remained well.

These cases are most suggestive. They are the ones in which we cannot but feel that had the original simple adenoma been looked after in a judicious manner the patient might later have escaped the carcinomatous element.

Digitized by Google

It is remarkable how unconcerned some patients are in reference to growths about the mammary gland, while others, with the very slightest evidence of some disturbance, become greatly alarmed, their nervous system receiving a shock that is sad to observe and detrimental to them when the operating-room atmosphere is reached. The latter class of patients are often unwilling, even amidst their fears, to have surgical intervention; yet they are, of all cases, the most in need and a class we should endeavor to reach early.

The condition of the no-worry patient is in great contrast to the nervous anxiety of the one who is frightened over the thought that she is to suffer from cancer of the breast at some time, and the years in which this period of worry may be unnecessary, yet where ultimately a tumor does present.

CASE III.—Mrs. E. M., aged fifty-seven years. In its end results this case has been a most instructive one. In the total series of cases I began to elaborate, I was greatly impressed with what I had sometimes been led to call the pre-cancerous state, from the nervous condition of the patient. Mrs. M., for nearly a year previous to the discovery of the tumor, came to my office not infrequently, and while not suffering from direct, characteristic, lancinating pain, or anything clinically that would demonstrate a growth presenting, yet was possessed of the fear that she was to have "a cancer of the breast."

She gave a good family history and was otherwise apparently well. She would, at times, locate an unpleasant feeling in the right side, and in order to relieve her from too many self-examinations I advised her to wear a diachylon plaster quite continuously, but she did not forget her condition. In November, 1901, she discovered a small lump in the right breast. I advised a thorough operation, which was done December 14, 1901, and specimen removed proved to be one of scirrhus carcinoma, with metastases to axillary glands, although the latter could scarcely be felt, on palpation, previous to the operation. The wound healed kindly and remained in good condition, but the patient was not relieved of her nervous strain. She was frightened and in constant fear. About May 1, 1902, she was sure that a tumor was developing in her left breast,

Digitized by Google

and May 14, to my own distress, I could distinctly map out a small growth. The patient's mental condition was truly pitiable, but with a resignation that was heroic she submitted to a second operation, May 25. In this second operation the pectoral muscles were removed, also the axillary glands thoroughly, however, the microscope alone could detect any invasion of them. From this operation she recovered, but later had pains and some enlargement of the cervical glands, and submitted for some time to *x*-ray treatment, getting relief from the pain, and at one time felt very much encouraged. There were no ulcerative growths in the scar tissue. She seemed fairly resigned to the fate that was inevitable, and while there were no metastases to the internal organs, or, apparently to the lung, yet this patient was taken suddenly ill and died, in a comatose condition, January 13, 1904, from all the evidence of carcinoma of the brain or membranes.

I would call special attention to the return of the disease, in some instances later after the first operation. This series of cases gives some interesting facts as to the time of recurrence.

CASE IV.—Mrs. S. A. W., aged fifty-six years, upon whom I operated for removal of the right breast and axillary glands in 1887, remained absolutely well until July, 1899, when she noticed a small tumor in the scar, which gradually increased in size and became painful. She presented for operation January 17, 1900, when I did a second operation, and patient has since remained well.

CASE V.—This is an inoperable case. Mrs. J. M., aged fifty-six years, upon whom I had operated seven years previously for carcinoma of the right breast, returned July 3, 1899 for treatment. Patient had remained well up to within a short time when the growth appeared, now presenting large nodules involving the axillary region to a marked degree, and cachexia very pronounced. Case not in a safe condition for further operative intervention. Axillary region contained a large, gangrenous, sloughing ulcer.

The shortest period of recurrence is as follows:

CASE VI.—Mrs. L. C., aged fifty years, gave the history of observing a tumor in right breast for two years, then applied for treatment, and operation done March, 1901. She was well for

Digitized by Google

about three months when secondary growths appeared in scar tissue. First growth not at all painful; second gave great pain. Second operation done May 1, 1901, for removal of the growths in the axilla and surrounding tissue. Very thorough removal done at this time. Patient at this operation was very much emaciated and had a growth in the axilla about half the size of a hen's egg. She made a good recovery from this last operation, and when last heard from was in good health. Laboratory report as follows: Recurrent carcinoma of mammary region.

CASE VII.—Mrs. A. E. H., aged fifty-one years. Amputation of right breast August, 1903. Growth returned March, 1904. I did a second operation May, 1904, removing all scar tissue, together with subclavicular and axillary glands. Patient made a good recovery, and so far as I am able to state has remained well since.

Regarding the element of pain it is not always so pronounced or marked until the tumor takes on an active stage of increase.

CASE VIII.—Mrs. E. H., aged sixty-five years. History of cancer on paternal side. Patient always well. Menopause two years ago. Five years ago noticed small, movable bunch in upper portion of left breast. No pain or soreness except a little toward axilla. Increase very gradual until past six months, since which time growth has changed position to around the nipple, which is retracted.

Operation, May 24, 1904. Tumor, with axillary glands, entirely removed. Pathological report confirmed diagnosis. Good recovery followed. Careful study of this question impresses one with the knowledge that when an operation is done before involvement of the axillary region a better percentage of recoveries follows.

CASE IX.—Miss L. K., aged fifty-nine years. In 1900 was operated upon by a surgeon who did not think it necessary to remove the axillary glands. In October, 1901, a tumor presented in the axilla and scar tissue. January, 1902, she first consulted me, at which time growth in axilla and scar were considered inoperable, and *x*-ray treatment employed with benefit in relieving pain and reducing tumor in size, but did not result in permanent relief.

Digitized by Google

In the table of operations there are two cases of metastasis to the long bone.

CASE X.—Mrs. M. C., aged fifty-seven years, a large woman, well developed and much adipose tissue. General health not affected and patient much opposed to operation with knife. Trouble began January, 1901, when growth in right breast was first noticed, which gradually increased, but no marked pain. Patient took various treatments, including *x*-ray and injections hypodermically. June 17, 1902, she presented with a large tumor involving the right breast, with axillary glands enlarged and causing her much distress from pressure of the arms upon them, against the chest. I did a very thorough operation, removing the pectoral muscle, the subclavian glands, and to close wound brought up flaps from the side and surface of the abdomen. Patient made a good recovery and left the hospital in excellent condition. Laboratory report on specimen as follows: Scirrhous carcinoma with metastases to lymphatic glands. This patient continued in good health, with the exception, at times, of complaining of pain in region of and underneath the scapula, and of some swelling of right arm. This disappeared in time; she was able to attend to her household duties and remained well until the summer of 1905, when she showed more marked cachexia, but no appearance of metastases could be discovered. The original scar was in excellent condition. About the first of August, in getting up from bed one morning she suddenly collapsed, and upon being taken up and placed in a chair it was found she was unable to use her left leg. She was brought to the hospital, and examination revealed a fracture of the upper third of left femur with the evidence of carcinoma being present. She also complained of pain in her left chest, and on examination there was found quite a pleuritic effusion. Patient was placed in bed, the limb properly dressed, bowels and kidneys carefully watched, and for four weeks she improved, but finally died from all the evidence of carcinoma of the pleura, possibly of the lung, on the left side.

I have been greatly impressed in the cases in this table that have come to me, in which there was a well-defined carcinoma of the

Digitized by Google

breast and also fibroid tumors of the uterus. In these cases I have operated for both conditions, cases generally doing well, but there is a greater degree of anxiety to the surgeon. Again, in others, I have only removed the breast, and these patients seem to live on very comfortably for many years, with no apparent disturbance from the uterine fibroid. Patients who have passed the menopause do best.

The element of traumatism in carcinoma of the breast has ever commanded my careful thought. Is it a factor? We must heed the history of such cases as the following:

CASE XI.—Miss D. P., aged forty-two years, who gave a very unusual history. In October, 1902, she presented with a history of a gradually developing tumor, which followed traumatism of the right breast. Patient had struck against a chair in January, 1902, and hurting herself. May, 1902, she noticed marked pain over the region of original injury. Tumor now about the size of an orange, painful, movable, and with axillary involvement. Operation done, axillary space thoroughly cleaned out, and patient made a good recovery. At this time we also removed a uterine polypus, which laboratory reported non-malignant in character. Growth removed from breast was reported carcinoma, with papillomatous changes of nipple and metastasis to axillary lymph nodes. She made a good recovery, gained in flesh and in every way felt herself thoroughly well until February, 1906, when she was not so well, having a marked pain in left side. She presented for examination February 21, 1906, when a diagnosis of pleurisy with effusion was made, chest was aspirated and three pints of serous fluid were removed. At this examination her family physician, Dr. Larkin, discovered a hard mass associated with the left breast, which the patient said she knew very little about. Nipple was retracted, mass movable, very hard, scirrhous in character and axillary glands also involved. Following further effusion a second aspiration was done and about sixteen ounces of fluid removed.

The patient recovered, and was so encouraged, and expressed such a strong desire for removal of the breast that an operation

Digitized by Google

was done June 2, 1906. She made a steady, uninterrupted recovery from all of her ills and in every way it was a successful case.

She returned home but later had further attacks of pleurisy and died, evidently, from metastasis of the pleura, about six months after the second operation. This case illustrates the cancerous diathesis most earnestly.

It is a matter of interest in our patients who are exceedingly fleshy, to note the difficulty that sometimes exists in reaching an early diagnosis, but I have an impression that these patients are very susceptible to the least disturbance about the glands and a pain, be it ever so slight, attracts their attention at once. A clinical diagnosis is not always so easy.

CASE XII bears upon this point. Mrs. S. C., aged thirty-four years. Family history strongly cancerous, several members having died from this trouble, including her mother, and this history was a source of great anxiety to her. July, 1902, first noticed lancinating, characteristic pain in right breast, and six weeks ago noticed a tumor. Axillary glands involved. Prompt operation was done January 25, 1903, believing, from the clinical history that this patient was suffering from acute carcinoma of the breast. She weighed two hundred pounds. Thorough removal was done and report from the laboratory showed growth to be a cystic fibroma of breast with lympho-adenitis.

It is very instructive to note how short a time sometimes elapses in the period that a tumor is apparently developing.

CASE XIII.—Mrs. B. M., aged sixty-five years, three months previously had slight pain in left breast. Now there is a tumor size of a pigeon's egg which has grown rapidly. Not much loss of weight or strength. When patient presented for examination and treatment growth was ulcerated, rectangular in shape, and measured 17 x 12 cm., seemed movable with a very offensive odor, and glands of axilla involved. Thorough operation was done November 12, 1902, and patient made a good recovery. Pathological report from laboratory: Very cellular, medullary carcinoma.

Digitized by Google

The following cases, giving a tuberculous history, are impressive:

CASE XIV.—Mrs. A. L. W., aged thirty-seven years. This case arouses the sympathy of the surgeon. She gave a family history of most pronounced tuberculous trouble, and had had some early lung affection herself. In the beginning of 1903 she discovered a small growth in her right breast, which alarmed her, but of which she said very little to her family. At first it developed very slowly, but later, with slight, characteristic, lancinating pain it began to grow more rapidly. She lost in appetite and weight and presented the appearance of a patient much worried about herself. When she came to my office, December 29, 1903, I told her husband and herself that she undoubtedly had cancer of the breast and that an immediate operation was advisable. To this they readily consented, although they had been advised differently. The operation, December 31, 1903, was a most serious one involving about three inches of the axillary vein, which I was obliged to dissect out and ultimately ligate the axillary artery, resecting a portion of it with the tumor. The nerve supply was preserved. The collateral circulation was sufficient to maintain life and no gangrenous spots appeared, yet great coldness of the arm in the healing of the wound. No radial artery could be made out after her recovery, although she got the use of her hand and forearm very well. The wound remained in good condition for about eight months, when a slight nodule appeared in the upper portion of the scar. She now returned to the hospital and had a most complete, thorough application of the *x*-rays with a disappearance of the nodule, the suffering and indurated tissue, and the swelling of the arm, so that the patient really felt very much better; however, the same conditions returned in other portions of the cicatrix and a second operation was done October 28, 1904, for removal of the secondary deposits, a plastic operation performed, and patient made a very good recovery. She gained somewhat in flesh and was most hopeful that she might ultimately get well. She was faithful and earnest in her treatment, aiding her recovery in every way possible. I occasionally heard from her, and on April 15, 1907, her husband wrote me that the case had not changed materially

Digitized by Google

in a long time, although she was gradually growing weaker. No tumor had developed to any extent nor was there evidence of metastases. The great complaint was the immense swelling of the right arm, which gave her a good deal of pain.

Surely this case is one that has shown a degree of malignancy and yet a power of resistence on the part of the patient most remarkable to observe.

Digitized by Google

FINAL RESULTS IN 164 CASES OF CARCINOMA OF THE BREAST OPERATED DURING THE PAST FOURTEEN YEARS AT THE AUGUSTANA HOSPITAL.

By A. J. OCHSNER, M.D.,
CHICAGO.

In order to condense the study of these 164 cases sufficiently to prevent this report from becoming altogether unwieldy, it has seemed best to make the following tabulations which were compiled by my associate, Dr. N. M. Percy, from the case histories. The present condition of 98 patients was determined by correspondence with patients and with their physicians, or by personal examination.

From 63 cases no information has been obtained as yet, but only twenty letters have been returned unopened, consequently it is fair to suppose that further information can be obtained concerning the condition of some of the 63 cases not heard from.

Of the 98 cases, concerning which we have received reports, 54 cases are still living and all of these with two exceptions are at the present time free from recurrence.

The first of these patients, Case 38, had a carcinoma of both breasts, which were removed, by primary operation in 1895, elsewhere. In 1897 she had a recurrence in the left axilla which we operated on December 7, 1897. This side has remained well since. In 1899 she had a recurrence in the right axilla which was removed elsewhere, which has just developed a second recurrence.

A second case (45), operated September 19, 1898, for carcinoma of the breast, remained well until six months ago, when she noticed a swelling the size of a walnut, which has not been definitely diagnosticated, although it is likely that it is a recurrence. I have not examined this patient personally since the operation.

The following table gives the number of living cases from which we have definite reports·

Digitized by Google

	Years.	Cases.
Duration of time since operation.	1	9
" " " "	2	11
" " " "	3	5
" " " "	4	7
" " " "	5	4
" " " "	6	5
" " " "	7	4
" " " "	8	1
" " " "	9	3
" " " "	10	1
" " " "	11	2
" " " "	12	0
" " " "	13	2
Total		—54

Three years and over, 34 cases; five years or over, 22 cases; ten years or over, 5 cases.

Of the 54 living cases heard from, 10 complain of swelling or stiffness of the arm.

An interesting fact observed in our series of cases is shown by the following table of deaths:

It was found that but few of the very advanced cases which were considered quite hopeless at the time of operation lived more than one year after the operation, making the number that died directly after the operation from shock, together with those who lived less than one year, 25 or about 15 per cent.

Deaths.

	Cases.
Died of shock	5
Died within 1 year	20
" " 2 years	6
" " 3 years	6
" " 4 years	1
" " 5 years	2
" " 6 years	1
" " 7 years	1
" " 8 years	0
" " 9 years	0
" " 10 years	0
" " 11 years	1
" " 12 years	0
" " 13 years	0
" " 14 years	1
Total	—44

Cases not heard from 63.

Digitized by Google

Of the 44 patients whose deaths have been reported only 39 died either as a result of the operation or from recurrence.

The following 5 cases died from other causes than carcinoma, all having lived over three years after the operation without recurrence. 2 cases lived for three years, and one each for five, seven, and ten years.

Case 18, aged forty-seven years, died three years after operation from some other trouble. No signs of recurrence.

Case 26, aged fifty-seven years, died ten years and six months after operation from apoplexy. No signs of recurrence.

Case 32, aged fifty-nine years, died five years after operation from nephritis. No signs of recurrence.

Case 42, aged fifty-eight years, died seven years after operation. No signs of recurrence.

Case 116, aged fifty-four years, died three years after operation from pneumonia. Ho signs of recurrence.

The following case seems to have special interest:

Case 12, aged forty-four years, was operated upon March 12, 1894. One year later had recurrence in scar. A paste was applied, causing necrosis of the wound. This healed completely and the patient has been perfectly well since. Now thirteen years and two months since operation.

Postoperative X-ray Treatment.

It has seemed proper to use *x*-ray treatment systematically in all cases after operation. This, however, was not always possible in patients living in the smaller country towns.

Cases which had X-ray Treatments.

All cases operated during the past six years had *x*-ray exposures during the patient's stay in the hospital. Of the cases heard from 22 took *x*-ray treatment after leaving the hospital.

The following cases seem to be sufficiently interesting to justify special abstracts of their histories:

Digitized by Google

Case 87, aged twenty-nine years, was operated May 17, 1901. Six months later she had a recurrence in the line of the incision of the axilla and cervical glands and apparently a carcinoma in the cranial cavity causing a marked protrusion of the right eye. All of these disappeared under *x*-ray exposures. The patient was last heard from one year ago. She was perfectly well at this time, five years after the operation.

Case 96, aged sixty years. Had recurrence one year after operation. This disappeared under *x*-ray exposures, but recurred two years later, causing her death.

Case 125, aged fifty years, was operated upon January 24, 1904. Following this had recurrence in scar. Was given vigorous *x*-ray exposures, with very little benefit. Arsenic was applied to the wound, causing necrosis of a considerable amount of tissue. Wound healed completely. The patient is perfectly well now.

Case 129, aged forty-three years. Operated upon September 9, 1904. Had primary operation three months previously, when only a portion of the breast was removed. Had second recurrence, a few months later, involving skin for a distance of several centimeters on each side of the scar. Under *x*-ray exposures, and the treatment by hypodermic injections, of a proprietary remedy, the recurrence disappeared, and patient is now perfectly well.

Case 163, aged fifty-four years. Primary operation February, 1900. A few months later a second recurrence involving scar and axilla and cervical glands, making the case apparently inoperable. This disappeared under *x*-ray treatment and remained well for four years. Third recurrence, 1 cm. in diameter about middle of scar, began one year ago. This was excised December 10, 1906. Has had *x*-ray treatment most of the time during the past five years. At present she is free from recurrence.

Case 164, aged forty-eight years, was operated upon May 23, 1889. Had recurrence ten years later, which was excised May 23, 1899. Recurred one year later. Has had *x*-ray treatments continually for three and one-half years, when she died of carcinoma.

Digitized by Google

Number.	Hospital Number.	Age	Involvement of				Date of operation.	Operation.	Date of last communication of patient.	Result.
			Ax. glan's	Cer. glan's	Skin.	Muscle.				
1	265	45	x	...	...	...	April 26, 1887	Excision of breast and axillary glands.	.....	Died 10 months later.
2	350	49	...	...	...	...	Jan. 12, 1888	Excision of breast.	None.	
3	711	40	x	...	...	...	April 19, 1891	Excision of breast and axillary glands.	None.	
4	714	62	x	...	...	...	May 8, 1891	Excision of breast and axillary glands	None.	
5	787	56	...	...	...	...	Oct. 4, 1891	Excision of breast.	None.	
6	799	44	...	...	...	...	Nov. 3, 1891	Excision of breast.	None.	
7	961	50	x	...	...	...	Sept. 18, 1892	Excision of breast and axillary glands.	None.	
8	1069	45	x	...	...	...	March 28, 1893	Excision of breast and axillary glands.	.....	Recurrence in 3 months. Died 6 months later.
9	1224	61	x	..	...	...	Oct. 24, 1893	Excision of breast and axillary glands.	None.	
10	1293	47	x	x	x	...	Jan. 2, 1894	Excision of breast, axillary and cervical glands.	.....	Died 6 weeks later of carcinoma of liver, pancreas and kidneys.
11	1319	39	...	...	...	...	Jan. 30, 1894	Excision of breast.	None.	
12	1373	44	...	...	...	...	March 12, 1894	Excision of breast.	April 16, 1907.	Had recurrence 1 year later. Doctor applied paste causing necrosis. Perfectly well since.
13	1673	36	x	...	x	x	Oct. 19, 1894	Excision of breast and axillary glands.	.....	Had rapid recurrence.
14	1850	31	x	...	...	...	Dec. 26, 1894	Excision of breast and axillary glands.	April 24, 1907.	No recurrence since first illness.
15	1970	82	...	...	...	...	Feb. 14, 1895	Excision of breast.	None.	
16	2133	63	...	...	...	...	June 2, 1895	Excision of breast.	None.	
17	2187	45	x	...	...	...	July 1, 1895	Excision of breast and axillary glands.	None.	
18	2351	47	...	...	...	...	Sept. 6, 1895	Excision of breast and axillary glands.	April 15, 1905.	No recurrence in 3 years when she died of some other disease.
19	2621	44	...	...	...	...	Jan. 21, 1896	Excision of breast.	None.	
20	3750	66	x	...	...	...	Feb. 17, 1896	Excision of breast and axillary glands.	None.	
21	2702	39	...	...	...	...	Feb. 17, 1896	Excision of breast.	None.	
22	2705	42	x	...	x	...	Feb. 18, 1896	Excision of breast and axillary glands. Skin-grafted.	.....	Died 9 months after operation apparently from involvement of internal organs.

Digitized by Google

23	2863	52	x	x	x	x	May 9, 1896	Excised axillary and cervical glands. Excision of breast and pectoral muscles.	.....	Never seemed to gain much strength and died about 4 months after operation.
24	3001	38	...	...	...	...	June 24, 1896	Excision of breast.	None.	
25	3110	46	...	...	...	...	Aug. 10, 1896	Excision of breast.	None.	
26	3292	57	x	...	...	...	Oct. 18, 1896	Excision of breast and axillary glands.	April 16, 1907.	No recurrence. Died of apoplexy April 12, 1907.
27	3228	37	...	...	...	...	Oct. 29, 1896	Excision of breast.	April 16, 1907.	Perfectly well since.
28	3367	37	x	...	...	...	Nov. 16, 1896	Excision of breast and axillary glands.	None.	
29	3373	56	x	x	x	x	.....	Inoperable. Applied calcium carbide.	.....	No relief.
30	3548	60	...	...	...	...	Feb. 5, 1897	Excision of breast.	None.	
31	3705	50	...	...	...	...	March 31, 1897	Excision of breast.	None.	
32	3745	59	...	...	...	.	April 18, 1897	Excision of breast.	April 17, 1907.	No recurrence in 5 years when she died of nephritis.
33	3799	25	x	...	...	...	May 11, 1897	Excision of breast and axillary glands.	None.	
34	3945	46	x	...	...	...	July 5, 1897	Excision of breast and axillary glands.	None.	
35	4034	63	x	...	...	...	July 31, 1897	Excision of breast and axillary glands.	None.	
36	4095	36	x	...	...	...	Aug. 24, 1897	Excision of breast and axillary glands.	None.	
37	4395	57	x	...	...	...	Dec. 1, 1897	Excision of breast and axillary glands.	April 22, 1907.	No recurrence. Fairly good health.
38	4410	29	x	...	x	x	Dec. 7, 1897	Recurrent case; excision pectoral and major and minor muscles and axillary glands.	April 21, 1907.	Both breasts removed. Primary operation 1895. Recurred left axilla 1897. Recurred right axilla 2 years later, which was removed 18 months ago. Now has another recurrence in right axilla.
39	4783	48	x	...	...	...	March 29, 1898	Excision of breast and both pectoral muscles and axillary glands.	None.	
40	4909	39	...	...	...	...	May 3, 1898	Excision of breast.	None.	
41	5155	44	x	...	...	...	May 22, 1898	Excision of breast and axillary glands.	April 19, 1907.	No recurrence. Never felt better than she does now.
42	5156	58	x	...	...	...	Aug. 12, 1898	Excision of breast and axillary glands.	April 15, 1907.	No recurrence in 7 years, when she died of some other disease.
43	5281	48	x	...	...	...	Aug. 21, 1898	Excision of breast and axillary glands.	None.	
44	5362	44	x	...	...	...	Sept. 11, 1898	Excision of breast and axillary glands.	Examined April 8, 1907.	No signs of recurrence. General health good.
45	5397	45	x	...	...	...	Sept. 19, 1898	Excision of breast and axillary glands.	April 18, 1907.	Felt poorly for 4 years after operation. Since then very well. Some stiffness of arm from shoulder to elbow. 6 months ago noticed swelling size of walnut. Did not state location.

Digitized by Google

Number.	Hospital Number.	Age	Involvement of				Date of operation.	Operation.	Date of last communication of patient.	Result.
			Ax. glan's	Cer. glan's	Skin.	Muscle				
46	5415	55	x	...	...	...	Sept. 27, 1898	Excision of breast and axillary glands.	.....	Died of cancer 2 years after operation.
47	5460	50	x	...	...	...	Oct. 5, 1898	Excision of breast and axillary glands.	None.	
48	5484	50	x	...	...	...	Oct. 15, 1898	Excision of breast and axillary glands.	None.	
49	5525	53	x	...	...	...	Oct. 27, 1898	Excision of breast and axillary glands and pectoral muscles.	None.	
50	5541	34	x	...	...	...	Nov. 1, 1898	Excision of breast and axillary glands and pectoral muscles.	None.	
51	5637	44	x	...	...	...	Dec. 6, 1898	Excision of breast and axillary glands and pectoral muscles.	None.	
52	5684	42	...	...	...	...	Dec. 27, 1898	Excision of breast.	None.	
53	5822	41	x	x	x	...	Feb. 4, 1898	Excision of breast and pectoral muscles and axillary and cervical glands.	.....	Died of shock on fourth day.
54	5830	25	...	...	...	...	Feb. 5, 1898	Excision of breast	None.	
55	5887	62	x	...	...	...	Feb. 19, 1898	Excision of breast and pectoral muscles and axillary glands.	.....	Had recurrence in scar 18 months later.
56	6113	26	x	...	...	...	April 23, 1899	Excision of breast and pectoral muscles and axillary glands.	None.	
57	6171	28	x	...	...	...	May 10, 1899	Excision of breast and pectoral muscles and axillary glands. Skin-grafted.	.....	Had rapid recurrence and died about 4 months after operation.
58	6258	38	x	...	...	...	May 30, 1899	Excision of breast and pectoral muscles and axillary glands.	None.	
59	6552	42	x	...	...	...	Aug. 17, 1899	Excision of breast.	None.	
60	6631	50	x	...	...	...	Sept. 17, 1899	Excision of breast and pectoral muscles and axillary glands.	None.	
61	6773	48	x	...	...	...	Oct. 9, 1899	Excision of breast and pectoral muscles and axillary glands.	None.	

Digitized by Google

62	6905	65	...	...	...	...	Nov. 12, 1899	Excision of breast and pectoral muscles and axillary glands.	None.	
63	6968	46	...	...	...	...	Dec. 13, 1899	Excision of breast and pectoral muscles and axillary glands.	April 15, 1907.	Perfectly well. Can use arm nearly as well as other side.
64	7071	64	x	...	...	...	Jan. 4, 1900	Excision of breast and pectoral muscles and axillary glands.	April 26, 1907.	Operation successful. Never troubled since.
65	7109	55	x	...	...	...	Jan. 16, 1900	Excision of breast and pectoral muscles and axillary glands.	None.	
66	7211	44	x	...	...	...	Feb. 7, 1900	Excision of breast and pectoral muscles and axillary glands.	April 18, 1907.	No recurrence. Considerable swelling and disability of arm for 3 years, but since then no trouble.
67	7350	34	...	...	...	...	March 12, 1900	Excision of breast and pectoral muscles and axillary glands.	None.	
68	7394	67	...	...	...	...	March 21, 1900	Excision of small nodule from old scar size of pea.	None.	Recurrent case. Had breast excised 6 months previously. Skin recurrence in line of excision.
69	7427	39	x	...	...	...	March 27, 1900	Excision of breast and pectoral muscles and axillary glands.	.....	Died of recurrence 3 years later.
70	7528	31	x	...	...	...	April 24, 1900	Excision of breast and pectoral muscles and axillary glands.	None.	
71	7530	77	x	...	...	...	April 24, 1900	Excision of breast and pectoral muscles and axillary glands.	.....	Died of shock on fourth day.
72	7554	37	x	...	x	x	April 29, 1900	Excision of breast and pectoral muscles and axillary glands.	.....	Had rapid recurrence and died about 6 months after operation.
73	7717	40	x	...	...	...	June 5, 1900	Excision of breast and pectoral muscles and axillary glands.	None.	
74	7749	48	x	x	x	x	June 12, 1900	Excision of breast and pectoral muscles and axillary glands.	.....	Died of shock next day.
75	7968	66	x	...	...	...	Aug. 9, 1900	Excision of breast and pectoral muscles and axillary glands.	.....	Died of shock same night.
76	8083	44	x	...	...	...	Sept. 8, 1900	Excision of breast and pectoral muscles and axillary glands.	April 15, 1907.	In good health. No recurrence.
77	8103	61	x	...	...	...	Sept. 11, 1900	Excision of breast and pectoral muscles and axillary glands.	None.	

Digitized by Google

Number.	Hospital Number.	Age	Involvement of				Date of operation.	Operation.	Date of last communication of patient.	Result.
			Ax. glan's	Cer. glan's	Skin.	Muscle.				
78	8123	38	...	...	x	...	Sept 16, 1900	Excision of large area of skin. Skin-grafted.	.....	Recurrent case.
79	8141	65	...	...	x	...	Sept. 20, 1900	Excision of nodule in scar.	.....	Primary operation 18 months previous. Recurrent nodule in scar. Lived 3 years after this. Four and one-half years after previous operation.
80	8154	50	x	...	...	...	Sept. 23, 1900	Excision of breast and pectoral muscles and axillary glands.	None.	
81	8350	37	x	...	...	...	Jan. 1, 1900	Excision of breast and pectoral muscles and axillary glands.	April 16, 1907	No recurrence. No *x*-ray.
82	8575	35	x	...	...	...	Jan. 9, 1901	Excision of breast and pectoral muscles and axillary glands.	April 19, 1907.	No return of trouble. Perfectly well since operation.
83	8648	57	x	...	...	...	Jan. 23, 1901	Excision of breast and pectoral muscles and axillary glands.	April 20, 1907.	Perfectly well since operation. Very useful arm.
84	8742	43	...	...	...	...	Feb. 5, 1901	Excision of breast and pectoral muscles and axillary glands.	April 18, 1907.	Examined personally. No signs of recurrence. No edema of arm.
85	8838	39	x	...	...	...	March 6, 1901	Excision of breast and pectoral muscles and axillary glands.	None.	
86	9038	46	...	...	...	...	April 18, 1901	Excision of breast and pectoral muscles and axillary glands.	April 16, 1907.	No return of disease. Has experienced considerable discomfort with arm.
87	9147	29	x	...	...	...	May 17, 1901	Excision of breast and pectoral muscles and axillary glands.	One year ago perfectly well	Two years later recurrence in line of incision, axilla and cervical region. All disappeared under *x*-ray treatment.
88	9222	56	x	...	...	...	June 3, 1901	Excision of breast and pectoral muscles and axillary glands.	.....	Had recurrence in axillary glands of opposite side in 3 months. Died 6 months later.
89	9331	76	x	...	x	...	June 26, 1901	Excision of breast and pectoral muscles and axillary glands.	None.	
90	9538	31	x	...	...	...	Aug. 13, 1901	Excision of breast and pectoral muscles and axillary glands.	None.	

Digitized by Google

91	9542	38	x	...	...	...	Aug.	31, 1901	Excision of breast and pectoral muscles and axillary glands.	None.
92	975[illegible]	34	x	...	...	...	Oct.	2, 1901	Excision of breast and pectoral muscles and axillary glands.	.....
93	9793	67	x	...	...	...	Oct.	5, 1901	Excision of breast and pectoral muscles and axillary glands.	.....
94	9800	42	x	...	x	...	Oct.	7, 1901	Excision of breast and pectoral muscles and axillary glands.	.....
95	9841	70	x	...	x	...	Oct.	19, 1901	Excision of breast and pectoral muscles and axillary glands.	None.
96	9904	60	x	...	x	...	Oct.	31, 1901	Excision of breast and pectoral muscles and axillary glands.	.....
97	9952	41	x	...	...	...	Nov.	15, 1901	Excision of breast and pectoral muscles and axillary glands.	1 year ago.
98	10167	60	x	...	x	...	Jan.	10, 1902	Excision of breast and pectoral muscles and axillary glands. Skin-grafted.	.....
99	9958	32	x	...	...	...	Nov.	18, 1902	Excision of breast and pectoral muscles and axillary glands.	.....
100	10390	48	x	...	x	...	Feb.	28, 1902	Excision of breast and pectoral muscles and axillary glands.	April 12, 1907
101	10441	67	x	...	...	...	March	10, 1902	Excision of breast and pectoral muscles and axillary glands.	None.
102	10656	67	x	x	x	...	June	23, 1902	Inoperable. No improvement.	None.
103	10933	66	x	x	x	...	June	23, 1902	Excision of recurrent mass in skin and axillary and cervical glds.	.....
104	11064	52	x	...	...	...	July	21, 1902	Excision of breast and pectoral muscles and axillary glands.	.....
105	11437	64	...	...	...	...	Sept.	29, 1902	Excision of breast and pectoral muscles and axillary glands.	.....
106	11658	54	x	...	...	...	Nov.	22, 1902	Excision of both breasts for carcinoma.	.....

Died a few months later apparently from some internal recurrence.
Died May, 1905. Had *x*-ray treatment for 3 years.
Died of recurrence April 1, 1903. Took *x*-ray for 1 year.
Recurred 1 year. Recurrence disappeared under *x*-ray. Recurred 2 years later. Died 3 years after operation.
No recurrence.
Had rapid recurrence and died 4 months later.
Died of recurrence 2 years later. Had *x*-ray treatment.
Perfectly well. Took *x*-ray treatment for 1 year.
Primary operation 6 years previous. Not heard from since second operation.
Had other breast excised for carcinoma 2 years previously. *x*-ray for 1 year after first operation.
Died of recurrence in May, 1903.
Died of cancer of stomach 1 year later.

Digitized by Google

Number.	Hospital Number.	Age	Involvement of				Date of operation.	Operation.	Date of last communication of patient.	Result.
			Ax. glan's	Cer. glan's	Skin.	Muscle.				
107	11790	41	...	...	...	...	Dec. 8, 1902	Excision of breast and pectoral muscles and axillary glands.	April 15, 1907.	Took 60 *x*-ray treatments after operation. No recurrence. Great deal of pain in shoulder.
108	12015	33	x	...	...	...	Jan. 21, 1903	Excision of breast and pectoral muscles and axillary glands.	.....	18 months after operation had recurrence in ilium from which she died. Had *x*-ray treatment 1 year following operation.
109	12098	57	x	...	...	...	Feb. 6, 1903	Excision of breast and pectoral muscles and axillary glands.	April 13, 1907.	No recurrence. Great deal of edema of arm. *x*-ray for 1 year.
110	12130	44	x	...	x	x	Feb. 13, 1903	Excision of breast and pectoral muscles and axillary glands.	None.	
111	12141	41	x	...	...	...	Feb. 15, 1903	Excision of breast and pectoral muscles and axillary glands.	Feb. 26, 1907.	No recurrence. Great deal of edema in arm.
112	12384	52	x	x	...	...	April 1, 1903	Excision of breast and pectoral muscles and axillary glands.	.....	Died of recurrence a few months after operation.
113	12423	56	x	...	x	...	April 10, 1903	Excision of breast and pectoral muscles and axillary glands.	Nov., 1906.	No signs of recurrence. Considerable edema of arm.
114	12424	47	x	...	...	...	April 10, 1903	Excision of breast and pectoral muscles and axillary glands.	None.	
115	12469	75	x	...	...	...	April 17, 1903	Excision of breast and pectoral muscles and axillary glands.	.....	Died one year after operation. No local signs of recurrence.
116	12740	54	x	...	...	...	June 8. 1903	Excision of breast and pectoral muscles and axillary glands.	.....	Died three years later from pneumonia. No signs of recurrence.
117	12866	64	...	...	...	...	June 30, 1903	Excision of breast and pectoral muscles and axillary glands.	None.	
118	12983	58	x	...	...	...	July 24, 1903	Excision of breast and pectoral muscles and axillary glands.	None.	
119	13017	57	x	...	...	...	July 30, 1903	Excision of breast and pectoral muscles and axillary glands.	.....	Died of cancer in chest 6 months later.
120	13019	43	x	...	...	...	July 31, 1903	Excision of breast and pectoral muscles and axillary glands.	April 11, 1907.	Perfectly well since operation.

Digitized by Google

121	13154	40	x	...	...	...	Aug.	26, 1903	Excision of breast and pectoral muscles and axillary glands.	May 1, 1907.	Perfectly well. Had few *x*-ray treatments.
122	13396	47	x	...	...	...	Oct.	9, 1903	Excision of breast and pectoral muscles and axillary glands.	April 12, 1907.	*x*-ray for 3 months. One year later carcinoma developed in other breast. This was removed. Well now.
123	13415	45	x	...	...	...	Oct.	12, 1903	Excision of breast and pectoral muscles and axillary glands.	April 13, 1907.	30 *x*-ray treatments after operation. Slight swelling of arm. Otherwise well.
124	13423	30	...	...	x	...	Oct.	12, 1903	Excision of breast and fascia of pectoral muscle and axillary glands	None.	
125	13905	50	...	...	x	...	Jan.	24, 1904	Excision of small nodule from old scar.	April 22, 1907.	Recurrent case. Primary operation January 30, 1903. Had several slight recurrences after second operation which were cauterized with arsenic. Healed after this.
126	13990	44	x	...	...	...	Feb.	15, 1904	Excision of breast and pectoral muscles and axillary glands.	.....	Died 18 months after operation of carcinoma.
127	14783	39	...	...	...	...	July	18, 1904	Excision of breast and pectoral muscles and axillary glands.	April 11, 1907.	*x*-ray for 3 months after operation. Perfectly well now.
128	14971	62	x	...	x	x	Aug.	31, 1904	Excision of breast and pectoral muscles and axillary glands.	None.	
129	15004	43	x	...	x	x	Sept.,	1904	Excision of breast and pectoral muscles and axillary glands.	Jan., 1907.	Recurrent case. Had portion of breast removed 3 months previously. Again had recurrence. *x*-ray and serum treatment. Now well.
130	15229	95	...	...	...	...	Oct.	22, 1904	Excision of breast and pectoral muscles and axillary glands.	April 12, 1907.	Perfectly well.
131	15388	39	x	...	...	...	Nov.	26, 1904	Excision of breast and pectoral muscles and axillary glands.	None.	
132	15398	35	x	x	x	...	Nov.	30, 1904	Excision of breast and pectoral muscles and axillary glands.	.....	Had rapid recurrence and died April 26, 1905.
133	15440	60	x	...	x	...	Dec.	7, 1904	Excision of breast and pectoral muscles and axillary glands.	April 10, 1907.	No return of disease. General health very good.
134	15533	70	...	...	...	...	Jan.	4, 1905	Excision of breast and pectoral muscles and axillary glands.	April 12, 1907.	Examined personally. No sign of recurrence.
135	15774	45	x	...	x	...	Feb.	22, 1905	Excision of breast and pectoral muscles and axillary glands. Skin-grafted.	.....	Died October 16, 1905, apparently from carcinoma inside of chest.

Digitized by Google

Number.	Hospital Number.	Age	Involvement of				Date of operation.	Operation.	Date of last communication of patient.	Result.
			Ax. glan's	Cer. glan's	Skin.	Muscle.				
136	15782	51	x	...	...	...	Feb. 24, 1905	Excision of breast and pectoral muscles and axillary glands.	May 4, 1907.	Perfectly well.
137	15800	45	x	...	...	...	March 1, 1905	Excision of breast and pectoral muscles and axillary glands.	April 18, 1907.	Took long time to regain strength. Perfectly well now.
138	15182	85	...	...	...	...	May 1, 1905	Excision of breast and pectoral muscles and axillary glands.	None.	
139	16253	72	...	...	...	...	May 24, 1905	Excision of breast and pectoral muscles and axillary glands.	April 14, 1907.	About 3 months after operation a small nodule appeared above clavicle. Has remained same ever since. No pain.
140	16346	40	x	...	x	...	June 5, 1905	Excision of breast and pectoral muscles and axillary glands.	April 15, 1907.	Has taken 27 *x*-ray treatments. No recurrence.
141	16351	46	...	...	...	...	June 5, 1905	Excision of breast and pectoral muscles and axillary glands.	.....	
142	16464	55	...	...	...	...	June 23, 1905	Excision of breast and axillary glands and left pectoral muscle.	April 14, 1907.	No recurrence. General health has not been as good in years.
143	16813	45	x	...	...	...	Aug. 23, 1905	Excision of breast and pectoral muscles and axillary glands.	April 12, 1907.	No signs of recurrence.
144	16824	39	x	...	x	...	Aug. 25, 1905	Excision of breast and pectoral muscles and axillary glands.	.....	Died 8 months later from carcinoma in chest.
145	17212	44	x	...	...	...	Oct. 23, 1905	Excision of breast and pectoral muscles and axillary glands.	April 15, 1907	Perfectly well except some swelling of arm.
146	17246	57	x	...	...	...	Oct. 27, 1905	Excision of breast and pectoral muscles and axillary glands.	None.	
147	17401	45	x	...	...	...	Nov. 22, 1905	Excision of breast and pectoral muscles and axillary glands.	April 21, 1907.	Perfectly well except at times has stiffness in arm.
148	47515	54	x	...	x	x	Dec. 11, 1905	Excision of breast and pectoral muscles and axillary glands.	.....	Had rapid recurrence and died July 22, 1906.
149	17556	44	x	...	...	...	Dec. 18, 1905	Excision of breast and pectoral muscles and axillary glands.	April 18, 1907.	Some numbness in arm Otherwise well.

Digitized by Google

150	17558	38	...	...	x	...	Dec.	20, 1905	Excision of breast and pectoral muscles and axillary glands.	.....	Died about 10 months later of carcinoma.
151	17606	50	...	...	...	...	Dec.	26, 1905	Amputation of arm and scapula and part of clavicle.	.....	Recurrent case. Primary operation June, 1905. Died of shock.
152	17656	57	x	...	x	...	Jan.	3, 1905	Excision of breast and pectoral muscles and axillary glands.	April 12, 1907. Examined.	There was evidence of local recurrence. This removed by actual cautery. Wound not completely healed. Still takes *x*-ray.
153	17883	73	x	...	...	...	Feb.	2, 1906	Excision of breast and dissected axilla.	April 3, 1907. Examined.	Perfect result. No signs of recurrence.
154	17907	48	x	...	...	...	Feb.	7, 1906	Excision of breast and pectoral muscles and axillary glands.	None.	
155	18694	52	x	...	...	...	June	11, 1906	Excision of breast and pectoral muscles and axillary glands.	April 22, 1907.	No signs of recurrence. Has pain in arm if she uses it too much.
156	18752	39	x	...	...	...	June	18, 1906	Excision of breast and pectoral muscles and axillary glands.	April 28, 1907.	No return of former disease. *x*-ray 3 times a week for 5 weeks.
157	18979	55	x	...	...	...	July	28, 1906	Excision of breast and pectoral muscles and axillary glands.	March 4, 1907.	No recurrence. Some contraction of scar in axilla.
158	18981	56	...	...	...	...	July	28, 1906	Excision of breast and pectoral muscles and axillary glands.	April 30, 1907.	Perfectly well. Has had 24 *x*-ray treatments.
159	19033	49	x	...	...	...	Aug.	1, 1906	Excision of breast and pectoral muscles and axillary glands.	April 18, 1907.	No signs of recurrence. Arm somewhat stiff.
160	19258	47	x	...	...	...	Sept.	3, 1906	Excision of breast and pectoral muscles and axillary glands.	April 15, 1907.	Perfect result. *x*-ray treatment for 4 months.
161	19636	64	...	...	...	...	Oct.	26, 1906	Excision of breast and pectoral muscles and axillary glands.	April 18, 1907.	Took *x*-ray treatment for 5 weeks. Feels perfectly well.
162	19799	65	x	...	x	x	Nov.	28, 1906	Excision of breast and pectoral muscles and axillary glands and cauterized over ribs.	.....	Died February 2, 1907, from extension of carcinoma into chest.
163	19904	54	...	...	x	x	Dec.	10, 1906	Excision of mass in old scar and cauterized base of wound with actual cautery.	.....	First operation, February, 1900. Rapid recurrence. Second operation, October 19, 1900. In 1901, another recurrence which disappeared under *x*-ray treatment. Present recurrence began one year ago.
164	.....	48?	...	...	...	...	May	28, 1889	Excision of breast.	.....	Had recurrence 10 years later which was excised May, 1899. Had recurrence 1 year later. Took *x*-ray treatments until October, 1903, when she became bedfast and died a short time afterward.

Digitized by Google

END RESULTS FOLLOWING OPERATIONS FOR CARCINOMA OF THE BREAST.

By NATHAN JACOBSON, M.D.,
SYRACUSE, N. Y.

In discussing the results to be obtained from operation upon carcinoma of the breast there are various factors to be carefully weighed. Considering these in their natural order, we should first be concerned with the period of duration of the disease and the rapidity of its progress; next, with the extent of the involvement of the various structures and the character of the carcinoma; and, finally, with the radical nature of the operation performed for its removal.

It is not always possible to determine the period of duration of the disease. Inasmuch as in its early stages carcinoma is entirely devoid of pain, it is frequently a matter of accident that the tumor is discovered. In one of my cases the patient dreamed that she had a tumor of the breast, and the next morning, on awakening, was startled to find, on placing her hand upon the gland, that a tumor was present.

The rapidity with which the disease progresses is of paramount importance. I think that it will be conceded without dispute that there is as much difference in the virulence of cases of carcinoma as there is in acute infectious fevers. In some instances of the latter the fever will progress so mildly as to scarcely disturb the patient, while in other instances it will overwhelm the individual with such fury as to be fatal within twenty-four hours. Acute cases can be of scirrhous as well as medullary character.

October 9, 1901, a woman, aged forty-one years, the mother of

Digitized by Google

two children, both of whom she had nursed, and, never having had any disturbance of the breasts because of lactation, presented herself for examination. Ten days before she had discovered a hardness in the right mammary gland. I found a tumor the size of a hen's egg in the right breast, occupying the outer upper quadrant, freely movable and non-adherent. In the axilla there were many glandular masses which were hard and somewhat fixed to the skin. It did not seem possible that this condition could have been of but ten days' duration. At the operation not only the skin covering the mammary gland, but that of the axilla, was freely removed, as well as the axillary contents and both pectoral muscles. The axillary mass was found to be larger than the primary growth. She made a rather slow recovery, inasmuch as it was impossible to cover the entire surface at the operation, and some of the healing, therefore, was by granulation. A recurrence in the axilla was discovered January 17, 1902. This was removed five days later by operation. Union this time was by first intention. February 7, 1902, that is, a little more than two weeks after her second operation, she began to suffer from pains in the abdomen, chest, and back. Early in March twitching occurred in both lower extremities. On March 11 there was complete paralysis of sensation and motion below the level of the seventh dorsal vertebra. The patient died April 23, 1902, namely, within six months of the first evidence of the disease. Microscopic examination of the tumor showed it to be a scirrhous carcinoma.

Another equally virulent scirrhous cancer occurred in a woman, aged fifty-two years, operated upon November 18, 1899. She had known of the presence of the growth but two days, and yet, upon examination, the entire gland was found to be implicated, the skin adherent, the nipple retracted, and the corresponding axillary glands palpable. A very wide excision of all of the diseased area, including the skin, mammary gland, pectoral muscles, and the axillary contents, was performed. The patient made a rapid recovery, the wound healing by first intention. She left the hospital on the sixteenth day after operation, in good general condition. Three months later there was not only recurrence in the scar at

Digitized by Google

the junction of the middle and lower thirds, but over the entire chest and on the back small shot-like nodules were to be felt, as well as nodes in the supraclavicular spaces. Similar nodules appeared in various parts of the body, rapidly increased in size as well as number; the cachexia grew profound, and the patient succumbed to the disease in August, 1900.

In this class of cases it matters little what operation is selected, or how early it may be performed; the evident virulence of the infection renders a permanent cure impossible. As far as I am aware, there is nothing which either the surgeon or the pathologist can discover at the time of operation which will make it possible for him to determine the degree of malignancy of the affection, aside from the rapid course the disease has pursued up to the time of operation.

There is another class of cases which show their tenacity and the patient's susceptibility to carcinoma by repeated outbreaks in different parts of the body.

On June 19, 1895, I curetted the uterus of a woman forty years of age, and found carcinomatous disease of the fundus. Not until the next spring did she consent to hysterectomy. In May, 1898, she discovered a tumor in the depth of her right breast. Amputation of the gland was not permitted until September 18, 1898. The tumor, about 1½ inches in diameter, did not involve the skin, and was quite movable. There were numerous glands to be felt in the axilla, and after removal of the breast the pectoral muscles, subpectoral and axillary glands, the patient apparently made a very good recovery. Glandular metastases, discovered in the posterior triangle of her neck on the right side and in the axilla, in January, 1900, were again removed. On June 7, 1900, there was a recurrent nodule in the scar tissue on the chest, and this was cut out. She remained well until January, 1902, when there was another recurrence in the cicatrix and involvement of the supraclavicular glands of the opposite side of the neck. In removing them I followed the chain down until I found it to be continuous with the glands in the mediastinum. From this time on she suffered greatly from dyspnea, laryngeal stridor, and a racking cough.

Digitized by Google

There was implication of the left recurrent laryngeal nerve. In December, 1902, orthopnea was marked. She died January 9, 1903, fully eight years after the first evidence of carcinomatous disease.

On March 10, 1897, I performed hysterectomy for carcinoma of the uterus on a woman, aged thirty-nine years, from which she made a very satisfactory recovery. September 23, 1899, she presented herself to me with a hard tumor in the lower outer quadrant of the left breast, associated with enlarged axillary glands. The entire breast, with its overlying skin, the axillary glands, and the pectoralis major were removed. She had no recurrence of the carcinomatous disease, either in the breast or pelvis, but developed cancer of the stomach, from which she died January 2, 1901.

In still another case, I amputated the right breast in March, 1891, and, without evidence of any local recurrence, she returned to me in June, 1892, with a similar disease of the left breast. This was likewise amputated. In January, 1895, a spinal metastasis occurred, and the patient gradually became paralyzed in both upper and lower extremities, and died of the spinal recurrence December 21, 1895.

This group of cases, in which carcinoma manifests itself in different organs of the body, and in which the new outbreak of the disease occurs without return at the primary site, indicates that, in a certain class of cases, we cannot lose sight of the personal equation, as, evidently, some individuals possess a pronounced susceptibility to cancerous disease.

That advanced age is not a matter of great import in determining the prognosis is evident in the following two cases:

The first was a woman, aged eighty years, who had known of the presence of the tumor for two weeks. Radical operation was performed on June 30, 1904. The axillary space was thoroughly cleared out, the pectoralis major was removed, and in just two weeks' time she left the hospital, primary union having followed operation. She died one year later of conditions incident to her vascular condition and without recurrence of the cancer. The pathologist's report in this case was scirrhous carcinoma.

In the second case I operated upon a woman, seventy-eight years

Digitized by Google

of age, who had been aware of the presence of the tumor but ten days. Here, also, there was well-advanced atheromatous degeneration. She did not die until five years after operationn, when her death was caused by apoplexy. At the time of operation the patient was already suffering from cerebral changes incident to the vascular disease. She complained of tingling and numbness of her extremities, and suffered from dizziness and aphasia. Ten months after operation there was a slight recurrence in the scar. This was treated by the application of a caustic paste, which removed the diseased part. In the course of six weeks it had entirely healed. The patient had no subsequent recurrence.

This is the only instance in which I did not use the knife for the removal of the recurrent growth.

On the contrary, I embodied in a paper, read before the Medical Society of the State of New York at its annual meeting in 1896, some statistics obtained from a gentleman whose wife was treated at a so-called cancer-cure institution by means of caustic applications. Among those receiving the same treatment in this institution were fifteen patients with carcinoma of the breast. The end result of the treatment was obtained in each case. In no instance was there any benefit, but each and every one died after months of torture of the cancerous affliction.

I had occasion to operate upon a religious sister in May, 1890, for carcinoma of the breast of one year's duration, during which period she had been treated by a self-styled cancer specialist with caustic plasters, only to produce a sloughing condition of the breast. A prompt recovery followed removal of the breast, the axillary contents, and part of the pectoralis major. A letter, received from her physician, Dr. Hancock, of Jeffersonville, Ind., April 22, 1907, *i. e.*, seventeen years later, reports her to be in good health, with no recurrence of cancer.

There can be no doubt that the removal of recurrent growths may be followed by lasting cures.

A patient was operated upon by me August 24, 1896, for scirrhus of the right breast of some months' existence. There were marked glandular metastases in the axilla. Local recurrence in the

Digitized by Google

scar tissue and neighboring glands appeared twenty-one months later. The recurrent growths were removed by operation May 18, 1898, and since then the patient has had no return, has enjoyed perfect health, and has the full use of her arm.

Whether sex is a factor to be considered in the ultimate prognosis of malignant disease of the breast I am unable to say. I have had but 3 cases of malignant tumor of the male breast, each of them recurring, and in the end causing death.

I have been greatly disappointed in my efforts to obtain information in regard to many of the patients upon whom I have operated. Of 71 of these cases reported upon and which were operated more than three years ago, 35 are still living, 33 died of metastases, and 3 within a year after operation of other diseases.

As has been stated, some of the most acute recurrences have been in cases of the scirrhous type.

In our pathological studies some attention has been given to investigation as to the presence of mitotic figures, to determine whether evidence of active cell division implied the probability of early recurrence. This has not been found to be the case. For example, in one specimen of scirrhous mitotic figures were found to be rare in the breast tumor, but numerous in the lymph nodes. There was evidence of spinal metastasis eight months after operation, death occurring two months later. In another, scirrhous carcinoma of a breast removed May 27, 1903, mitotic figures were very abundant, but the patient is at present in the full enjoyment of health, having never had the slightest recurrence.

During the past ten years I have employed the incision suggested by Dr. Halsted and have followed his technique, except as to the removal of the supraclavicular glands in all cases. The latter step has only been undertaken when there has been apparent invasion of the neck. The axillary space has been thoroughly cleaned out, the pectoralis major and sometimes the pectoralis minor have been removed. After making the skin incision, the axillary space is first cleared and an attempt made to remove everything en masse. The great advantage of being able to see the field of operation clearly at every step of the operation cannot be too highly appreciated.

Digitized by Google

For the past two years, when it has been possible to do so, the patients have been given weekly *x*-ray treatments for at least three months after their recovery from the operation.

During the decade preceding the last ten years I was guided by the principles enunciated by the late Samuel W. Gross, in the paper presented to this Association at its meeting in 1881. A circular incision was made around the breast and extended into the axilla. The axillary fat, with the glands buried in its substance, was removed, together with the upper layer of the pectoralis major. In cleaning the axilla by this method one had to depend largely upon the sense of touch, and hence there was always a degree of uncertainty as to whether all invaded structures were thoroughly removed. That this result was obtained in many instances, however, there can be no doubt.

In 1890 I operated upon three religious sisters—one in May, another in June, and still another in November. In only one of these cases has there been a recurrence. This was in March, 1906, namely, sixteen years after operation, when there appeared in the abdomen numerous nodules, presumably involving the various abdominal viscera. They were hard and fixed. She died September 2, 1906. No autopsy was permitted.

This brings up the question of what we are to consider a cure. I think it must be conceded that the three-year limit usually put upon these cases is altogether too short to determine the end result. While in most instances a patient remaining entirely well for three years is quite apt not to suffer from further recurrence, the exceptions to this rule are by no means rare.

A woman, operated upon by me December 19, 1888, when in her thirty-seventh year, and in whom a scirrhous carcinoma of the breast had been present for about a year, showed no further signs of malignant disease until the spring of 1901. She died on June 17, 1901, of malignant invasion of the liver, the autopsy showing this organ to have been converted into a mass of malignant nodules of varying size, from a pin-head to that of a large marble. All of the other organs seemed to be free from malignancy.

Withal, however, as we review the results of operative pro-

Digitized by Google

cedures undertaken for carcinoma of the breast, we can warrant the assertion that the present operative technique, developed as it has been along the lines of pathological research, has fully verified our expectations and justified the statement that except in the very acute cases a timely operation radically performed will completely remove the carcinomatous disease and prevent recurrence in the majority of cases.

Digitized by Google

THE END RESULTS IN OPERATIONS FOR CARCINOMA OF THE BREAST.

By JOHN CHADWICK OLIVER, M.D.,
CINCINNATI.

I HAVE assumed in preparing this article that one is expected to confine his observations to patients upon whom he has operated and to give the results of his personal experience. It has been utterly impossible for me to obtain "the end results" in such a large number of cases operated upon in the charity wards of the hospitals that it seems necessary to omit any reference to patients who could not be followed after they left the hospital. I have, therefore, omitted from consideration all patients except those private ones whose subsequent histories could be accurately obtained either from personal observation, or by correspondence with their family physicians. One cannot present a complete list of this class of cases either because some of the patients have removed to new localities, or the physician who referred the patients to me may have died or removed from his original location.

The histories of the patients herewith reported are complete up to April 1, 1907, and I am sure that each statement is based upon authentic information. A tabulated statement is appended for convenience of reference. No case is reported which has not passed the three-year limit or has died before the expiration of that period of time. It is possible that the statistics herewith given are somewhat better than has been the average in my work. I believe this to be true, because the patients grouped in this report represent the more intelligent class of people, as well as those best able to care for themselves.

The complete histories of 35 patients with carcinoma of the

Digitized by Google

breast are presented herewith. Twenty-two, or 62.85 per cent., are dead from recurrence of the disease, while 12 are alive and well from three to ten and one-half years after operation (34, or 0.28 per cent.). One is alive after more than three years, but she is at present afflicted with an inoperable recurrence, to which she will undoubtedly succumb in the near future.

The radical operation, with removal of both pectoral muscles, but without cleaning out of the supraclavicular region, was performed thirty times. The breast was removed and the axilla cleared out without removal of the pectoral muscles seven times. (The two additional operations are accounted for by the fact that the remaining breast became involved in two patients, and these were subsequently removed.) Ten of the 30 patients upon whom the radical operation was done have recovered (33⅓ per cent.), while 4 of the 7 upon whom the simpler operation was done are now alive and well (57.15 per cent.). These figures are misleading, because in two instances a simple operation was done upon the remaining breasts after radical operations had been done upon the opposite breasts. It is rather remarkable that both of these patients recovered and have remained well—one seven and one-half years and the other five and one-half years after removal of the second breast.

These statistics seem to prove that recurrences and deaths from carcinoma of the breast are unusual after the patient has remained well for three years after the operation. In but three of the cases has death from carcinoma occurred after three years; these lived respectively five, four, and three and one-half years.

Three patients developed recurrences or metastases after three years; these appeared four and three-quarters, three and one-half, and three and one-half years after operation. One of these cases is alive and well one year after the removal of a local recurrent growth. The author has met with one fatal recurrence in the axilla fourteen years after the breast had been removed.

These very late recurrences open up the question as to what should be called a recurrence and what should be regarded as a new development of carcinoma. A discussion of this question is not in order under the present circumstances because all such devel-

Digitized by Google

opments must be regarded as recurrences so far as the purpose of this discussion is concerned.

Two or more operations were performed upon eight of the thirty-five patients, the secondary operations having for their object the removal of local recurrences of the disease. Three of these are alive and well more than three years after the last operation.

Twenty-one of the thirty-five patients operated upon had known of the existence of a tumor in the breast for one year or longer. One patient had had a lump in her breast for upward of twenty years, but it had remained quiescent until one year preceding the operation. Another lady had known of the existence of a tumor in her breast for ten years, but there were no signs of activity until about six months before the operation. In each of these patients the tumor grew rapidly during the active period, and malignancy was well marked. Fourteen of the patients who had known of the existence of a tumor for one year or more died (66⅔ per cent.). One is alive with an inoperable recurrence, and six (28.5 per cent.) are alive and well more than three years after operation.

Eight patients knew of the existence of a tumor from six to twelve months prior to operation. Four (50 per cent.) are alive and well; four (50 per cent.) are dead.

Six had been aware of the presence of a tumor for a period of less than six months. Two (33⅓ per cent.) are alive and well; four (66⅔ per cent.) are dead.

The figures seem to indicate that one may not be able to judge of the prognosis very accurately merely by the length of time the patient has known of the presence of a tumor in the breast. It must always be borne in mind, however, that a patient's statement on this point is not apt to be very accurate. When this testimony comes from the family physician, or from members of the patient's family, it assumes much greater importance. The time given by the patient is always short of the real period of existence.

One remarkable case was that of a lady who had known of the existence of a tumor in her breast for two years. She consulted her local physician, and he removed part of the breast, the incision not being sufficiently wide of the involved tissues to prevent an

Digitized by Google

early recurrence. I made a radical operation one year later, and then removed a local recurrence nine months after the second operation. The patient is alive and well four and one-half years after the third operation. (Case 19.)

Recurrence above the clavicle took place in but two of the thirty-five cases. This was less frequent than were recurrences in the opposite breast (five cases).

Lymphedema of the arm supervened in five of the patients. Three of these died in less than three years; one is alive but with extensive recurrences, and very extreme lymphedema. (No. 30.) The swelling gradually disappeared under treatment in the remaining patient. (No. 20.)

The function of the arm is good in all of the surviving patients. None of them complain of weakness or inability to use the member.

Twenty-eight of the patients comprising the material for this report were married, seven were spinsters. Ten of the married and two of the single women recovered (36 and 28.6 per cent. respectively).

Statistics based upon this very limited number of cases indicate that the location of the primary growth has some bearing upon the prognosis. Central growths and those located in the lower third of the breast give a much larger percentage of recoveries than do growths located elsewhere.

The average duration of life after operation (in fatal cases) was twenty months. The extremes being five years and five months.

The average time of recurrence was fourteen and one-quarter months—the extremes being fifty-six and three months.

An estimation, such as the above, based upon the mere existence of cancer of the breast without any consideration of the actual conditions present at the time of operation will give a very fair idea of the average results obtainable in the general run of cases, without any elimination of cases unsusceptible of cure through operative measures. One may, however, in fairness exclude from these statistics those cases in which operation was simply undertaken as a palliative measure, and thus obtain a better idea of what results may be accomplished in cases more carefully selected. This

Digitized by Google

more careful discrimination is only possible through more thorough education of physicians and of the general public. Fourteen of the thirty-five cases in this report were beyond the possibility of cure through operation, and in each of these cases operation was undertaken with the hope of prolonging life or to remove offensive, ulcerated breasts. If we subtract these fourteen cases and estimate our mortality upon those in which there was a reasonable hope of success we then have twenty-one patients, twelve of whom recovered—a percentage of recovery of about 57.6.

The matter of prognosis in an individual case will always remain a doubtful one, even though the surgeon has had a very considerable experience with this class of cases. Seemingly favorable cases sometimes progress to a fatal termination, whereas one is sometimes pleasantly surprised by having an unpromising case go on to recovery.

The most potent factor bearing upon prognosis is the character of the growth. The richly cellular, rapidly growing, soft, succulent carcinomata are much less amenable to surgical treatment, even when seen early in the course of the disease, than are the more fibrous, slow growing, hard varieties of the disease. A successful outcome is not probable in the former variety unless operation is undertaken early, because secondary foci of development are planted soon after the primary growth makes its appearance.

One is justified in looking upon the operative treatment of cancer of the breast as being far from an ideal method of treatment, even with the extensive removals practised at the present time. The hope for the future lies in better prophylaxis and in a better knowledge of the nature of the disease.

Digitized by Google

	Time between discovery and operation.	Breast affected	Segment of breast involved.	Rapidity of growth.	Glandular involvement at time of operation.	Time of recurrence.	Sites of recurrence.	Time between operation and death.	Alive.
1. Mrs. B. . .	15 months.	Right.	Upper, outer.	Slow.	Extensive.	6 months.	Axillary glands op. breast skin.	2 years, 2 mths.	
2. Miss S. . .	1 year.	Right.	Whole breast.	Rapid.	Very extensive.	3 months.	Axilla and stomach.	6 months.	
3. Mrs. F. . .	3 months.	Right.	Upper, outer.	Rapid.	Extensive.	3 months.	Local and neck.	2 years.	
4. Mrs. D. . .	1 year.	Rigbt.	Upper, outer.	Slow, 10 months, rapid 2 mths.	Extensive.	3½ months.	Axilla, liver, and pleura.	4 months.	
5. Mrs. A. . .	1 year.	Left.	Upper, inner.	Rapid.	Slight.	9 months.	Local and spine.	11 months.	
6. Mrs. B. . .	3 years.	Right.	Upper, outer.	Slow.	Extensive.	4 weeks.	Brain.	5 weeks.	
7. Mrs. B. . .	6 weeks.	Right.	Upper, inner.	Very rapid.	Extensive.	6 months.	Liver and stomach.	14 months.	
8. Mrs. C. . .	20 years, active 1 year.	Left.	Upper.	Very slow, then rapid.	Well marked	1½ years.	Liver.	21 months.	
9. Mrs. K. . .	6 months.	Right.	Lower, middle.	Rapid.	Well marked.	14 months.	Axillary glands.	.....	Well 10½ years.
10. Mrs. V. . .	1 year.	Right.	Lower, middle.	Slow.	None.	...	.....	.....	Well 10 years.
11. Miss K. . .	1 year.	Right.	Outer, middle.	Slow.	Well marked.	13 months.	Opposite breast.	.....	8½ after first, 7 after second operation.
12. Mrs. R. . .	9 months.	Right.	Outer, middle.	Medium.	Well marked.	18 months.	Abdominal viscera.	22 months.	
13. Mrs. P. . .	3 months	Left.	Upper, outer.	Rapid.	Very extensive.	1 year.	Spine.	18 months.	
14. Mrs. P. . .	6 months.	Right.	Upper, outer.	Rapid.	Slight.	2 years.	Scalp.	3½ years.	
15. Mrs. W. . .	5 weeks.	Right.	Lower, middle.	Rapid.	Well marked.	¾ years.	Chest.	5 years.	
16. Mrs. M. . .	6 months.	...	.....	Rapid.	Slight.	3½ years.	.....	4 years.	
17. Mrs. G. . .	18 months.	Right.	Central.	Slow.	Slight.	4¾ years.	Local.	.....	Well 6 years.
18. Mrs. T. . .	2 years.	Right.	Lower, inner.	Slow.	Very extensive.	6 months.	Stomach.	6 months.	
19. Mrs. H. . .	2 years.	Right.	.....	Slow.	Well marked.	Incomplete removal.	Axilla.	.....	Well 4 years 8 mths.
20. Mrs. W. . .	4 months.	Right.	Upper, outer.	Rapid.	Absent.	None.	.....	.....	Well 5 years.
21. Miss F. . .	1 year.	Right.	Upper, outer.	Rapid.	Very extensive.	1½ years.	Liver, kidney, left breast.	2 years.	
22. Mrs. De C. .	3 months.	Right.	Lower, outer.	Rapid.	Slight.	...	.....	.....	Well 3½ years.
23. Mrs. B. . .	3 years.	Right.	Upper, outer.	Slow.	Well marked.	3 months.	Local and lung.	1 year.	
24. Mrs. B. . .	8 months.	Right.	Upper, outer.	Rapid.	Extensive.	...	.....		Well 3½ years.
25. Miss H. . .	1 year.	Left.	Whole gland.	Rapid.	Very extensive.	9 months.	Not known.	15 months.	
26. Miss S. . .	2 years.	Right.	Whole gland.	Slow.	Slight.	...	.....	.....	Well 3 years 1 mth.
27. Mrs. P. . .	15 months.	Left.	Whole gland.	Medium.	Very extensive.	5 months.	Not known.	9 months.	
28. Mrs. W. . .	5 months.	Left.	Whole gland.	Rapid.	Slight.	...	.....	.....	Well 3 years.
29. Mrs. R. . .	6 months.	Right.	Lower, outer.	Rapid.	Slight.	...	.....	.....	Well.
30. Mrs. S. . .	8–10 months.	Right.	Lower, outer.	Rapid.	Very extensive.	4 months.	Lung, skin local.	7 months.	
31. Mrs. McN. .	10 years, active 1 year.	Left.	Lower, inner.	Slow.	Very extensive.	1½ years.	Above clavicle.	.....	With recurrence.
32. Miss F. . .	1 year.	Right.	Whole gland.	Very rapid.	Very extensive.	4 months.	Local lung, other breast.	7 months.	
33. Mrs. K. . .	1 year.	Right.	Middle, outer.	Rapid.	Well marked.	8 months.	Spine.	1 year, 8 mths.	
34. Miss M. . .	1½ years.	Right.	Upper, outer.	Rapid.	Slight.	4 months.	Opposite breast, stomach.	1½ years.	
35. Mrs. W. . .	1 month.	Both.	Lower, outer (L.). Middle, outer (R.).	Rapid.	Marked on left side.	...	.....	.....	Well 5½ years.

Digitized by Google

END RESULTS IN OPERATIONS FOR CANCER OF THE BREAST.

By A. F. JONAS,
OMAHA, NEBRASKA.

Of all cancers found in women, the breast, next to the uterus, is the most frequent seat; and of the total number of cancers in men and women, it occupies third place—the uterus and stomach are the only organs more frequently affected. The breast seems to occupy a very important relation to the genital apparatus. Its development to its full function is combined with a growth of connective tissue, bloodvessels and lymphvessels, and no other organ is exposed to such frequent nutritive changes and functions as the mammary gland. Added to this, the breast is subjected to constant developmental changes, often of a retrograde character. These facts may, in a measure, have something to do with the origin of cancer, because mamma carcinoma is unknown before puberty. The frequency of breast tumors seems to occupy a direct relationship to the genital organs.

It has been shown that 80 to 86 per cent. of all breast tumors are carcinomata, and that has been the writer's experience, as will be shown by the appended table.

Carcinoma is nothing more nor less than a proliferation of epithelial cells that have extended beyond physiological limits, and have destroyed normal organic tissues. The malignancy of a carcinoma is dependent upon this advance of new-formed epithelial masses beyond normal bounds.

From a practical standpoint, we may divide carcinoma into two general groups, namely, *soft growths*, which are made up of a large cell proliferation, and *hard growths*, in which there are few cells and much connective tissue.

Digitized by Google

While it is intended at this time to discuss only epithelial growths, the author has taken the liberty of introducing all the neoplasms of the breast that have come under his treatment, in order that the relative proportion of epithelial and non-epithelial growths may be shown. A considerable number of both operable and inoperable growths that were seen only in the consultation-room, which did not return for treatment, are not included here.

The total number of neoplasms of the female breast that have come under the writer's observation, which were operated during twenty years, and of which it has been possible to obtain more or less complete data, comprise a list of 260 cases. These cases have been classified according to their histological component parts, and may be divided into the following groups:

Fibro-adenoma	31
Adenoma	2
Myxo-angioma	1
Cystoma	2
Lipoma	5
Atheroma	1
Sarcoma	7
Carcinoma	211

It will be seen from the above table that the non-epithelial growths comprise 18.5 per cent. of the total number and that 81.5 per cent. are of epithelial origin. The latter form that large group known as carcinoma or cancer, and have been subdivided according to their microscopic findings, as follows:

Acinous carcinoma	105
Tubular carcinoma	75
Scirrhous carcinoma	25
Colloid carcinoma	6

In briefly detailing our experience we have followed the above classification, and we find:

1. Acinous carcinoma forms partly soft and partly hard nodules; usually, however, they comprise the soft cancer, and in its most dangerous forms they are of the medullary variety. The more or less firm stroma is filled with round cells, and the carcinoma proliferation is found to be composed of epithelial cell masses, which

Digitized by Google

form large, irregular, acinous-like groups. In their interior, early degenerative changes occur, which lead to softening and early ulcerative changes, forming crater-like ulcers. From these craters proliferate sponge-like granulations, which soon melt down. Under this head there came to operation at our hand 105 cases.

2. The tubular carcinoma is characterized by a growth of epithelial masses in the form of elongated, branched cylinders which very soon extend beyond the bounds of the original acini, rapidly producing an acinous confluence. It spreads superficially and infiltrates the neighboring tissues. The cell nests are long and tubular. The connective-tissue cell infiltration progresses at the same rate. As the growth progresses, neighboring tissues are invaded, namely, skin, adipose tissues, muscles, ribs, pleura, and axillary glands, which is shown by more or less numerous carcinomatous nodules in all these tissues. Sometimes the skin of the breast and back and arm may become infiltrated with carcinomatous nodules so extensive as to form a hard, thickened, uniform, board-like mass, extending from sternum to spine, known as cancer en cuirasse.

With tubular carcinoma, cell degeneration is slower, and takes place much later than in the acinous form. The softened cellular material is absorbed and eliminated by lymphatics and veins, and the remaining connective-tissue contracts, forming the interstitial cicatrix which is manifest by the retracted nipple. Of the tubular carcinoma form our list contains 75 cases that were operated.

3. The scirrhous. The atrophic cancer is known by its slow growth, the disappearance of carcinomatous cells, and a resultant cicatricial connective-tissue contraction. The connective tissue preponderates, and the epithelial nests are small and sparsely distributed. Of this variety 25 cases were removed by operation.

4. The colloid cancer is rare, only two cases appearing in our tables. Such cancer masses, when incised, present mucoid, jelly-like transparent masses, embedded in a connective-tissue stroma. According to Lange, the colloid masses are formed of a mucoid softening of connective tissues, surrounding the cancer masses, and with this mucoid degeneration occurs a simultaneous destruction

Digitized by Google

of cancer cells and their disappearance. Colloid cancers grow slowly, and of all forms offer the best prognosis.

No cases of carcinomata or other growths have been included in the above list, prior to twenty years ago, because all the writer's cases, operated before that time, were treated by a removal of the primary nodule or the entire breast, without a systematic removal of the axillary contents. Our knowledge of the pathology of breast neoplasms, and especially the early and widespread carcinomatous dissemination to axilla and frequently to the supraclavicular triangle, has become so well-founded that no modern surgeon would have the temerity to stop short of a complete removal of the entire breast and axillary contents in the very early cases, and in later ones remove, in addition, both pectoral muscles and the fat from the supraclavicular triangle.

All of our operations, as tabulated above, have been done in this radical way, and in a number of instances portions of one or several ribs were removed wherever there was the slightest indication of the neoplasm having approached a rib. There were 30 secondary operations of our own cases which have not been included in the above list. Nor does this table comprise 14 other secondary operations, in cases done primarily by other surgeons. Of our own 30 secondary operations, 15 cases underwent a third operation; 5 were subjected to a fourth operation; and 1, to 5 operations—all of these for local recurrences. All of the writer's cases were cautioned to return immediately when the least suspicion of a recurrence should take place.

Briefly we may say that our operative experience comprises 211 primary operations for cancer of the breast; 30 operations for local recurrences in our own cases; and 14 cases done primarily by other operators—totaling in all, 55 cases. Out of this number there were six deaths.

Deaths. Two cases died from sepsis; 1 case, secondary operation, where the breast only had been removed by another operator. The axillary and supraclavicular involvement was extensive. The axilla was completely cleaned out, and the supraclavicular extirpation was almost complete, save for a node that was adherent to the subclavian vein; while under the gentlest possible manipula-

Digitized by Google

tion the blunt dissector punctured the vein, allowing the entrance of a large quantity of air. The heart beat immediately increased to 160 per minute. The opening in the vien was immediately grasped between the two fingers; it was accurately closed with a running silk suture. The heart rate, however, did not improve, and she died in twenty-four hours. Another case died from an overdose of chloral hydrate, self-administered.

The last case died from secondary hemorrhage on the thirteenth day. During the operation the axillary vein was completely torn across on account of carcinomatous involvement. Suturing was out of the question, so both ends were ligated, which can be done without fear of permanent circulatory disturbance, because the collateral circulation takes place through the cephalic vein.

Accidents. The axillary vein was completely torn in two cases. One recovered without untoward symptoms. The other died from secondary hemorrhage. The left subclavian vein was punctured once, admitting a quantity of air; the patient succumbed twenty-four hours later.

Of the twelve cases in which one or more ribs were resected, for the removal of deep-seated carcinoma, the pleura was punctured five times. Once only did the condition following seem alarming. The patient went into collapse with a pulse rate of 140, the latter remaining so for several days; recovery, however, eventually took place. The axillary and subclavian arteries were never wounded. The important nerve trunks of the axillary plexus never were divided in any of our cases.

End Results. We now come to the most difficult part of our theme, "the end results." The author has tried for many years to maintain a correspondence with his patients, not only in the class of cases under consideration, but in other classes of patients as well, but his efforts have been feebly rewarded. In many of his breast cases it has been possible to follow them for a year or two, and many until they had reached the usual time limit of three years—many cases having passed the period when a cure was considered permanent, namely, three years. A systematic correspondence was attempted, but the responses to inquiries were not numerous, so that the information gained was largely by personal

Digitized by Google

interviews, inquiries, through friends, and relatives. Many of the patients had disappeared from their former places of residence and no trace could be found of them.

PRIMARY OPERATIONS FOR CARCINOMA.

	Total.	Disappeared.	Considered here.	Recurred in 1 year.	Recurred in 2 years.	Free after 3 years.
Acinous	105	21	84	25	19	40
Tubular	75	10	65	12	8	45
Scirrhous	25	1	24	1	5	18
Colloid	6	2	4	0	2	2
Total	211	34	177	38	34	105

Secondary operations for recurrence, own cases 30.
Secondary operations for recurrence, other surgeons' cases 14.

The final outcome of the secondary operation is not known in most of the cases, consequently it is impossible to even approximately estimate the final results.

From the above table it will be seen that out of a total number of 211 primary operations, 34 cases could not be found, and their fate is unknown to the writer; consequently they must be left out of consideration entirely. This leaves 177 cases whose condition was known up to and beyond three years after operations. It will be noted that there were 38 recurrences in one year and 34 the second year, leaving 105 cases without recurrence at the end of three years—about 56.7 per cent.

Now this does not indicate the real percentage of permanent recoveries. Among our cases that came to operation for recurrence there was one case operated by another surgeon that had remained free for fifteen years; another case had apparently been well for ten years; another for eight years; and another for five years.

In our series the larger number of recurrences were found among the earlier operations, and a smaller number among those operated in more recent times. This is due no doubt to two factors: the first, that at the present time every lump in a woman's breast is regarded with suspicion, and an immediate radical operation is advised; consequently, a larger number come to operation early—before extensive secondary involvement occurs. And, secondly,

Digitized by Google

radical operation, which means removal of the entire breast, together with the axillary contents in *all* cases, and also where axillary involvement can be demonstrated on opening the axillary space of the pectoral muscles.

The fate of all the recurring cases can be briefly stated. They finally all ended fatally. An attempt was made to ascertain the exact locality of the recurrence, the progress, later involvements, complications, metastases, and swelling of the arm, due to vascular involvement. But the available data were so meagre as to be of no value; therefore, this phase of our subject cannot be discussed here.

The functional results, so far as the movements of the arm are concerned, on the whole were good. In our earlier cases, where the incision was made along the lower border of the pectoralis major, the resulting scar sometimes caused a limitation of outward and upward movements of the arm. In our later cases a modified curvilinear incision (E. Senn) was made, the curve reaching almost to the clavicle. This method seemed to eliminate limitation of movement due to scar contraction. However, some motor restriction seemed to be due to subcutaneous cicatricial contraction in the axilla. This seemed to be due to a partial distention of the axilla by serum and blood, in spite of methodical tubular drainage. This complication, in part at least, was overcome by stitching the middle portion of the axillary flap up high against the chest wall, in accordance with a suggestion of Miles Porter, of Fort Wayne, Indiana. This prevents the formation of a dead space in which fluids can collect. The loss of function from a removal of both pectoral muscles was insignificant. In one or two years there seemed no marked restriction of motion on this account.

A more or less severe postoperative swelling of the arm occurred in a number of instances, owing, no doubt, to a removal of all the axillary lymphatics. This swelling usually disappeared in a few weeks, as soon as a collateral lymphatic circulation had been established. There is no question that there will be a constant improvement in the end results, because there is a growing unanimity of the profession and laity regarding the necessity of an early and a radical operation.

Digitized by Google

VERY LATE RECURRENCES AFTER OPERATION FOR CARCINOMA OF THE BREAST.

By JOSEPH RANSOHOFF, M.D., F.R.C.S.,
CINCINNATI.

WHEN Volkman, more than twenty-five years ago, established the triennium as the time limit for recurrence after operations for cancer, it was with the knowledge that it may return at a later period. Investigations have recently been made, especially on the Continent, by Labhardt, Koenig, Pulsen, Schroeder, and Wunderli, of the subsequent history of cases that have passed the three-year limit. Their facilities for such investigations have been unusual by reason of the registration laws which, through official sources, permit the following up of cases to the very end. From these investigations it will appear that of those who have safely passed the three-year limit about 20 per cent. succumb later to recurrence in loco or to visceral, bone, or gland metastases. It would seem, therefore, that before a permanent cure can be said to have been obtained an immune period of five or six years must have been passed. But, as we shall see later, even long after this time, local glandular or visceral metastases may appear.

The mortality of even very extensive breast operations has been steadily reduced, until now they can hardly be classed with the major operations. Synchronously the number of patients who remain well after three years or more has increased. The average of patients who pass the three-year limit, in the hands of most surgeons who perform radical operations, is but a little under 30 per cent. A three-year cure of over 40 per cent. is certainly exceptional unless conservatism is manifested in the selection of cases deemed suitable for radical operation. The age of the patient, the degree

Digitized by Google

of glandular involvement, the size and rapidity of the tumor growth, and, above all, its wealth in cell elements will greatly affect the prognosis as to recurrence. Experience has taught us in the individual case to foretell, with reasonable accuracy, how lasting the relief afforded by operation may be.

It is altogether probable that a fair part of the improved end results, latterly achieved, is due to the fact that the public has for over twenty years been educated to the importance of early interference in breast cancer. It is now exceptional in the experience of anyone to encounter an ulcerated or even adherent mammary cancer, and a primary inoperable case in well-settled communities is indeed a rara avis. In advanced cases, the postoperative prognosis is still extremely bad. Of ulcerated breast cancers, Wunderli reports only two living after three years.

To ascribe the improved results altogether to the radical end of the operation I believe to be fallacious. My first case of breast amputation is still living and well after twenty-nine years, and I have two living and well operated on twenty-six and twenty-two years ago, respectively. In the last of these, a very severe wound, erysipelas threatened the life of the patient. It goes without saying that in each of these cases the pathological diagnosis of cancer was made. In none of them was more than an amputation with incomplete evacuation of the axilla done.

This is not in any way to be construed as advocating recession from the practice of widest possible excision now in vogue by almost everyone, but as some basis for hope even in those exceptional cases in which, for one reason or another, a very extensive operation is contra-indicated. On the contrary, the radical operation of today, if properly done, reduces considerably the danger of local recurrence, although it, of course, in no way can effect metastases already existing. How long these metastases may lie dormant will be seen later. The danger of the modern operation is in the inoculation of the wound by the needless manipulation of the tumor mass by an inexperienced or clumsy operator. Almost everyone who does surgery at all feels himself competent to do a breast operation, which to do properly, in my judg-

Digitized by Google

ment, is one of the difficult feats of surgery. I believe that I have seen relatively more cancers en cuirasse follow speedily after the radical than the older methods of operation. I also believe that if surgeons would more generally clean out the axilla as the first step of the operation the results would be better, although I have no statistics upon which to base this view.

However much wide excisions have reduced the probability of local recurrence, this will always continue to be an obstacle in the way of getting much better results. From the statistics of seven German clinics, where it was possible to follow the cases, I have figured out that local recurrence takes place in about 58 per cent. of the cases and that of these, again in 62 per cent., the recurrence appears during the first year; in 11 per cent. in the second year, and only in 5 per cent. in the third year. In these percentages are included metastases in the axillary and cervical lymphatics which form but a small proportion of the total number of cases. The great preponderance of recurrences takes place in the scar or in the skin in its immediate vicinity. These facts, clearly elementary in character, are only mentioned as a predicate to the statement that after the third year freedom from local recurrence, although not assured, may at least be confidently hoped for.

Recurrences after this time become less and less frequent. Of 20 cases collected by Markgraff, 12 took place in the third and fourth years, 4 in the fifth and sixth years, 2 in the seventh or eighth years, and 2 in the ninth and eleventh years. Of 17 recurrences from the clinic at Rostock 5 took place in the fourth year, 4 in the fifth, 3 in the sixth, 3 in the seventh, and 1 each in the eleventh and thirteenth years. The latter seems to me a doubtful case, since without local recurrence the cancer developed in the inguinal glands and the patient succumbed to abdominal metastases.

In the preparation of this paper I have had communications from sixty-two Fellows of the Association with mention of 37 cases of recurrence after six years. No less than eighteen of my colleagues in the Association who responded had not seen or did not recollect cases which had recurred after five years. It is self-evident that

Digitized by Google

these reports fall far short of scientific accuracy, but in a general way, from the very wide experience which they reflect, they emphasize the fact that after that period recurrences are certainly unusual.

Of late recurrences, Warren, Carson, Bevan, and Senn each report a case of eight years; Shepherd 1 of nine and 1 of eleven years, the latter in the supraclavicular glands; Ochsner 1 of eleven years; Bell 1 of ten years; Bloodgood 1 of fifteen years; Moore 1 of twelve years; M. H. Richardson, 2 of seven and 1 of eight years; Vander Veer, 1 of twelve years and six months; McLaren, 1 of thirteen years, exitus of general carcinoma; Pilcher, 3 of five or six years; Coley, 1 of seventeen years; Armstrong, 1 of fifteen years; Bull, 1 in loco after eight years, and 1 of general metastases after nineteen years. Curtis has recently reported 5 cases of late carcinomatous metastases. Of 27 cases kindly abstracted for me by Harrington from his service, there was 1 dying eleven years after operation from cerebral hemorrhage without local recurrence. The patient was seventy-five. There was no reason for believing that the apoplexy was due to hemorrhage. There was no case of late recurrence.

Willy Meyer communicates a case of gastric cancer appearing six years after breast amputation without local recurrence, and Tiffany one of intestinal and omental cancer twelve years after a breast operation without local recurrence. Finney had one of cancer of the rectum seven years after the operation without local recurrence, and Jacobson communicates two cases of abdominal carcinoma developing thirteen and sixteen years after the primary operation. In neither case was there local recurrence. In the one case multiple metastases were found in the liver without any other organic abdominal disease. Halsted reports one case of cancer of the pleura developing eight years after the operation without recurrence in the scar, and Mayo, one of cancer of the other breast which developed seven years after the first operation.

My personal experience with late recurrences or metastases has been limited to a few cases. There may have been others of which I have no knowledge.

Digitized by Google

In May, 1893, the writer removed a round-cell sarcoma from the left axilla of a man seventy-three years of age. Without any local recurrence, a tumor developed on the outer side of the left arm, which I removed in May, 1907. The tumor proved to be a melanosarcoma.

Mrs. S. L., aged forty-eight years. Cancer of the right breast. Amputation with removal of axillary lymphatics in April, 1881. Continued well for four years, when symptoms of cancer of the spine developed, to which she succumbed six years after the operation.

I have seen a second case of metastatic spinal cancer in a woman of forty. The symptoms developed about eighteen months after the primary operation for breast cancer. The patient died ten months after the inception of the spinal symptoms. There was no local recurrence.

In a personal communication Da Costa mentions a case of spinal cancer which developed nine years and ten months after an operation by the younger Gross, who was a pioneer in the practice of wide excision of breast cancers. There was no local recurrence.

A doubtful case was that of Mrs. L., on whom a radical breast operation was done at the Jewish Hospital, January 1, 1897. She continued well for nearly six years, when, without local recurrence, cerebral symptoms developed. Their onset was sudden and consisted of right hemiplegia and aphasia. There was no loss of consciousness. The patient lived four months. I would exclude this from the list of metastases and consider it one of ordinary cerebral embolism were it not for the following case recently in my service at the Cincinnati Hospital:

The patient, a lad of nineteen, entered with a rapidly growing periosteal sarcoma of the upper end of the right humerus. On the day before the one set for operation the patient complained of intense headache, became comatose within twenty-four hours and died thirty hours after the onset of the cerebral symptoms. There was no paralysis of the extremities. The autopsy revealed a metastatic growth as large as an olive in the left cerebellar hemi-

Digitized by Google

sphere. A hemorrhage had broken through the growth under the pia and into the fourth ventricle. Similar pigmented metastases were found in the lung, the spleen, the kidneys, and one in the right pararenal fat.

Of cancer of both breasts I have had two cases. In one the second breast was removed four years and two months after the first operation. Recurrence ensued within a year.

The second case was that of a woman of forty-two, the mother of four children. The right breast and axillary glands were removed at her home in Peru, Ind., in June of 1887. In 1894 the left breast was removed for scirrhus. Sixteen months after this operation a cancerous growth was removed from the axilla of the side first operated upon. There has been no recurrence since, and now the patient is enjoying the best of health.

Of the appearance of carcinoma in other organs, after breast operations, I have had but one case, and even in this the later history did not come directly under my observation. It was that of a woman of forty-eight, who developed a cancer of the uterus seven and one-half years after the first operation. Her physician could not persuade her of the independent nature of the uterine cancer, and she refused operation.

A remarkable case as to the length of the interval between operation and recurrence is that of Mrs. F., whom I first saw in March, 1904. She was then sixty-three years of age. She had given birth to five children. In May, 1883, Prof. T. A. Reamy, at his private hospital, removed the right breast for carcinoma of the scirrhus type. The axillary glands were not invaded and the operation consisted of wide incision of the breast without opening the axilla. A microscopic examination confirmed the clinical diagnosis. The patient remained well until four months before her visit to me, when she observed a painless lump in the scar. The tumor grew rapidly from its first appearance.

Her condition at the first examination was one of perfect health, except for the cancer recurrence in the region of the right breast. The scar, very irregular and broad, was a little over six inches in length, and had evidently formed after healing by granulation.

Digitized by Google

Here an irregular nodular tumor of stony hardness and adherent to the muscle was found. The skin over it was purplish in spots, adherent to the mass and quite glistening. The tumor could just be covered with the palm of the hand. Except for the patient's statement, which there was no reason to question, nor by reason of her very superior intelligence, was there cause for doubting the accuracy of the observation, it did not seem possible that such rapid growth could have taken place in four months. The axillary glands were not at all involved. On April 2, 1904, at the Jewish Hospital, the entire scar, together with the tumor and the sternal part of the large pectoral muscle, was removed. By plastic operation and light skin grafting the wound was closed. The axilla was not disturbed. An examination of the specimen showed it to be a scirrhus recurring in the scar. On April 23, 1905, two recurrent nodules were removed from the site of the scar left from the second operation. Local recurrence did not take place. Death resulted on April 9, 1907, from intrathoracic cancer, which had caused intense dyspnea. There was no pleural effusion. Her physician, Dr. W. H. Kelley, informed me that ten days before her death a large mass could be felt in the region of the liver. On account of the condition of the patient no effort was made to accurately localize it. No autopsy was made.

So far as I have been enabled to glean from a rather extensive investigation of the literature, this case presents the longest interval of freedom from recurrence hitherto reported. The interval between operations was one month less than twenty-one years. In a personal communication Deaver informs me that he has knowledge of one case which had recurrence twenty years after the removal of the breast. Matas writes me that he saw a woman, seventy-six years old, who had a tumor appear in the cicatrix of an operation for breast tumor performed by another surgeon about twenty-five years before. The axillary glands, which had not been removed at the first operation, were not involved.

Tiffany speaks of a case recurring from time to time during a period of twenty-one years. The first operation was done by Sir James Paget. Death resulted from cancer en cuirasse.

Digitized by Google

The summing up of the cases communicated to me and my own shows 37 developing seven years or more after the first operation for cancer of the breast. Of these, 26 were clearly local recurrences and 11 were doubtful. Among the local recurrences I included those in which the regional lymphatics of the axilla and the neck of the thorax were involved. Perhaps even some of the abdominal recurrences, unless clearly primary, in the viscera, may be due to retro-infection of the lymphatics. Of the cancers of the other breast there were three cases. To classify these as recurrences is hardly logical. The same is true of the cases of cancer of the rectum, of the stomach, and of the uterus. With predisposition and environment unchanged a primary growth may certainly occur in any organ after many years without reference to a growth elsewhere removed years before. Late metastases without local recurrence, as in a case of Bull's, of ten years in the brain, of cancer of the spine after ten years, and of the liver after thirteen years, without local recurrence and without any recent primary growth in any other viscus, must, on the other hand, clearly be classified with the metastatic recurrences. Of clean local recurrences, ten occurred during the seventh and eighth years, two after the ninth, tenth, eleventh, twelfth, and fifteenth years, and one each at varying intervals from fifteen to twenty-five years. Even in these late recurrences the tumor growth was in the scar or its immediate vicinity, and it is worthy of record that in some of the cases of longest standing there was no axillary involvement even at the time of the recurrence. This might cast some doubt upon the nature of the growths as to cancer, although the very fact of recurrences bears out the correctness of the clinical diagnosis of the primary tumors and the pathological findings when made. Especially in those cases where the absence of axillary lymph-node involvement is noted, the suspicion of a chronic mastitis or of some form of abnormal breast involution would seem justified. But here, again, the recurrence speaks for the malignancy of the initial growth.

The explanation of these late local recurrences is largely speculative. The trend of opinion is that since, irrespective of the

Digitized by Google

length of the interval, they recur with great uniformity in the scar or the skin about it, they must result from cell deposits left at the first operation where they have remained latent. Clearly as this is opposed to our notions of the activity of the cancer cell, recent investigations, notably by Peterson, have shown that retrograde changes can take place in cancer nodules, chiefly through the agency of giant cells, and that the operation fosters this process. If, and when, this process fails recurrence ensues.

In conclusion, I am inclined to believe that all supposed very late recurrences in the scar are not such in reality, for there is one factor worthy of consideration. It is that scar tissue, with its epithelial covering and deformed glandular tissue in its vicinity, is subject to diseases of its own, and that among them cancer is not uncommon. Why should it not occur, therefore, de novo, in the scar of an old breast operation just as it occurs in the cicatrix of a healed gastric ulcer, or in that of a torn cervix?

Digitized by Google

CLINICAL EXPERIENCE WITH THE LAW OF ACCELERATING RISK IN CANCER.

By E. WYLLYS ANDREWS, M.D.,
CHICAGO.

In a former paper ("The Law of Accelerating Risk," *Annals of Surgery*, December, 1905) I tried to prove that the law of mathematics, the law of squares, applied to the speed of malignant growth. This well-known law of squares applies to many phenomenon in physics, to falling bodies, to momentum of masses, to radiant energy, etc. It is a long step from physical processes to vital ones, but in so simple a mechanical problem as the radiation of cancer cells, which appear to be able to conquer their way centrifugally into any and all tissues, it ought not to be difficult to formulate the ratio of extension, unless this is modified by certain resistance or antagonism, such as the occurrence of immunity.

The growth of cancer in the animal body is unchecked and unremitting exactly as if it were upon dead soil. We seem to see no recessions occurring from natural or acquired resistance. It is true that age predisposes to the *occurrence* of tumors, but we do not know that it influences their severity, when once acquired. In fact, malignant growths in the young and strong, when they do take place, are possibly more rapid and fatal than in the aged and feeble.

I would not deny the possibility of an immunizing therapy being discovered from animal pathology, but the clinical fact remains that, as we see cancer, it presents an unvarying front of crescent power, which beats down all resistance, and conquers the tissues of its victim, not in steady or arithmetical ratio, but in an accelerat-

Digitized by Google

ing or geometrical ratio of speed. In a late stage it covers more ground than in an early stage. Let us consider what law of growth exists, if any.

In most organs a malignant tumor finds room to spread centrifugally in an enlarging circle, or, more properly, a sphere. Leyden justly observes that it begins as a strictly local phenomenon, and its most striking feature is its unlimited proliferation. "Unlimited proliferation" can be taken almost literally. The clinical fact is admitted, regardless of our theories for or against parasitism.

Starting with the strictly local atrium or focus, which we all admit, and ending with unlimited proliferation, we have a phenomenon so closely like that of radiant energy, heat, light, sound, that we are forced to admit an analogy in the law of progression.

Stated mathematically, the infection radiates in a sphere, with the primary focus as a centre. Like all radiations, it follows the law of squares. The superficial area, which is an index of the risk of metastasis, increases as the square of the diameter of the infected area. If a uniform growth in diameter takes place in a uniform time, when multiplying time by 2 would increase risk 4 times; multiplying time by 3 would increase risk 9 times; multiplying time by 4 would increase risk 16 times; multiplying time by 5 would increase risk 25 times; multiplying time by 10 would increase risk 100 times.

This soon brings us to infinite risk in finite time. In other words, a comparatively short time suffices to make every case infinitely dangerous or practically hopeless. This only restates theoretically what every surgeon knows to be mournful truth clinically.

What we lack to confirm this law clinically is means of locating the exact time of origin of any case. Theoretically, it is the date when the growth crossed the line between the microscopic and the macroscopic period. Practically, it is the accidental time of discovery of a neoplasm—early in accessible and exposed tissues, later in more concealed parts; perhaps never discovered before death in certain remote or unusual locations, as in the brain, prostate, or skeletal deposits.

Digitized by Google

THE LAW NOT A DEATH WARRANT. Discouraging as this law is when stated in its first or positive form, we may derive much comfort from converse proposition.

THE RISK OF RECURRENCE DIMINISHES IN THE RATIO OF THE SQUARE ROOT OF THE TIME AFTER INCIDENCE. The law, thus stated, admonishes us that an early golden period is always given us for saving the life of the cancer victim, and imperatively demands us to take action during the brief and precious stage. We should look almost reverentially on the opportunity which then exists.

It is this curable stage only which is of strategic importance in surgery. Just what are its limits? Looking at the life history of any malignant case, we may consider it as composed of three periods: (1) The microscopic period; (2) the macroscopic period, before metastases; (3) period after metastases or carcinosis period.

Of the first or microscopic period we know nothing except by inference.

For the carcinosis period we have little to offer therapeutically, save the hope that the *x*-rays, or some remedy yet unknown, may come as a sort of deus ex machina to the rescue.

Of the second stage, that of tumor building without metastases, we think we have abundant clinical evidence. Radical surgery should be mainly limited to this stage. By the law I have attempted to prove, I have obtained a working formula which, when applied clinically, will determine for us not, perhaps, the exact time limits within which it is safe to operate, but, at any rate, certain limits beyond which it is useless to operate for radical extirpation.

CLINICAL TEST OF THE LAW. On the chart, two extreme cases, one extraordinarily rapid and the other unusually slow, both of which illustrate its accuracy, can be represented by the line, *o*, *p*, *q*, etc.

CASE I.—Miss M., aged forty-seven years, robust and well in appearance, had, in November, 1894, a small movable nodule, size one-half inch, in right breast. Known duration, three weeks. I gave a bad prognosis, but allowed a delay of one week for observation. Patient, however, waited six weeks, and consulted me in

Digitized by Google

January, with the tumor increased sixfold, and already some glands in axilla. I estimate the growth at fully 100 per cent. weekly, and it proved to be the most rapidly malignant carcinoma of the mamma I ever saw.

Plotting the curve of this case on the basis of a doubling each week, we have the extraordinary result of a practically hopeless prognosis in five weeks, and apparently fatal result imminent in a few months. This actually happened. I removed first one breast and axillary contents, and the opposite one a few weeks later, patient dying in May, six months after the first invasion, with large metastatic masses in liver, both lungs, and pleuræ.

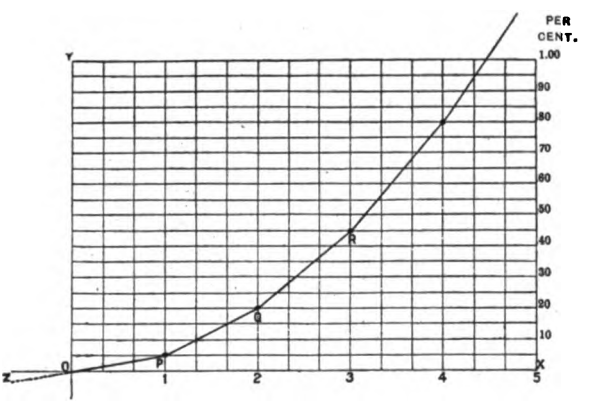

The risk curve in carcinoma. 1, 2, 3, etc., time elapsed. 10, 20, 30, etc , per cent. of risk. O, P, Q, "risk cure."

CASE II (the slowest I can remember).—Mrs. R. K., patient of Dr. C. P. Paldwell. Had slow-growing carcinoma of left breast. I estimated the time required for doubling at six months, basing this on history. This rate, plotted with the abscissa representing six-months' intervals, gives a danger limit very slowly accelerated, and a fatal result years distant. Exactly this did occur. The breast and glands were removed by me, and patient had no recurrence for three years. I considered her cured.

Very slow re-development in the old breast scar and axilla then appeared, and patient eventually died of the cancer eight years after the first appearance.

Digitized by Google

I have tested this graphic method in a large number of cases by the past history, and a few by way of prophecy, and have every faith in its accuracy. By it we can exclude, with fair accuracy, all those cases which ought not to be operated upon. When the risk curve plotted by my law has risen to the upper half of the card, say to 90 or 100 per cent., it is useless to do other than palliative operations. There is no class of cases likely to discredit surgery more than those tumor operations so often done, in which rapid recurrence takes place, and in which a subsequent review of the whole case shows patient's family and physician alike that the operation really never had a chance of succeeding. A careful application of this law will put us at a middle stage of any case almost in the position of one who has seen its whole course. I am certain that the first stages of any growth furnish the data for all the later stages, whether it be very slow or very rapid. Although each case has its own rate of progression, that rate, once determined, will accelerate uniformly, according to the law of squares.

I shall be very much interested to learn if these conclusions are not confirmed by the experience of other operators.

Digitized by Google

DISCUSSION ON CANCER SYMPOSIUM.

PROFESSOR KÜSTER, of Marburg.

First I regret that I did not find an opportunity to obtain reports of all my patients operated on for cancer of the breast, in number about 650 persons, so I cannot therefore present any statistics. I prefer to speak only of two points which seemed to me particularly remarkable in the excellent papers read.

The one point is the classification of the cases of cancer of the breast. We have heard spoken of adenocarcinoma, scirrhus, medullary carcinoma, and other forms. But if we consider anatomically the mammary cancer we may only discover two forms, differing by the maternal ground from which they emerge. The one form contains fine alveoles in the form of small rents, filled by small epithelia in one or two rows. These epithelia are so similar to the epithelia of the finest milk ducts of the mammary glands that there is no doubt this is the maternal ground. On the other side, we see great irregular alveoles stopped up with large epithelia. The form resembles so completely the enlarged acini that we may conceive them as emerged on the ground of the acinous tissue of the gland. Therefore, we call the first form the tubular, the second the acinous form of the mammary cancer. Now there is no doubt that there are certain differences in the course of the two forms, supposed that they remain unchanged, but, unhappily, we see great changes as soon as the tumor becomes large. Then we find on the one side a tubular and on the other an acinous cancer in all transitions, so that it seems quite impossible to say which has been the maternal ground on which the tumor first emerges.

The second point remarkable in the statistics presented is the length of time in which a patient may be considered surely healed. Richard v. Volkmann first stated the time of three years, but later it was extended to five years. We know now that even this seems not sufficient, and surely every surgeon of great experience has seen similar cases to those reported. I saw a case operated upon in 1872, without opening of the axilla, return with a cancerous gland on the neck after seventeen years; it could not be completely extirpated. These cases seem to be of great importance in the question of the causation of cancer. If we see a cancer return after seventeen years, as I did, we may suppose a new cancer has taken place without connection with the first. This is not possible to suppose if we find a cancerous gland after so long a time; and as it is impossible to suppose that the cancerous epithelia endure so long a time without regressive metamorphosis, one must say that there is a good proof of the parasitical nature of the cancer.

Digitized by Google

DR. JAMES E. MOORE, of Minneapolis.

In the matter of recurrence, we have all censured ourselves when we have had local recurrences. I have some photographs here that have led me to believe that possibly we have censured ourselves unjustly in thinking we have not performed a complete operation, when it really was as complete as might have been. These photographs are of a patient operated upon first in August, 1904. A complete operation was done, both muscles removed with a wide area of skin, and the axilla cleared out as well. She was seemingly perfectly well for two years. In August, 1906, two years exactly, she came back to me and had areas of recurrence. The little nodules in the skin were quite a distance from the original disease. In other words, they occurred in portions of the skin which were originally away over under the woman's arm and down on her abdomen. At her urgent request I made a wide removal of the skin, removing these nodules completely, and again dissected the skin on her side and down below the thorax, bringing the edges together and getting primary union. She returned from California in April, 1907, seven months after this last operation, and again has nodules of recurrence, not at the line of suture, but quite a distance away in skin that had been originally almost around on her back, and one spot down on her abdomen.

Now is it not possible that my original operation was as radical as I could make it, and the foci which have caused these recurrences were in the mediastinum? What led me to think this is that this woman is rapidly failing from mediastinal growth. Is it not possible that these mediastinal foci were there all the while and that these nodules in the skin are secondary to them and not to foci left in the skin? The second recurrence occurred immediately over the same space that had the first recurrence.

I wish to say just a word about an idea brought out by Dr. Vander Veer. I entered the profession as quite a young man and with surgical aspirations; I did my first breast operation over thirty years ago while a country physician in western Pennsylvania. After repeating the operation a few times my recurrences were so uniform that I became totally discouraged and did not operate; and even in later years, when I removed to a city and became more actively engaged in surgery, I did not encourage operation until after the appearance of Dr. Halsted's report. Since that time I have grown more and more optimistic, and, in spite of the disappointing results in many cases, have we not greater reason for optimism than for pessimism in this matter? Have we not made wonderful strides in the past, and can we not hope for more in the future?

Digitized by Google

DR. JOHN B. ROBERTS, of Philadelphia.

I would ask the Fellows in discussing this question to also express their opinions on the propriety of the actual amputation of the arm in cancer of the breast which has involved the axilla, either in the primary or secondary operation. This suggestion has been made a number of times by me, in the *Annals of Surgery*, January, 1898, p. 111, and other writers. We see by these papers that the activity of the operator is sometimes stopped at a point not quite as far distant from the primary lesion as it should be. In cases where the infiltration of nodes extends high up around the vessels, cannot we do better by actual sacrifice of the arm to reach the higher regions of the armpit? Dr. Vander Veer reported successful excision of one or two inches of the axillary artery. I myself have excised the subclavian vein and portions of the subclavian with satisfactory results. It seems to me the more radical step of brachial amputation should be included in this discussion.

DR. C. B. G. DE NANCRÈDE, of Ann Arbor, Mich.

There are a sufficient number of cases on record such as I shall relate to justify my mentioning one case if not more in my own experience. I made a clinical diagnosis of sarcoma of the breast, and to my great surprise I received word from Professor Warthin, who examined the specimen microscopically, that it was an epitheliomatous neoplasm, not a connective-tissue one. Shortly after that one of my assistants, examining this same breast, submitted to Dr. Warthin some sections which he unhesitatingly pronounced to be sarcoma. When he was told it came from the breast he had asserted was carcinomatous he could not believe it, but felt sure that some mistake in labelling the tumors must have occurred. That breast was examined over and over again and presented the most typical forms of both carcinoma and sarcoma.

Dr. Dennis mentioned a case, where after a carcinomatous breast had been removed, if I am not mistaken, sarcoma appeared in the other breast. I believe that probably the original growth that was removed and pronounced carcinomatous was also sarcomatous.

There is another thing I wish to mention. In quite a number of cases in which I have removed the breast for carcinoma I have also found the breast to have been tuberculous as well.

I would therefore recommend a little more widespread microscopic examination of breasts than we are in the habit of giving them. Portions of the tumor from different, widely separated localities should be examined, and I believe they will explain some of our otherwise inexplicable results.

Digitized by Google

DR. ALEXANDER H. FERGUSON, of Chicago.

In taking up the point mentioned by Dr. Roberts regarding very extensive operations even at the sacrifice of the upper extremity, let me sound a note of warning. Amputation of the upper extremity does not facilitate the removal of the deep lymphatics of the neck. If these lymphatics are extensively involved there is no sense in removing the upper extremity with the idea that such an amputation will aid in obtaining a permanent cure. I removed the upper extremity in one case, a recurrence one and one-half years after operation. The recurrence involved one and one-half inches of the axillary vein and the musculocutaneous and internal cutaneous nerves, causing partial paralysis of the arm with extensive edema. Here was a case where I thought amputation to be the only thing. I could find no extension along the lymphatics at the root of the neck. I removed the upper extremity and, I think, all the recurrences in that region. On the tenth day, while my patient was eating breakfast and sitting at the table, she commenced to have bad symptoms and died within fifteen minutes.

That is my only experience with amputation of the upper extremity. I have gone into the neck a number of times, probably seven or eight. Every patient died inside of two years. I have removed ribs, costal cartilages, and sternum, and even a portion of lung. One of the cases, where I removed the ribs extensively, was a carcinoma in a male. He died inside of a year after operation. I have had three such operations on males. Two died inside of a year, the other is still living, having been operated on about fourteen years ago. I removed about one-third of the sternum, a portion of the lung and pleura in two cases. These patients recovered from the operation, but I do not believe that the operation did any good whatever. We used the *x*-rays afterward; both patients died inside of nine months.

From my own limited experience with these very extensive operations of removal of ribs, sternum, etc., to eradicate the disease when deeply seated, I believe it is better not to operate at all. It is my belief that these patients will probably live longer and with more comfort if not operated on than when they undergo such extensive operations.

DR. THOMAS W. HUNTINGTON, of San Francisco.

I have been interested in the discussion in reference to extensive operations in these cases and want to call attention to the work of Dr. Rixford, of San Francisco. In three of Dr. Rixford's cases he has gone completely into the thorax, has removed a very considerable portion of the pleura and all tissue that seemed to be involved. These cases are still living, and have been practically without suffering since operation. The intention of the operator should be for the prolongation of the life and

Digitized by Google

the comfort of the patient. I do not think that we should hold out that our patient will be permanently cured. This is not expected.

I wish to allude briefly to the matter taken up by Dr. Roberts. In one case of recurrence taking place six years after operation in a patient aged sixty-nine years, I found the axillary vessels involved in a large cancerous mass. Intrascapular thoracic amputation was performed. This old lady is living in Brooklyn, very comfortably, at the end of nine months, and there is no evidence of a recurrence.

It seems to me that such operations as this are not only justifiable but are to be urgently advocated.

DR. WILLIAM B. COLEY, of New York.

I have observed 65 cases of recurrent cancer of the breast and wish to give you a summary of them according to the time of recurrence: 10, or 15 per cent., recurred after the three-year period; 4, or 6 per cent., after fourteen years; the longest was seventeen years; 1, sixteen years; 1, fifteen years; 1, fourteen years; 1, seven years. One other interesting case recurred one and one-half years after the primary operation, was operated upon a second time and remained well for five and one-half years and had a second recurrence two years afterward; 30 cases, or nearly 50 per cent., recurred within the first six months, 8 cases within one to two years, 6 cases within two to three years.

Regarding the question of sarcoma and carcinoma in the same individual I reported, at the meeting of the Association a year ago, one case in which the carcinoma of the breast had been removed two years previously by another operator. I operated upon a recurring tumor, a large typical carcinoma. About two months later there was a tumor which developed in the submaxillary region which proved to be a typical round-cell sarcoma. It recurred promptly after removal and killed the patient in a few months.

I had another case of large sarcoma of the abdominal wall operated upon first by Dr. Tuttle and Dr. McBurney. At the end of ten years there was typical carcinoma of the breast, which I removed, but which recurred within a year and finally caused death.

I have one other case of sarcoma and carcinoma in the same individual, and I believe, in view of the recent investigations of Ehrlich, in which he succeeded in producing carcinoma and sarcoma in the same strain of mouse tumors after twelve generations, a tumor which was originally carcinoma, showing carcinoma and sarcoma in the same tumor, and later on showed pure sarcoma only. This goes toward confirming Mr. Ballance's opinion, that the infectious cause of malignant tumors may be the same organism, which under different conditions produce connective-tissue and epithelial tumors.

Digitized by Google

With regard to removing the entire upper extremity I have had no experience. A few years ago a patient of mine was advised by another surgeon to submit to this. The operation was performed against my advice and the woman died on the operating table. I think there is another side of the question which has not been touched upon. That is, the effect these extensive operations have upon other patients suffering from the early stages of cancer. If they see the results in the case of removal of the entire extremity, the patients usually dying shortly after the operation, then those with small malignant tumors are prejudiced against all operative measures, and I think in the long run we do far more harm than good.

DR. WILLIAM L. RODMAN, of Philadelphia.

In the first place a word as to Volkmann's law. Everyone admits, as a matter of course, that three years are not sufficient to enable one to declare a patient immune from recurrence, but Dr. Coley has just stated that only 15 per cent. of such cases recur after three years. So, after all, it seems to me that the Volkmann law is a good working rule, for if you extend the limit, to what period will you extend it? Ten years are not sufficient, probably fifteen are not sufficient, and it would seem also that at least a few of these supposed cases of late recurrences are not recurrences at all. In the first place one must demonstrate in every case that the histological type of the secondary growth corresponds in every way to the primary focus. In some of these supposed recurrences we have been told the one was carcinoma and the other sarcoma; one a hard growth, the other a medullary.

I maintain very much as did Dr. Ransohoff, that the probabilities are that many, perhaps most of these very late recurrences, are not recurrences or metastases at all, but simply secondary cancers in patients predisposed to cancerous growth. For if a patient dies with secondary cancer of the stomach, rectum, or uterus, it is foolish in every way to say that it is a metastatic growth. With the liver it is quite different. Do we usually see patients with cancer of the stomach or other internal organs living ten years after the onset of symptoms? And yet we must suppose that is to be the history of the case if we are to believe these cases are metastases. I would throw out these cases of vague and obscure abdominal affections that are supposed to be metastatic carcinomas.

I believe the prognosis of malignant disease depends more upon, as Dr. Halsted and others have said, the type of carcinoma than anything else, and I was quite surprised to hear Dr. Halsted say that his medullary growths had given better prognoses than his scirrhous. I think the majority have had a different experience with the soft, succulent growth,

Digitized by Google

and that they have had better results from the hard or infiltrating scirrhous growths.

As to technique, it seems to me that the most important thing in the technique of cancer of the breast is a very wide removal of skin. From visiting many clinics, both here and abroad, I am satisfied that this is the one step lacking in most instances. Men want to get primary union and consequently make small incisions, which simply make complete removal of the disease out of the question. I was impressed by the operation of Gross many years ago. His good results must have been due to the very free removal of skin. No man did a complete axillary dissection at that time. To give you an idea of the amount of skin Gross removed, I was present one day when there was a visitor present, and Gross said to him: "This is my dinner-plate incision." The visitor replied, "Dinner plate! it looks more like a cart wheel!" That was the reason why he got such excellent results. I believe the principle laid down by Dr. Halsted is correct: free removal of skin, removal of muscles in every case, and if the growth is situated anteriorly, in every case the neck should be entered. Halsted builded better than he knew, for Poirier and Cunes showed that in growths located superiorly there is a chain of lymphatics that may cause the supraclavicular glands to be involved before the axillary.

Moreover, Grossmann and Rotter demonstrated enlarged glands between the greater and lesser pectoral muscles, and they could never be diagnosticated or removed with the muscles in situ. I recently encountered such a case and demonstrated the condition to my assistants in the Jewish Hospital.

Of my private cases operated on in the past ten years—every one has been followed—there have been 70 per cent. cured. At least they are living without recurrence upward of three years after operation. I have not attempted to follow my ward cases, as it is impossible to do so in many instances; therefore none are included of my earlier operations, but a single one was cured.

Dr. Stephen H. Weeks, of Portland, Maine.

I have been very much interested in the papers and discussions, and yet I cannot accept all that has been said. One would infer from the papers and discussions that the completed operation consists in not only removing the breast, but removing all the tissues in the axillary space, the pectoral muscles, and entering the supraclavicular fossa. Now, it seems to me that a completed operation is one that removes all the diseased tissues. If that be the standard of complete operation, then I claim that so extensive an operation as that discussed is not completed; it is far from complete; it does not remove all the tissue invaded when

Digitized by Google

the supraclavicular space is invaded, because the mediastinal glands are then involved and these cannot be removed.

In my clinics at the Medical School of Maine and the Maine General Hospital, extending over a period of thirty years, while I have no tabulated statistics as to the number of operations and end results, I can think of a number of patients on whom I operated, five, ten, fifteen, twenty-five years ago, who are still living and free from the disease.

One portion of Dr. Warren's paper read by his assistant has been entirely overlooked as it seems to me. The statement was to this effect: that many years ago, before the so-called complete operation, when the operation consisted simply in removing the mammary gland and axillary glands when involved without removing the pectoral muscles, the end results showed better statistics than the results accomplished during this period of so-called completed operation. It has been my custom, and probably always will be, to remove so far as possible all tissues that are invaded. While it is impossible to tell the extent of the disease before the breast has been removed and the axillary space opened, I have endeavored to remove everything external to the muscles, sometimes including the muscles, and in every case where the glands within the axilla cannot be felt an incision is made through the axillary fascia, and if diseased glands are discovered they are removed.

I think the teaching of Sir Frederick Treves years ago has some importance. There is a function performed by the deep cellular tissues in the axilla; they act as a cushion, protecting the vessels and nerves from pressure.

When all the cellular and fatty tissues have been removed the blood-vessels and nerves are unprotected from pressure and there is likely to be swelling of the hand, forearm, and arm, with more or less of discomfort from pressure. Of course, if these tissues are infiltrated with cancerous deposit they should be removed, otherwise not. The old rule in surgery which will be a good rule, however old it may be, "the removal of all diseased tissues, with the least possible sacrifice of healthy structures." The problem is one of education. The people must be taught to apply to the surgeon early, and that an early operation will cure in the majority of cases. When the disease is removed early, extensive dissection will not be necessary.

DR. ELLSWORTH ELIOT, JR., of New York.

There are several phases of this subject in which I am particularly interested. First, as to two cases of late recurrence: one a woman, aged thirty-seven years, with a traumatic history and a growth of one year's duration; the growth was removed by operation, and four years afterward a scirrhus appeared in the innermost extremity of the

Digitized by Google

skin near the sternum. This was removed two years ago and since that time there has been no further recurrence. The second case was a woman, aged forty-two years, who presented a tumor of four years' standing with superficial ulcers of the overlying skin, in whom radical operation was done in 1899; the axillary glands at the base were involved, but were free at the apex. There was no recurrence for seven years, and at the end of that time two inches above the inner part of the scar a small nodule appeared which was removed, entirely invested in the subcutaneous fat, and microscopic examination showed it to be cancer presented in two distinct foci, separated by an interval of subcutaneous fat.

In regard to the first case I agree with Dr. Ransohoff and Dr. Roberts. Occurring in a cicatrix at a distance from the seat of original growth, I regard it as a cancerous degeneration of cicatricial tissues rather than as a fresh outbreak of the disease. The original histological examination was mislaid and therefore it cannot be positively stated that the secondary nodule presented the same characteristics as those of the primary growth. The second case I would consider a latent focus, because the recurrence took place in the subcutaneous fat.

Another phase of this subject is that a diagnosis of possible recurrence may be made without sufficient warrant. Such an important mistake was made in the two following instances: the first occurring in a patient aged thirty-nine years, with a growth of several months' standing removed by complete operation, in which, after operation, there was some temporary swelling and edema of the arm. This swelling did not reappear for five years after operation, when a recurrence in the upper mediastinum was declared to have taken place and amputation of the upper extremity and shoulder advised. She did not consent to this operation, the edema disappeared, and during the past three years no further suggestion of recurrence has appeared.

A second case is that of a patient, aged forty-five years, operated upon by complete operation in 1899. For five years there was no trouble; then she developed neuralgic pains in both lower extremities and in the loins, with an irregular temperature and with a considerable amount of prostration. A diagnosis of carcinoma of the lung and pleura was made by one of the best medical consultants in New York. This was three years ago and the symptoms subsided and have not returned.

In conclusion, I would like to emphasize the advisability of radical operation in every case of carcinoma of the breast, irrespective of its extent, for after that operation the mortality is no higher nor the eventual function of the arm more materially impaired than after removal of the breast alone, while the wider excision of the growth provides greater immunity against recurrence.

Digitized by Google

DR. B. FARQUHAR CURTIS, of New York.

I am very much interested in the question of late metastatic growths. In one case of my own after removal of the breast the patient remained perfectly well for about nine years. At that time she began to have a short, dry cough resembling the symptomatic aneurysmal cough, and examination showed a growth in the mediastinum of moderate dimensions. Two or three weeks after that occurrence she had a hemorrhage in one eye. Ophthalmoscopic examination proved a new growth in the eye. I think in this case, with absolute freedom of local recurrence, without the symptom of any other primary tumor, with the appearance of a mediastinal growth, we have to assume that the deposit in the mediastinum at any rate existed from the time of primary operation. (*Annals of Surgery*, February, 1906.)

I believe there is microscopic evidence to show that cells of the carcinomatous type may exist in distant lymphatic glands for years and be found without any growth, the patient having died of some intercurrent condition. One German case (Lomer reporting for Lubarsch) died of pneumonia some five years after removal of the breast, and the autopsy showed in the deeper glands of the axilla carcinomatous cells in a quiescent condition. I do not think we need be afraid to assume that isolated cells may be shut off, encapsulated, or that their growth may be checked by the influence of the cells about them, just as in the case of bacterial infection, the germs may lie latent, only returning to activity after some change in the conditions.

DR. W. H. CARMALT, of New Haven, Conn.

With reference to the microscopic examinations of breast tissue, I believe no one who makes many microscopic examinations of removed breasts but finds not infrequently in the same breast both carcinoma and sarcoma, he names it the prevalent type of growth, but the recurrence or the secondary growth may be of the other variety.

Another point I should like to refer to has not to do exactly with carcinoma of the breast, and hence I may be out of order. It has to do with the changes in neoplastic growths, but illustrated by a case occurring in the uterus. I removed a uterus from a woman, aged thirty-two years, who had presented no symptoms except that of a tumor discovered accidentally by the masseuse. I advised waiting at first, but in the course of a few weeks it increased markedly and operation was determined upon. Complete panhysterectomy was performed, the vagina being sewed up. The tumor was examined and pronounced to be a pure myoma, nothing else, and of course we then gave a favorable prognosis. The patient made a rapid recovery. But in a few weeks a tumor was found in the abdomen which evidently was

Digitized by Google

connected with the kidney. She declined operative interference, and in the course of a few weeks further she began to develop brain symptoms, and examination showed double optic neuritis, and she died finally from the effects of a brain tumor. An autopsy was obtained and the tissue of this tumor revealed a small round-cell sarcoma. I then reëxamined the original tumor of the uterus, which was still in the laboratory; went over it as carefully as possible, and nothing but myomatous tissue was found in it. We cannot call this sarcomatous transformation or metastasis; it shows that certain individuals have a neoplastic tendency which may develop in many different forms apparently independent of each other.

DR. N. B. CARSON, of St. Louis.

I wish to call your attention to three cases of cancer of the breast in which recurrence took place after a lapse of several years. In the first case the disease returned in the scar after six years, and eventually resulted in the death of the patient. The second case was a lady from whom I removed the breast over fifteen years ago. There was a return in the scar between seven and eight years after the removal. This I removed soon after its appearance, and there has been no return in the cicatrix up to the present time. Three years after the removal of this nodule from the scar there was a return of the disease in the skin about three inches to the outer side of the cicatrix, which I also removed shortly after its appearance, since which time there has been no evidence of a return of the trouble. The third was a case of a lady whose breast was removed while she was abroad. After a lapse of at least ten years the disease appeared in the lung and pleura of the opposite side.

I would ask, if we are not possibly doing harm in trying to lengthen the time limit necessary to elapse before we may assure the patient against recurrence. The laity have been educated to the idea that three years is the limit. Three years of anxiety and fear, from which everybody from whom a cancer has been removed is waiting impatiently to pass in order that they may feel free from the chances of a recurrence. The discussion of the subject among ourselves is all very well, but when it gets abroad and those who have been afflicted with this disease find that we are trying to prolong the time of probation they will, naturally, feel discouraged, and it will prevent many persons from being operated upon who, otherwise, would be willing to submit to the knife if they could do so with the idea that after a lapse of three years without a recurrence they would be comparatively safe. I think that instead of trying to lengthen the time of a possible return, if we can consistently do so we should rather shorten the time, and impress upon the people the advantage of an early and complete removal.

Digitized by Google

DR. S. J. MIXTER, of Boston.

I wish to specially emphasize one fact brought out in the papers and discussions, and one point only. That is, the necessity of a radically thorough operation, and in this I think I have voiced the opinion of the great majority of the Fellows. No mutilation can be so terrible as the disease, and whatever mutilation takes place during operation, whether it be amputation at the shoulder-joint or a large open area, it cannot possibly be as bad as the horror of cancer. I think that the Association should emphasize this fact. And another thing, the smaller the growth the bigger the operation: The more desperate chances should be taken in the small growths, because there we have a better chance for a radical cure. The necessity for making this stand, I think, is shown from the fact that a great many men who are not skilled surgeons think they can remove a breast, that it is the simplest thing in the world, and they do an incomplete operation. Let us insist upon the radical operation.

DR. HERBERT L. BURRELL, of Boston.

I wish to submit the following resolution to the Association:

Resolved, That the American Surgical Association recommend the medical profession to strongly advise any person who has a palpable tumor of the breast to have the tumor examined at once by a competent surgeon, and if necessary have the tumor removed by an adequate surgical operation.

This opinion may seem trite to us, but I think that this opinion is not generally acted upon throughout the medical profession. Particularly is it true, that a certain class of practitioners keep these cases of tumor of the breast in the early stages for weeks, frequently months, and then, after they have passed beyond the line of operation, they are sent to surgeons. The point is this, a tumor in the breast should mean that the tumor should be examined by a competent surgeon and if it is necessary a microscopic examination should be made of a small section of the same, then if the condition is found to require an operation it should be done at once.

DR. CHARLES A. POWERS, of Denver, Col.

I make a brief report of end results in 29 cases of complete operation for cancer of the breast done in Denver between 1894 and 1904. While the number is small it represents all operations performed during these years, each case being carefully followed from year to year. Of these cases 28 were in private practice. The results are as follows: Died from the operation, pulmonary embolus on the fifth day, 1; living with recurrence, 2; died from recurrence, 16; living and free as yet from recurrence, 10. This gives 34 per cent. of the so-called three-year cases, but, as said, the total number of cases is very small.

Digitized by Google

PRIMARY SARCOMA OF THE PROSTATE.

By CHARLES A. POWERS, M.D.,
DENVER.

Mr. A., of Cheyenne, aged sixty years, consulted me February 7, 1907, regarding a rapidly increasing difficulty in urination. He was an unusually strong and healthy man. He stated that he never had any sort of bladder trouble until two months before, when he began to notice a little pain and discomfort on urination, and began to rise in the night to urinate. The symptoms rapidly increased, and, coincidently, he lost flesh and strength.

Examination. The man is 5 feet and 9 inches in height; he weighs 180 pounds, having lost 25 pounds during the last two months. He complains of constant, severe pain in the hypogastric region and a constant pain, which is less severe, in the recto-perineal region. He urinates about every one and one-half hours, day and night, urination being attended by increasing difficulty and pain. The urine is entirely normal. Catheterization finds no residual urine whatever; both soft-rubber catheter and ordinary searcher pass easily to the bladder; no stone is found. Rectal examination reveals a very large, rounded, slightly nodular, balloon-like prostate. The finger does not reach the upper margin. The prostate bulges widely laterally and well posteriorly. The impression gained by the finger is an unusual one; the balloon-like mass seems large and uniform; it is only moderately tender; it is of moderate consistency; the abdomen is fat and rather rigid; the mass cannot be made out bimanually. The pulse is normal in frequency and in character; the heart sounds are clear; examination of the lungs is negative; the temperature is normal.

The patient was sent to a hospital, and five days were spent in preparation for operation. During these days the urine was at all times abundant in quantity and normal in quality. While diag-

Digitized by Google

nosis seemed in doubt, it seemed probable that the growth was malignant. The short duration of the symptoms—two months—the rapidity of growth, the balloon-like contour of the growth, and the absence of residual urine pointed toward sarcoma, and a tentative diagnosis was accordingly made; cystoscopy was not done. The situation was fully explained to the patient, who definitely requested operation.

Operation under ether by the drop method at the Mercy Hospital, February 12, 1907. Ordinary, inverted Y-incision. The central tendon of the perineum and the recto-urethralis muscle were divided; the deep urethra was opened and the finger passed readily to the prostatic urethra. A gloved finger of the opposite hand in the rectum allowed bimanual palpation and showed the growth to be larger and to extend higher than was at first thought. The finger tore readily through the prostatic urethra into the left side of the mass and the process of enucleation was begun. This was attended by profuse, alarming hemorrhage; blood poured from the wound, and the wound had to be firmly packed with hot, salt cloths. As soon as packing controlled the hemorrhage, enucleation was proceeded with, but was exceedingly difficult. Very frequent hemorrhages obliged one to stop and pack. Nowhere could a lead be gained between the gland and its capsule. Friable masses were reamed out from both sides of the gland and from it posteriorly. These, to the eye, had the appearance of sarcoma. An assistant's fist above the pubes crowded the bladder down, yet one could not reach the upper part of the growth; this upper part seemed fixed. As much as possible was brought down and torn away by heavy, ringed clamps. At all points the growth seemed fused with the prostatic capsule, and it was apparent that here and there a portion was left behind. A T-shaped tube, alongside of which was seen a small irrigation tube, was placed in the bladder and the large prostatic cavity firmly tamponed and packed with sterile gauze. The loss of blood had been great, and although salt infusions had been given on the table, the patient was returned to his bed with a poor pulse.

During the succeeding twenty-four hours the patient's condition

Digitized by Google

was precarious, but under copious salt infusions and ordinary stimulation he picked up, and at the end of thirty-six hours was in fairly good condition and secreting a good amount of urine. At the end of the second day a double pneumonia appeared, to which he succumbed on the fifth day. An autopsy was not permitted.

The masses of growth removed amounted to a double handful. They were submitted to Dr. J. A. Wilder, Professor of Pathology in the University of Denver, who makes the following report:

The specimen consists of a number of large and small pieces of a reddish-gray, rather friable tissue. The pieces are irregular in shape; the larger ones are from 2 to 5 cm. in diameter.

Histological examination of sections from different parts shows the tissue to be composed chiefly of small, round and oval cells with very little intercellular substance. A delicate fibrillar supporting meshwork in which the tumor cells lie can be made out in some areas. The nuclei of the cells are large and prominent and have a distinct nuclear membrane. A small ring of protoplasm can be seen around the nuclei of many of the cells, in others it cannot be seen. These cells have no definite arrangement. The vascular supply is fair. The bloodvessels have very thin walls and are surrounded by the tumor cells. The remains of the prostatic tissue are seen in some of the sections in the form of a stroma of unstriated muscle fiber, and fibrous tissue containing gland tubules lined with cuboidal epithelium, the glands in several instances containing corpora amylacea.

Diagnosis. Small round-cell sarcoma of the prostate.

In the foregoing case operative attempt was dangerous. Complete operative removal was to me impossible. Immediate microscopic examination of the first fragment removed from the growth might have certified its nature, and thus have saved an operative death. The growth was extending so rapidly, however, that death by sarcoma would have been speedy. I doubt if the suprapubic route would have given better access to the tumor than did the perineal. I judge that the hemorrhage was controlled better through the perineum than it could have been through the bladder.

A careful study and analysis of accessible literature reveal but

Digitized by Google

22 additional cases of microscopically proved, primary sarcoma of the prostate.[1] These are reported by Barth, Birch-Hirschfeld, Burckhardt, Botescu, Gibson, Grätzer, Kaufmann, Levy, H. Marsh, Matthias, Oliva, Socin (Kocker), Schalek (2 cases), Spanton, Stern, Tordeus, West, Wharton,[2] Wind, Van der Hoeven, and Verhoogen. Cases which are not definitely authenticated, but which are probably true cases, are reported by Adler, Aiken, Cabot, Coupland, Dupraz, Harris, Isambert, Jolly, and Mann, while doubtful cases are instanced by Barth (2 added cases), Brée, D'Haenens, Dickinson, Fergusson, Jolly (anat. specimen), Kapsammer, MacGowan, Réboul, Socin (added case), and Spanton.

The ages of the patients in the 23 cases classed as authentic, are as follows:

0 to 15 years	13	cases
16 to 30 "	4	"
31 to 60 "	5	"
Over 60 "	1	"
	23	"

The condition is, therefore, to be considered most frequent in childhood.

Histological examination of the specimens obtained from these 23 cases shows the form of the sarcoma to be:

Small round-cell in	8	cases
Spindle-cell in	3	"
Myxosarcoma in	3	"
Spindle-cell and myxosarcoma in	2	"
Small round-cell and spindle-cell in	1	"
Angiosarcoma in	2	"
Adenosarcoma in	1	"
Mixed-cell in	1	"
Large round-cell in	1	"
Microscopically examined, but form not given in	1	"
	23	"

[1] In certain instances cases have been accepted by one writer and discarded by another. In the present communication the writer has endeavored to class as authentic only those cases microscopically proved and primary. For example, the case of Dupraz is here classed as probable only, as it possibly had a primary seat in the scapula.

[2] Case also reported by Hughes.

Digitized by Google

The small round-cell form is, therefore, the most frequent.

As compared with carcinoma, sarcoma of the prostate is infrequent. Engelbach gives as percentages: carcinoma, 86 per cent.; sarcoma, 14 per cent. This sarcoma percentage is undoubtedly very much too high. A reasonably accurate computation will not be made until reports are furnished on large clinics in which all prostatic growths are submitted to routine microscopic examination.

The diagnosis is at times easy; at times difficult. A rapidly growing tumor of the prostate in a child or youth is probably a sarcoma. So, as well, is a rapidly growing, soft, balloon-like prostatic tumor in an adult. Pain is generally marked and is referred to the pubes, perineum, and rectum. Urinary urgency is not generally present in the early stages. As in the case which forms the subject of this paper, an enormous growth may be unaccompanied by residual urine.

Prognosis in these cases is necessarily bad. In each of the authentic cases submitted to analysis[1] by the writer, either (*a*) the disease went on to a fatal termination, or (*b*) the patient succumbed to operation, or (*c*) to relapse after operation, or (*d*) the case was reported simply as an operative recovery. An editorial writer (*American Journal of Urology*, 1903–6, vol. ii, p. 129) goes so far to say that the simplest and most rational treatment is to allow the disease progress. While it is true that no lasting cure has thus far been reported, it is but rational to assume that in the future early diagnosis and appropriate management, either by operation or serum therapy, or by both, may give to this disease a more hopeful outlook.

References.

Th. Ackermann. Die Histogenese u. Histologie der Sarkome, Sammlung klin. Vorträge. Volkmann, No. lxxiv, S. 1971.

Adenot. Tumeur maligne de la prostate. Lyon Médicale, 1900, T. xciv, p. 237.

Adler. Hypertrophy of the Prostate Gland. St. Louis Med. and Surg. Jour., 1882, vol. xliii, p. 629.

[1] The majority of cases are scantily reported, and it does not seem necessary to give details here. Those accepted can be verified by aid of the bibliography hereto appended.

Digitized by Google

Andrew Aiken. Sarcoma of the Prostate. Provincial Med. Jour., 1891, vol. x, p. 208.

M. J. Albarran et N. Halle. Hypertrophies et neoplas. epith. de la prostate. Ann. des Maladies des Organes gén., 1900.

Edward Albert. Harnblase, Vorsteherdruse, Lehrbuch der Chirurgie u. Operationslehre, 1879, Band iv, S. 181.

Edward Albert. Tumoren d. Prostate. Lehrbuch der Chirurgie u. Operationslehre, 1885, Band iv, p. 177.

L. B. Bangs and W. A. Hardaway. Sarcoma of the Prostate. Amer. Text-book of Genito-urinary Diseases and Diseases of the Skin. Bangs and Hardaway, 1898, p. 335.

Arthur Barth. Ueber Prostata Sarkom. Archiv. f. klin. Chirurgie, 1891, Band xlii, p. 759.

Arthur Barth. Ueber Prostatasarkom. Verhandl. der deutschen Gesell. f. Chir., 1891, Band xx, pp. 176–181.

Botescu. Primitiv Sarkom. der Prostata beim Kinde. Revista, de Chirurgie, 1902, Nr. iv, p. 175.

M. Bouvier. Cancer de la Prostate. Bulletin de l'Académie de Méd., Paris, 1837–8, tome ii, p. 732.

Buchal. Ueber den primaren Krebs d. Prostata; dissertation, Greifswald, 1889.

Emil Burckhardt. Zur Kasuistik u. Ther. d. Prostata. Centralbl. f. d. Krankheiten der Harn- u. Sex. organe, 1894, Band v, S. 153.

Cardiot et Founier. Cancer de la Prostate. Rec. Bull., 1888, p. 348.

Bazy. Double adenome prostatique. Bull. et mem. de la Soc. de Chir. de Paris, 1905, tome xxxi, p. 921.

Beraud. Des maladies de la Prostate. Thèse agreg., Paris, 1857.

von E. Bergmann. Tumors of the Prostate. System of Practical Surgery, 1904, vol. v, p. 562.

Birch-Hirschfeld. A case of Adenosarcoma (cited by Kaufmann) in Verletzungen u. Krankheiten der Prostata, Socin. u. Burckhardt, 1902, S. 391. (Vide Lehrbuch, 1895, S. 1008.)

Bizzozero. Ueber das Stroma der Sarkome. Med. Jahrb. d. K. K. Gesell. d. Aerzte zu Wien., 1878, Heft iv, S. 429.

Carlin. Adenite Susclav. Cancereuse dans le Cancer de la Prostate. Assoc. francaise urol., 1896.

Carver. Primary Malig. Disease of Prostate. Lancet, London, 1886, vol. i, p. 788.

Casper. Die Radicalbehand. der Prostata-hypertrophie u. Prostatatumoren. Berliner klin. Wochenschr., 1888, Nr. xxiii, u. xxiv.

W. Clegg. Case of Large Sarcomatous Tumor of Prostate Gland. The Lancet, London, 1882, vol. i, p. 1032.

Cohn. Ueber bakteriologische Untersuch. bei Urethritis u. Prostatis. Centralbl. f. die Krank. d. Harn. u. Sexualorg., 1898.

Sidney Cupland. Medullary Cancer of the Prostate. Transac. Path. Soc., London, 1877, vol. xxviii, p. 185.

Croft. Cancer of the Prostate. Trans. Path. Soc., London, 1868, vol. xix, p. 285.

X. Delore. Cystotomie subpubienne dans le Cancer de la Prostate. Lyon Médicale, 1900.

Digitized by Google

A. D'Haenens. Sarcome de la prostate. Jour. Méd. de Bruxelles, 1901, vol. viii, p. 383.

Dickenson. Malignant Disease of Prostate. Trans. Path. Soc., London, 1865, vol. xvi, p. 190.

A. L. Dupraz. Le Sarcome de la Prostate. Revue d. Méd. de la Suisse Rom., Genève, 1896, tome xv, p. 465, 486; 1896, xvi, p. 465, 509–655.

A. L. Dupraz. Ueber das Prostata-Sarkom. Virchow, Jahresb. der Med., 1896, Band xi, S. 450.

A. L. Dupraz. Le Sarcome de la Prostate—Etude clinique et anat-pathologique. Revue d. Malig. Cancer, Paris, 1896–7, tome ii, p. 72, 145.

A. Ebermann. Ueber die Veränderungen der Harnröhr, bedingt d. v. Geschwülste der Prostata. St. Petersburg Med. Wochensch., 1899, Nr. 20.

Editorial in the American Journal of Urology, 1905–6, vol. ii, p. 129.

Paul Engelbach. Le Sarcome de la Prostate. Thèse de Paris, 1888, cited by Wolff in Deutsche Zeitschr. f. Chir., 1899, Band liii, 94–95.

Exner. Beiträge zur Histologie d. Prostata Carcinome. Dissertation, Greifswald, 1892.

E. Hurry Fenwick. Colotomy in Cancer of the Prostate. Brit. Med. Jour. 1887, vol. ii, p. 873.

E. Hurry Fenwick. Prim. Malig. Disease of the Prostate Gland. Edinburgh Medical Jour., 1899, vol. xlviii, p. 16.

Fergusson. Medullary Sarcoma of Prostate Gland. The Lancet, London, 1853, vol. i, p. 473.

Gartegen. Krebs der Prostata, u. s. w. Göttingen, 1898.

Septimus Gibbon. Medullary Cancer of the Prostate. Trans. Path. Soc., London, 1846, vol. v, p. 196.

C. L. Gibson. De Sarcome de la Prostate. Annales des Maladies des Organes genito-urin., 1905, tome ii, p. 1558. (Also personal communication.)

George Grätzer. Zur Statistik der Prostata Sarcoma. Inaug. diss., Würzburg, 1895.

George Grätzer. Ein Fall von Sarcom. d. Prostata. Prager med. Wochensch., 1899, Band xxiv, S. 563.

G. H. Gray. Case of Vesical Calculus and Medullary Cancer of the Prostate. St. Louis Med. Jour., 1877, vol. xiv, p. 1.

Robert Greene. Cancer of the Prostate. New York Med. Jour., 1903, vol. lxxviii, p. 785.

Gribbon. Cancer de la Prostate. Soc. Anat., Paris, July 4, 1896.

A. Guépin. Le Cancer glandulaire de la Prostate. Revue de Chirurgie, 1899, tome xix, p. 576.

Gueterbock. Die Krankheiten der Harnrohre u. der Prostata, 1889. Die Chir. Krankheiten der Harn-w.-männlich. Geschlechts organe, 1890.

Guyon. Le Sarcome de la Prostate, Revue gén. de Clin. et de Therap., 1905, xix, p. 581.

Worsley J. Harris. Malignant Disease of the Prostate. The Lancet, London, 1893, vol. i, p. 587.

Reginald Harrison. Tumors of the Prostate. Twentieth Century Practice of Medicine, 1895, vol. i, p. 256.

Digitized by Google

Berkley Hill. Cancer of the Prostate. Trans. Path. Soc., London, 1889, vol. xl, p. 181.

Egon. Hoffmann. Die Krankheiten d. Prostata. Klin. Handb. d. Harn- u. Sexualorgane, 1894, S. i.

Egon. Hoffmann. Die Untersuchung der Prostata am Lebenden, Klin. Handb. d. Harn. u. Sexualorgane, 1894, Band iii, S. 3.

Egon. Hoffman. Die Malig. Geschwul. der Prostata. Klin. Handb. d. Harn u. Sexualorgane, 3d ab., 1894, S. 51.

W. E. Hughes. Sarcoma of the Prostate Gland. Med. and Surg. Reporter, Philadelphia, 1882, xlvii, p. 688.

Isambert. Tumeur de la Prostate, Bull. Soc. Anat. Paris, 1853, xxviii, p. 97–102.

J. Jolly. Cancer of the Prostate Gland. Path. Trans., 1850, p. 130.

Jacques Jolly. Cancer of the Prostate. Arch. Gen., 1869, xiii, pp. 577 and 705.

J. Jolly. Essai sur le Cancer de la Prostate. Archiv. de Med., 6 Series, 1869, tome xiv, p. 61–184.

Jacques Jolly. Der Krebs der Prostate. Schmidt's Jahrbücher, 1870, Band 146, S. 104.

Julien. Contribution a l'étude clin. de Cancer de la Prostate. Thèse de Paris, 1895.

George Kapsammer. Beitrag zur Klinik der Prostata. Wiener klin. Wochenschrift, 1903, Nr. 5, s. 129.

Kapuste. Ueber den primaren Krebs d. Prostate. Dissertation, Munich, 1885.

Edward Kaufmann. In Socin. und Burckhardt's Verletzungen u. Krankheiten der Prostate, 1902, S. 388, 390, 391.

F. Koenig. Sarcome u. Carcinome der Prostata. Lehrbuch der Speciellen Chirurgie, 1893, Band ii, p. 821.

Kornfeld. Zur Klinik der Prostataerkrankung. Wiener med. Wochensch., 1897, Nr. 52.

Labadie. Du Cancer de la Prostate. Thèse de Lyon, 1895.

Labadie. Du Cancer de la Prostate. Thèse de Lyon, 1896.

Langstaff. Sarcoma of the Prostate. Cited by Thompson. Dis. of the Prostate, etc., London, 1861, p. 276.

H. Leisrink. Beiträge zur Chirur. der Harnführwege beim Manne. Archiv f. klin. Chirur., Langenbeck, 1882–3, Band xxviii, p. 578.

L. Levy. Zur Kasuistik d. Prostatagesch. in Kindesalter. Münchener med. Wochenschr, 1903, Nr. 10, S. 430.

Loumeau. Deux Cas de Cancer de la Prostate. Annales de la Policl. de Bordeaux, 1900, tome xii, p. 113–21.

F. Lydston. Cancer of the Prostate. Twentieth Century Practice of Medicine, 1895, vol. i, p. 396.

E. H. Madison. Cancer of the Prostate. Medical Record, 1895, p. 715.

G. MacGowan. Virginia Med. Monthly, vol. viii, p. 166.

Marchland. Beiträg, zur Kasuistik der Blasen-tumoren. Archiv f. klin. Chir., Band xxii, S. 682.

Howard Marsh. A Case of Sarcoma of the Prostate. Clinical Soc. Trans., 1896–7, vol. xxx, p. 162. (Also Lancet, 1897, i, 1092.)

Digitized by Google

Mathias. Zur Casuistik der Tumoren der Prostata. Inaug. Diss., München, 1889.

M. Nitze and E. Sonnenberg. Tumors of the Prostate. V. Bergmann's Practical Surgery (edited by Bull), vol. v, p. 552.

O. Oliva. Di un Sarcoma prostatico. Osservatore, Torino, 1883, xix, 609–625–641–657.

O. Oliva. Di un Sarcoma prostatico. Gazette delle Cliniche, 1883, No. 39, 42, p. 513.

Alfred Schalek. Primären Sarkom d. Prostata. Präger medicinische Wochenschr., 1899, Band xxiv, S. 547.

Max Schüller. Demonstrationen v. mikro. Proparaten zur Paras. Entsteh. von Krebs und Sarkom. Verhandl. d. deutschen Gesell. f. Chirur., 1902, Band xxxi, S. 68.

A. Socin. Krebs der Prostata. Pitha and Billroth, Handbuch der Chirurgie, 1872, Band iii, ab. ii, S. 105–6.

A. Socin u. E. Burckhardt. Die Verletzungen u. Krankheiten der Prostata, Stuttgart, 1902.

E. Sonnenburg. Geschülste der Prostate. Handbuch d. Praktischen Chirur., Bergmann, Bruns, Mikulicz, 1901, Band iii, S. 245.

A. Socin. Sarcome de la Prostate. Gazette Méd. de Paris, 1873, p. 410.

W. D. Spanton. Large Sarcomatous Tumor of Prostate Gland. Lancet, London, 1882, p. 1032.

W. D. Spanton. Myxosarcoma of Prostate and Bladder. Trans. Path. Soc., London, 1891, vol. xlii, p. 218.

Sperling. Zur Statistik d. Primären Tumoren d. Harnblase. Diss. Inaug., Berlin, 1883.

Adolph Stein. Ueber die Extirpat. der Prostata wegen Malig. Neubild., Verhandl. d. deutschen Gesell. f. Chirur., 1889, Band xviii, S. 247.

Stern. Tumor der Prostata, Deutsche med. Woch., 1902, Band xxviii, S. 308.

E. Tordeus. Tumeur abdominale (Sarcoma de la Prostate.) chez un enfant de neuf mois. Jour. d. Med. Chirur. et Pharm., Bruxelles, 1890, tome xc, p. 405.

James Tyson. Case of Spindle-cell Sarcoma. Pennsylvania Hospital Reports, 1869, vol. ii, p. 239.

J. Verhoogen. Ueber einen Fall v. Total Exstirpation d. Prostata wegen Malign. Neubildung. Centralbl. f. d. Krankheiten d. Harn u. Sexualorgane, 1898, Band ix, S. 19.

Virchow. Die Krankhaften Geschülste, Band ii, 1864–5, Berlin, S. 196.

J. Van der Hoeven. Sarcoom von de prostata, Nedrl. Tijdschr. v. geneesk, Amsterdam, 1903, vol. xxxix, p. 923.

Walter. Zur Casuistik d. Prostata Carcinome. Dissertations, Greifswald, 1891.

Samuel West. Sarcoma of Prostate and Bladder. Trans. Path. Soc., London, 1883, vol. xxxiv, p. 145.

H. R. Wharton. Round-cell Sarcoma of Prostate Gland. Medical News, 1882, vol. xli, p. 538.

Wind. Die malignen Tumoren der Prostata. Inaug. Diss., München, 1888.

Richard Wolff. Ueber die bosartigen Geschülste der Prostata u. s. w., Deutsch. Zeitschr. f. Chirur., 1899, Band liii, S. 134.

Digitized by Google

PROSTATECTOMY.

By ARCHIBALD MacLAREN, M.D.,
ST. PAUL, MINNESOTA.

At the meeting of the American Medical Association last year at Boston there happened to be no paper on the surgical program on the subject of prostatectomy. The remark that prostatectomy had evidently run its course, made by a number of our best surgeons, but by men who had done little, if any, work along these lines, caused me to elect this subject several months ago. Since that time two excellent works have appeared, one by Young, in the Johns Hopkins Hospital reports, dealing with perineal prostatectomy according to his well-known method; the other by Deaver in a beautiful volume, taking up in an exceptionally thorough manner all sides of this interesting subject. We have here in these two books the extremes; for Young practically always removes the prostate through the perineum, while Deaver, although he recognizes the occasional value of the perineal route, always uses the suprapubic operation of Freyer.

Several years ago Murphy, with his keen surgical judgment, in discussing this subject, took the position that both operations had their legitimate field; that when the prostate projected more into the bladder than it did into the perineum the suprapubic route was the best; that when the prostatic enlargement could be well defined by a rectal examination the perineal route was the operation of choice. Charles Mayo believes that in a stout man, with a thick perineum and a long prostatic urethra, with a high-lying prostate, that either the suprapubic or the combined operation is indicated.

The excellent results obtained by such men as Young, Deaver, Mayo, Goodfellow, and Ferguson, and many others, make us feel that both operations have been established on a firm and lasting

Digitized by Google

foundation; that they have proved their value and will always hold their places in the surgical world of the future.

For several years I made the suprapubic operation with excellent results. Some of the cases bled profusely and had to be packed; a few, especially the old, debilitated men, had infections of the prevesical space, endangering their lives and prolonging their convalescence. These bad cases did better when they had a perineal drain; therefore it seemed best to make the drainage opening first and explore the bladder from below; then, if it seemed easier and safer to remove the prostate from above, we could later make a suprapubic opening. In following this method I have been in the habit of making a median perineal incision, opening the prostatic urethra, and, after exploring the bladder with the finger, have usually found that I could remove the prostate through the prostatic urethra, even when it was of considerable size, and even when the enlargement was principally confined to the median lobe.

Since adopting this method of perineal exploration I have met with very few cases which could not be successfully removed through the perineal wound. This procedure is, as a rule, easily and quickly accomplished. The difficult ones usually prove to be the hard, fibrous prostates that have suffered from prostatitis perhaps for several years. The hard, fibrous prostates are always difficult to remove, whatever be the route of attack. Freyer describes one which he could not remove through the suprapubic wound, and had to abandon on account of the profuse hemorrhage, the patient dying in the next few hours in shock. As Deaver says, "This result is far from proving that the prostate, in this individual patient, could have been satisfactorily removed by a perineal operation, but it certainly shows that no one method can be exclusively employed, if we aim to secure the best results."

After exploring the bladder with the finger, which grows longer with experience, as Moore has so well pointed out, withdraw the finger into the prostatic urethra and pass into the urethra a sharp-pointed, short-bladed bistoury, and, with the finger as a guide, make a slit one inch long in the side wall of the prostatic urethra,

Digitized by Google

cutting deep enough to be certain that the capsule is well divided. After entering the capsule of the prostate, whether from above or from below, the enucleation of the lobe is not very different from the separation of an adherent appendage, after one has his finger in the line of cleavage, or perhaps it is more like the enucleation of a fibroid in a myomectomy. Sometimes it requires considerable force to remove a fibrous prostate. But some of my very best results, as far as urination and ability to have intercourse were concerned, have been just in this class of cases.

Young does the same thing with his much greater and more extensive dissection, only he divides the posterior wall of the prostatic capsule, while most other operators, myself among the number, work from the inside, dividing only the urethra. Deaver seems to think that Goodfellow divides the base of the bladder, but I am inclined to think that he follows the same line that I have just described.

My objection to Young's method is that too much anatomy is exposed, and that whatever the method of removal—whether by perineal or suprapubic route—the actual work of enucleation has to be done by the sense of feeling alone, and after entering the line of cleavage the sense of feeling is all that is necessary. Again, the posterior prostatic sheath and rectum are so intimately united that it needs the greatest care to avoid injuring the rectum in attempting to separate one from the other, while it is almost impossible to injure it when working from the inside of the prostatic capsule.

I speak from one sad experience. After I had been doing prostatectomy first by the suprapubic route and later by perineum for several years, I read Young's description, saw his beautiful plates, and I said to myself, "That is much the better method." On my first and only attempt I opened the rectum. I ought not to have done it, and believe that I would not do it again, but I have been afraid to try it a second time. The theoretical value of saving the ejaculatory ducts in these old men is, I believe, not a sufficient reason for exposing them to the considerable risk of a rectal fistula.

Young has had so much experience and has done his operation

Digitized by Google

so many times, that with him the risk of this accident is now very small, but with the rest of us, who have not had the advantage of his experience (8 per cent. in 50 cases), the danger, considering the great disability which this accident occasions, makes us hesitate, and keep to the median prostatic operation for the majority of cases, with the suprapubic for exceptional ones. Bellefield, who is a strong advocate of the suprapubic route, says, in the *Illinois Medical and Surgical Journal*, that rectal fistula occurs in 8 per cent. of 2000 reported cases of perineal prostatectomy—permanent incontinence in 3 per cent., stricture in 7 per cent., mortality 3 to 5 per cent.—and that with any but the median incision there is apt to be a loss of erectile power, not from the loss of the prostate, but from the destruction of the perineal muscles. He thinks that there is 20 per cent. of chances that the patient will find himself worse off after the operation than he was before.

I have not found this true in my own cases; perhaps they have gone to someone else. I know of two cases operated upon by other men, but good operators, one of whom would certainly be dead at this time if he had not had his prostatectomy. The other probably would have died. Both are very miserable from a suppurating cavity at the neck of the bladder. One who, following a suprapubic operation, had a later cystitis has refused to have another suprapubic exploration, and I have operated upon him twice through the perineum, with only temporary results. The other man I have never seen, but, from the description given me, has apparently the same condition following a perineal prostatectomy. He is being constantly irrigated by a friend of mine, in the hope that he may not have to have a second operation. Bellefield finds that the mortality of the suprapubic operation is twice as great as the perineal operation, but thinks that the risk is justified on account of the greater chance of a perfect cure. Murphy thinks that the mortality of the two operations is about equal. Bellefield advises when making the suprapubic operation that, to avoid infection of the prevesical space, either a two-stage procedure, five days apart, or draining of the wound through the triangular ligament and perineum should be adopted.

Digitized by Google

After doing the suprapubic operation for several years, with excellent results, I made a suprapubic cystotomy for a stone on a man twenty-two years old, with apparently a clean bladder. This was just after the modern suprapubic operation was described, and I carefully made the opening in the bladder water-tight, about the suprapubic tube, with a purse-string suture. The wound did not do well, and I eventually did everything but drain the patient from below, but in five weeks he died, with a small, contracted bladder, deep in the pelvis, and a huge abscess filling the entire pelvis above it. This experience has always been in mind when considering the best method of reaching any diseased bladder, and has influenced me more than any other one thing to favor the perineal line of attack.

Young's operation for cancer of the prostate is without doubt the best operation so far offered. I have only operated upon two cancer cases, one of whom lived over three years after a removal according to his method.

There is a small class of patients, which we should always keep in mind, that is, the neurotics. As prostatectomy becomes better known among the laity this class increases in number, just as in the surgery of the stomach the neurotics are the first to make the diagnosis of their own cases, and apply for relief. If they are truly neurotics, operation gives no relief at all. One such case has recently come under my observation. A weak old man of excessively nervous character came to me desiring prostatectomy. He had no cystitis, as evidenced by examination of the urine, but he had attacks of frequent painful urination—as often as every hour during the night, for several months—without much enlargement of the prostate. He had marked dyspnea at this time without any evidence that I could discover of pulmonary or cardiac disease. I referred him to my friend, Dr. Charles Greene, who found arteriosclerosis. Fortunately I did not operate, but saw him on and off for several months. Recently he died very suddenly of heart disease, his bladder having been considerably improved by internal medical treatment.

The patient suffering from an enlarged prostate often can be

Digitized by Google

very much relieved by intelligent use of the catheter. He should be carefully instructed in the care of it. I have known patients who have safely used a catheter once or twice a day for several years. Sooner or later the bladder becomes infected, and usually this is the time that the surgeon first sees the case. I have known several cases so badly injured at the time of the first retention by the heroic and hysterical abuse of the catheter by the medical man that the patient was killed as a result. If the patient objects to the use of the catheter, I usually encourage him to have his prostate removed. The danger of the operation upon a clean case is very small, while the danger to an infected case is very much greater. As a class, "prostatics" are the most satisfactory of any in surgery, especially the bad cases, the ones who have used a catheter until the breakdown of catheter life. They have become disgusted with themselves, have been in torment, and I know of no class who are so much pleased as are these old men when they find that they can again urinate naturally.

Young believes, after a careful study of 145 cases, that gonorrhea is not an active factor in the production of prostatic hypertrophy, and he found only eight strictures in all of these cases before operation.

In regard to the symptoms, pain seems to be rather a common one—pain usually situated in the perineum, especially in calculous cases, and several that I have seen have suffered from painful nocturnal erections.

I have noted hematuria in a number of cases, sometimes in the early stage of the disease; in others later in its course. Complete retention of urine has been the first symptom complained of in 20 per cent. of my cases. The frequency of urination has been the most common symptom complained of in over 50 per cent. of cases, urination about every hour during the day and every two hours during the night. Cystoscopy has not been at all satisfactory in cases where this was tried, and I agree with Deaver in believing that there is more danger of doing harm with the cystoscope than there is of a chance of acquiring useful information by its use.

In the last 25 prostatectomies there has been one death. This

Digitized by Google

man was seventy-five years of age, a patient of Dr. Kilbride's, of Canby, Minnesota—a weak, thin, emaciated old man, with a temperature of 105° and suffering from frequent chills. I watched him several days and saw that he was going to die if he did not get some surgical relief. Under these circumstances I always feel that if I were the patient I would want the surgeon to assume his part of the risk. So, at his request, I operated upon him, and found that he had a large glandular adenomatous prostate, which shelled out easily from the perineum. Two large stones were then removed through the same wound. He lived seven days, and died of exhaustion. At the autopsy an old double pyelitis was found, the kidneys being almost completely destroyed.

Digitized by Google

DISCUSSION OF THE PAPERS OF DRS. POWERS AND MACLAREN.

DR. C. L. GIBSON, of New York.

To Dr. Powers' list of cases I can add another. A man aged twenty-four years was operated on by another surgeon, who removed by the suprapubic route an intravesical growth springing from the prostate. Microscopic examination showed a small round-cell sarcoma.

When seen by me he was profoundly septic, chills and elevations of temperature. The suprapubic wound was reopened, and an incision was made through the bladder wall encircling the urethra. Then, by a wide, perineal dissection the greatly enlarged soft, spongy prostate was removed in toto. Although the tumor was thus thoroughly removed and free drainage provided the patient succumbed in three weeks, with persistent septic manifestations.

As regards the operative treatment of the hypertrophied prostate, I am thoroughly in favor of the perineal route and the small median incision. When beginning to operate eight years ago, I tried various other methods: the suprapubic route; the combined suprapubic and perineal, with a liberal dissection of the perineum; then the straight perineal incision, with a finger opening in the bladder above for counter-opening. But my results were disappointing, being attended with a considerable mortality. From the time when I limited myself four years ago to the present perineal operation I have not lost a single case, and have been accepting increasing "risks" up to eighty-five years of age.

A quick operation is a sine qua non in these elderly individuals—the average age of my patients in the past year has been seventy-two. I think my operations seldom average over ten minutes, and these old gentlemen so operated show little shock or reaction. They make quick convalescence, not being disturbed by the presence of a complicated wound; they are up within a week, and some of my favorable cases have been all healed in sixteen days.

Such an operation is truly a life-saving measure in these cases, and can be done under conditions which would totally forbid the doing of a slow deliberate operation with a wide exposure of the parts, such as is necessary in Young's operation.

DR. J. C. MUNRO, of Boston.

I can add one case of primary sarcoma of the prostate occurring in my service at the Boston City Hospital in 1902, and operated upon by my colleague, Dr. E. H. Nichols.

Digitized by Google

Chin Bee, a Chinese, aged thirty-six years, entered the hospital with retention of urine for which the catheter had been used for several days. Other than this no history could be obtained.

Examination of the urine showed the specific gravity to be 1018, red color, $\frac{1}{2}$ to $\frac{3}{4}$ per cent. albumin, and abundance of normal blood, with many large, round, epithelial cells.

At operation Dr. Nichols found that the sounds were reflected upward and to the right by a large tumor of the left prostatic lobe.

Upon opening into the tumor through the perineum a large amount of gelatinous material was removed, accompanied by severe hemorrhage. The operation was attended by marked shock, for which vigorous stimulation was given. The patient was put to bed with a perineal drain. Three days after operation the patient was comfortable. The bladder was frequently irrigated. He continued to improve for about a week, although there was considerable discharge from the wound, and he was allowed to sit up. Then an attack of diarrhea started, he rapidly lost strength, and died eleven days after operation.

Pathological diagnosis of the tissue removed at operation showed it to be spindle-cell sarcoma.

Digitized by Google

FURTHER CONSIDERATION OF THE SURGICAL TREATMENT OF CANCER OF THE HEAD AND NECK.

By GEORGE W. CRILE, M.D.,
CLEVELAND.

1. Plan of Operation. With splendid operative tools in abundance, the inclined head-up posture to lessen the blood pressure, and the closure of the common carotid artery, hemostasis may now be so perfectly accomplished as to prevent, on the one hand, the contributing factor of the loss of blood to the immediate depression and shock of the operation; and, on the other hand, the unfavorable results possible in the final outcome. With tubage of the pharynx, operations within the mouth or oronasal cavity may be done without inhalation of blood, thereby virtually eliminating the postoperative pneumonia. By this method the head may be placed in any posture most convenient for light and accessibility, and the anesthetizer may be entirely away from the field of operation. Likewise, the protective zone of granulations across the deeper planes of the neck prevents the much dreaded gravity abscess into the mediastinum. Upon these several features, viz., the control of hemorrhage, the minimizing of shock, the prevention of pneumonia and of the gravity abscess of the mediastinum, is based the conclusion that surgery has sufficiently advanced to enable us to individualize operations and disregard set types of the past.

2. Hemorrhage. The far-reaching observations of Gaylord and Clewes, later confirmed by Beebe and Ewing, Erlich and Bashford, that there may be immunity reaction in carcinoma, and that animals that are bled show less resistance to the growth of

Digitized by Google

carcinoma, has a practical bearing in operations for cancer. According to these observations, a patient losing the least blood at the time of operation, other things being equal, would have the best chance for permanent cure. I have gained the impression that this is borne out clinically. To test this point farther, I have begun a series of transfusion of blood at the time of or soon after the operation, for the double purpose of making a more certain convalescence and for the possible advantage of added blood to the patient's resources in his battle against the disease. In addition to the above reasons, a more remote one is worth considering, viz., that certain animals are endowed with a natural immunity to carcinoma, and, though remote, there is nevertheless given the opportunity of luckily finding in the donor's blood such immune bodies which might further assist the patient.

3. The Use of the X-ray. Dr. Hill, of Lakeside Hospital, and others have treated with the *x*-ray a considerable number of cancer cases in various regions of the body. I have seen no good results in the use of the *x*-ray in deep-seated tumors. I have seen superficial growths disappear. Acting upon this, it seemed to me reasonable that when operating for cases of extensive involvement, if one left the wound wide open, the *x*-ray might then be effective against any remaining cancer tissue. I have, therefore, had a series of cases in the past three years treated in this way. That is to say, the day following the operation, if possible, the dressings are removed and the naked wound is exposed to the *x*-ray, and this is repeated daily until the local tissues are brought to a reaction, expressed by an erythema. The treatment is continued until the wound is closed, or at least until the time for skin grafting has been reached. Unless some other factor, such as increased conservatism of blood, or increased care in the wide dissection, is unexpectedly operative in the group of cases thus treated by the *x*-ray, I cannot but feel that it has played a certain, perhaps not unimportant, role in the result.

4. Relative Value of the Tissue Sacrificed. In the cancer period of life the occlusion of the common carotid and the internal carotid arteries is often followed by such a high percent-

Digitized by Google

age of cerebral softening that in the last 100 or more cases I have not permanently closed either one. Then, too, it is extremely fortunate that a carcinomatous growth almost never involves the sheath of the artery. The ligation of the external carotid artery in itself is a matter of importance, as it carries with it a 2 per cent. risk of cerebral embolism by having the thrombus washed away by the blood stream of the common and internal carotid. The jugular veins, one or both on a single side, or one or both on both sides, may be excised with safety the entire length of the neck. There is such an abundance of veins in all directions in all parts of the neck that this may not be considered. I have many times removed the sternomastoid and twice removed the entire sternomastoid from both sides. This inconveniences the patients to a surprisingly small degree. The omohyoids are of minor consequence. This is true of the digastric, the sternothyroid, the sternohyoid, and the platysma. The functional importance of one or all of these muscles is so well compensated for by other and deeper muscles, and, at all events, is so trifling as compared with the importance of any advantage their removal might have in the cure of the disease, that they need not be considered.

As to the scar, a patient who is cured of cancer of the head and neck will have very little concern about any scar that might be left.

Unilateral excision of the vagus is attended by little other than a hoarseness of the voice. Bilateral excision is of course uniformly fatal. Unilateral excision of the phrenic is followed by less than one-half paralysis of the diaphragm, but is rarely necessary. Likewise, the unilateral excision of the hypoglossal is of some importance in the use of the tongue in speech, but a fair degree of compensation may be acquired. Bilateral excision is generally fatal, on account of pneumonia following. Fortunately, it rarely becomes necessary to excise the phrenic, the vagus, or the hypoglossal even in extreme cases.

I would, therefore, advance the following propositions:

1. That the operative technique of this field has reached the point of development which enables the surgeon to operate each case individually, with sole reference to excising every particle of

Digitized by Google

the malignant growth and in no way recognizing the so-called types of operation, such as Whitehead's, Kocher's, etc.

2. That the loss of blood plays an important role in the remote as well as in the immediate results.

3. That the immediate use of the *x*-ray applied upon the naked wound is useful.

4. That the only tissue that must be respected, to the extent of determining the breadth of the excision of the growth, is the common or internal carotid artery; that the sternomastoids, one or both, the omohyoids, the digastric, the sternothyroid, sternohyoid, and platysma muscles, either on one or both sides, need not be considered as of functional importance in weighing the chances for a successful eradication of a malignant growth. On the same ground, neither the internal nor external jugular on one or on both sides need be considered, nor the unilateral excision of the vagus, phrenic or hypoglossal.

5. That the creation of a granulation barrier across the base of the neck under cocaine nitrous oxide anesthesia, by the packing of iodoform gauze in the deep planes of the neck prior to operation, protects with almost certainty the mediastinum.

6. That the immediate operative risk has fallen to a minimum.

7. That the chances for final cures compare favorably with that of cancer of the breast.

Digitized by Google

LOCATION OF THE GROWTH.

Location.	Operations.
Epithelioma of lateral margin of eye	6
Carcinoma of face (including maxillæ)	18
Carcinoma of lips	37
Carcinoma of floor of mouth	4
Carcinoma of soft palate	2
Carcinoma of alveolar process	2
Carcinoma of pharynx	1
Carcinoma of tongue	14
Carcinoma of tonsil	2
Carcinoma of nose	5
Carcinoma of scalp	2
Carcinoma of lymphatic glands	28
Carcinoma of parotid	5
Carcinoma-branchiogenic	4
Carcinoma of larynx	15
Carcinoma of thyroid	5
Total	150

No fatality in last 40 operations. Total number of operations, 150 on 135 patients.

33 operations on 31 patients between 1900–1904.
30 patients traced.
12 patients no recurrence, or 40 per cent.
18 patients dead from carcinoma, or 60 per cent.
1 patient not traced.
55 operations on 48 patients *previous to* 1900.
35 patients traced.
11 patients no recurrence, or 31 per cent.
23 patients dead from carcinoma, or 65 per cent.
13 patients not traced.

Digitized by Google

DISCUSSION.

DR. A. T. BRISTOW, of Brooklyn.

A year ago this month I operated upon a patient for carcinoma of the larynx, removing the whole larynx and epiglottis, and found the pharynx involved. I removed the involved portion of the pharynx, and then left the wound open, intending immediately upon the patient's recovery to submit it to the *x*-rays, knowing that in superficial growths alone was this warranted, and I hoped to make the growth superficial by leaving the wound open. I expected prompt recurrence. I saw him in November again and was surprised to find at that time that all the parts were healed, and the only evidence of local recurrence was a small sinus which reached down to the pharynx. I then made what I now know to be a great blunder. I put a small probe, under cocaine, into that sinus and curetted it.

Following the curettage evidences of recurrence became manifest, and in spite of *x*-ray treatment the tissues of the neck became involved. Beard's treatment seemed also to have no effect. I mention this case because I think that the evil result was delayed by the wound being left open and the deep tissues exposed to the *x*-rays.

DR. ALBERT VANDER VEER, of Albany.

Progress is certainly the watchword in anything that Dr. Crile offers us. For the past few years I have, in operating for removal of extensive malignant growths about the neck, also the tonsils, tied the common carotid, in some cases applying two ligatures, thus severing the proximal and distal ends. I have not made the incision of which he speaks, but have no reason to regret the time consumed in tying the common carotid. I want to indorse this paper, for although my operative work in this direction is about over, yet I feel that we have had added to our experience something of great value, by one who is so careful in his investigations.

Digitized by Google

ACQUIRED DIVERTICULITIS OF THE LARGE INTESTINE.

By WILLIAM J. MAYO, M.D.

IN COLLABORATION WITH

LOUIS B. WILSON, M.D., AND H. Z. GIFFIN, M.D.,
ROCHESTER, MINNESOTA.

DURING the past eleven years a certain group of cases has been observed clinically, but they have not, until recently, been placed upon a sound pathological basis. The cases of this description, which have come to our notice are as follows:

In 1896 a well-nourished man, aged fifty-one years, presented himself at our clinic with an internal fecal fistula into the bladder. The history in brief was that some months previously he had been seized with pain and soreness in the left inguinal region, and a tumefaction followed. After a number of weeks of illness there was a spontaneous evacuation of a large amount of foul pus by way of the bladder. The tumor disappeared, but from that time there had been more or less escape of gas and feces into the cystic cavity.

A diagnosis was made of probable appendicitis abscess, with secondary internal fistula. Upon opening the abdomen the appendix was found normal, but in the sigmoid flexure of the colon was a considerable sized sausage-shaped tumor embedded in a mass of adhesion, and a fistula existed between the sigmoid and the bladder. This was divided, the opening into each viscus sutured, and free drainage introduced. The suturing proved imperfect, and a combined urinary and fecal fistula to the surface was the result.

Digitized by Google

The bladder opening healed in a few weeks, but when the patient was last seen, two years after the operation, the fistula occasionally discharged gas and hard particles of feces.

Second and third cases of the same character have since been under our care. The colon, which has been concerned, is that part which stores waste products for intermittent elimination, and lies distal to the splenic flexure.

In addition to these 3 cases of internal fistula, several patients have presented themselves with abscess or external fistula having the same etiology. One, a physician, very fleshy, had been suddenly taken sick with what he described as "like an appendicitis on the left side." After a number of weeks a large abscess formed. This was evacuated by an abdominal incision. Since that time there has been a small fecal fistula to the surface of the body, which would nearly heal and then be followed by an exacerbation, with the escape of a purulent fluid containing one or more small hardened fecal masses about half the size of a pea. Under the belief that it was in some way connected with the appendix, this organ had been removed by the surgeon in charge, and found to be normal, the seat of the disturbance being located in the sigmoid.

Another case was that of a male who had two years before been operated on for acute appendicitis, and who said that the present trouble was exactly like that of his attack of appendicitis, except that it was located on the left side.

In 5 instances patients have presented themselves with a well-marked tumor in the left side, which in 3 cases had appeared suddenly with inflammatory symptoms; obstruction of the large intestine had resulted. In all 5 the colon was resected, and in each the gross appearance in situ was that of carcinoma. Examination of the removed specimens, however, showed that no malignant disease was present.

But not all of these cases go on to the production of such serious symptoms. We have had a small number of elderly, and usually obese, patients who have been suddenly attacked with severe pain in the left side. An indefinite tumefaction would appear. After a

Digitized by Google

thorough evacuation of the bowels the trouble would subside, though the feeling of tenderness and resistance on deep palpation would last for several weeks. In two of these individuals there have been one or more relapses.

All the patients coming under observation have had certain features in common. They were over forty-five years of age; all but 4 were males, and, excepting for this illness, were otherwise robust in health, most of them inclined to obesity. The onset of the symptoms was sudden, and presented the characteristics of a localized peritonitis. A tumor rapidly developed, and usually lay to the left of the median line in the middle or lower quadrant of the abdomen.

In all of the cases the disease has originated in the descending colon and sigmoid, between the splenic flexure and the rectum structures which are derived from the primitive "hind gut."

The cases briefly cited above naturally drop into three clinical groups: First, those in which an intraperitoneal abscess forms, with spontaneous evacuation into a neighboring viscus, or evacuation externally by means of operation; second, those cases giving rise to acute or chronic obstruction necessitating operation; third, those in which the symptoms are mild and recovery occurs spontaneously.

SURGICAL TREATMENT.

The surgical treatment of diverticulitis of the colon depends upon the condition present. First, localized suppurative cases must be treated by free drainage. If, in conjunction with the infective process, acute obstruction of the bowels develops, as in the cases reported, a temporary artificial anus should be made, and if necessary, after the infection has subsided, the involved colon may be resected. Second, if a considerable tumor is present, and the symptoms do not show a tendency to disappear, it is better to make a primary resection of the affected part of the bowel before abscess and fistula supervene to render patients prolonged invalids.

In all of the cases which we have resected the disease has been limited to from four to eight inches of the gut, and all of those that

Digitized by Google

recovered from the operation have remained in perfect health. The milder cases, which tend to spontaneous recovery, do not suggest operative treatment.

Dr. L. B. Wilson will discuss the pathology of these cases and Dr. H. C. Giffin the clinical course.

Report on the Pathological Examination of Five Cases of Diverticulitis and Peridiverticulitis of the Sigmoid. By Dr. Louis B. Wilson.

Case I (H1903).—The specimen of sigmoid resected in this case was about 16 cm. long (Fig. 1). The mesentery contained a hemispherical nodular mass, 1 to 4 cm. thick and 7 cm. in transverse diameter. This mass consisted of two diverticula, swollen glands, and inflammatory exudate. On section, one of the diverticula (Fig. 2) was found to have ulcerated almost through into the peritoneum. Its walls had sloughed and presented ragged, overhanging edges, leading to a provisional diagnosis of carcinoma. Microscopic examination, however, showed no carcinoma.

The other diverticulum (Fig. 3) had an inflammatory mass 3 cm. in diameter surrounding its base and protruding into the lumen of the bowel about 1 cm. This mass had almost closed the opening into the diverticulum. The diverticulum contained an irregularly shaped enterolith.

The walls of the diverticulum consisted of the following coats:

1. Mucosa, markedly atrophied around the proximal end of the lumen, where pressure had been greatest from the thickened gut walls, and fairly well preserved around the sacular portion.

2. Submucosa, a strong fibrous coat thicker in the proximal than distal portion.

3. Muscularis, fibers derived from the circular coat of the sigmoid, and thickened by fibrous infiltration to twice the thickness of the same coat in the normal portion of the sigmoid. The muscularis in the sigmoid wall, where penetrated by the diverticulum was much thicker.

4. A layer of fibrous tissue from the subserosa.

Digitized by Google

CASE II (16736).—The portion of sigmoid removed was about 20 cm. long and 7 cm. thick. The lumen was so reduced that it was with difficulty that a glass rod 1 cm. in diameter could be passed through it. The specimen had the roughened external appearance and hard nodular feel of a carcinoma of the sigmoid. Sections showed the walls to consist, beside the thickened muscularis, of a fat-infiltrated, inflammatory mass, mostly in the subserosa, and containing multiple diverticula. On dissecting away the tissue from about the diverticula (Fig. 4) they were found to be small, thin-walled, and many of them containing in their sacculated extremities, hard, black enteroliths. Examination of the walls of ten of the diverticula showed no muscularis whatever. Their hernial nature was further shown by the fact that all had penetrated the haustra of the sigmoid well away from the teniæ of the longitudinal muscularis.

Careful examination of the circular muscularis showed areas of marked thinning, even where no diverticula had developed. None of the diverticula gave evidence of marked inflammation within the lumen.

CASE III (18856).—The portion of the sigmoid removed was about 15 cm. long and 5 to 8 cm. thick. The diameter of the lumen was much reduced. The wall showed the results of a chronic inflammatory process in its thickened submucosa, muscularis, and subserosa, the latter being infiltrated with fat. There were marked hyperplasia in all the glands removed. Immediately after the operation a large portion of the inflammatory mass was divided into blocks for histological examination, both in this laboratory and in the laboratory of the patient's home physician, so that the exact number of diverticula penetrating the sigmod wall was not accurately determined. However, when the specimen was later dissected, two typical examples of small, false diverticula were found (Fig. 5). One of these contained an enterolith. The other, though sacculated, contained none. There was no evidence of inflammation within the lumen of either. The walls of both were quite thin and devoid of muscularis. Besides these two fully developed diverticula, several small pocketings of the mucosa were

Digitized by Google

present. At each of these the circular muscular fibers were markedly fewer than in surrounding areas.

CASE IV (19305).—The resected portion of the sigmoid in this case was about 17 cm. long and 6 cm. thick. The thickening was due to chronic inflammation, principally in the muscularis and subserosa, into which had penetrated numerous diverticula (Fig. 6). The circular muscular coat contained many thinned areas, in some of which, indeed, the muscular fibers seemed to be entirely absent. In these tumors there was always pocketing of the mucosa and submucosa, with usually compensatory hypertrophy of the inner fibers of the subserosa.

All the diverticula were small, with more or less atrophied mucosa (Figs. 7 and 8, and sketch 9), thickened submucosa and no muscularis. Their distal ends were well surrounded with the markedly increased fibers of the inner portion of the subserosa. Many contained enteroliths. None showed inflammation within the lumen. None perforated into the bands of longitudinal muscle fibers. Recent infection with bacilli tuberculosis was demonstrated in the enlarged glands in the specimen, and later elsewhere in the peritoneum when the case came to autopsy.

CASE V (20202).—The specimen of sigmoid in this case was removed thirteen days after its fixation (2-stage Mikulicz operation), and was, consequently, too necrotic to permit of satisfactory histological or gross anatomical examination. Its general appearance is shown in Fig. 10. It was about 20 cm. long and 10 cm. thick. The walls were thickened with old inflammatory deposits about numerous diverticula. The diverticula were all small and apparently devoid of muscularis in their walls.

SUMMARY.

It will thus be seen that of the five specimens herewith reported one contained a true diverticulum and four only false diverticula. It is possible that the true diverticulum (Fig. 3) may have been congenital, though the relation of the layers of its wall to those of the

Digitized by Google

sigmoid makes the supposition scarcely tenable. One diverticulum (Fig. 2) in this case had formed a sloughing ulcer, simulating in its symptoms and in its gross anatomy an ulcerating carcinoma.

The diverticula in the other 4 cases were all of the small, multiple, false variety. All were simple herniæ of the sigmoid walls passing through the circular muscular coat at points where its fibers were deficient. It was impossible to determine accurately whether this deficiency of the muscularis of the sigmoid walls was congenital or the result of atrophy from the pressure of fecaliths or constipation. It would seem, however, that a congenitally defective musculature slowly yielding to increased internal pressure would readily produce the anatomical conditions found.

The large inflammatory deposits about the diverticula were undoubtedly caused by chronic leakage through the diverticular walls. It is noteworthy that this inflammatory reaction was much greater around those diverticula which extended well through the muscularis, and which contained enteroliths. This is well shown in Fig. 7, an enlarged view of a portion of the sigmoidal wall in Case IV. Here is seen a small diverticulum protruding well through the muscularis and containing within its almost occluded lumen an enterolith. Around it is an inflammatory mass three times as thick as that around a much larger diverticulum in its immediate neighborhood, but which scarcely penetrates the muscularis, is still well open into the lumen of the sigmoid, and contains no hard fecal concretion. This one section would seem to go far toward explaining not only the etiology of the diverticula, but also of the secondary peridiverticulitis.

It would seem worth while to draw a sharp distinction between the acute ulcerative process within the diverticula in Case I and the chronic inflammatory process confined to the tissues surrounding the diverticula in the other cases. The former is a lesion, primary in the mucosa, caused by bacteria to which it is not immune; the latter, only an inflammatory reaction of the peritoneum set up by the leaking through the diverticular walls of toxins, or bacteria, with the presence of which the mucosa is constantly familiar. The former causes no material reduction of the lumen of the bowel; the

Digitized by Google

latter, a very marked reduction with chronic obstruction. The former tends to acute perforation into the peritoneal cavity, while in the latter the reparative process is so predominant that rarely should perforation occur. Finally, if we are to speak accurately we should apply the term "diverticulitis" only to cases of the former type, that is, *acute inflammations of the mucosa within the diverticula*, while the cases of the latter type, that is, *chronic inflammations of the subserosa around the divericula*, should be designated "peridiverticulitis."

The Clinical Course of Acquired Diverticulitis of the Large Intestine. By Dr. H. Z. Giffin.

Acquired diverticula may be "true" or "false," the "true" consisting of all the layers of the intestinal wall, the "false" being hernial protrusions of mucosa through musculature. Traction caused by tumors, or by adherent organs, is probably the most common cause of the "true" variety. The "false" are most likely the result of excessive pressure from within the intestine, combined with a congenital weakness of the bowels.

Acquired diverticula of the large intestine are more common than those of the small, and pathological changes occur in them much more frequently. They are usually multiple and may arise from any part of the surface. Some authorities have tried to show that the mesenteric border is the weakest part of the bowel and that diverticula form here more readily. This seems to be true in the dead bowel, when bloodvessels are not distended and resistant; but the experiments of Chlumsky[1] demonstrate that upon distention of the living bowel, rupture generally occurs at some point opposite the mesentery.

Diverticula often extend into the epiploical appendages and may account for some of the tenderness found in many portions of the gut.

According to a table compiled by Gordinier and Sampson,[2] acquired diverticula of the large intestine were recorded in 64 ex-

Digitized by Google

aminations out of 8132 autopsies at the hospial of the city of Dresden; in 19, out of 2600, at the Johns Hopkins Hospital; in 2, out of 953, at the Bender Hygienic Laboratory, and in 1, out of 2382, at the Boston City Hospital. It is probable that general interest and careful investigation will show that they occur much more frequently than supposed.

ETIOLOGY.

Constipation is considered an important factor in the production of diverticulitis. Hardened feces, becoming impacted in a diverticulum, may be the cause of beginning irritation, and possibly of ulceration. This is probably one reason why diverticula of the large bowel undergo pathological change so much oftener than those of the small, and why the sigmoid is so commonly affected.

Most of the cases occur in persons beyond middle life; the majority are over the age of fifty. The fact that this is the cancer age is productive of obscurity in diagnosis. One of our probable cases, whose age was thirty-nine at the time of examination, gave a history of trouble beginning at fifteen. All other cases were of more advanced age, and of much shorter duration—eleven days to two years.

There is apparently no particular reason why some disturbance should not occur early in life, nor why the cases should not be of longer duration.

There seems to be a notable general tendency to obesity. One might conceive this to be a proper concomitant of weakened intestinal musculature.

Chronic passive congestion has been mentioned as a factor in the production of diverticula themselves and also in the causation of disease in them.

Dilated veins give a sieve-like character to the intestinal walls and internal pressure may cause herniæ through the weakened areas. Moreover, after diverticula are formed, improper nourishment will foster inflammatory change.

At our clinic, five cases have been seen in which, after resection,

Digitized by Google

the diagnosis has been made certain by pathological examination. Indeed, this is the only way in which one can arrive at a positive diagnosis.

CASE I was operated upon May 1, 1902, for supposed carcinoma of the sigmoid. O. A., male, aged forty-one years, first noticed a tumor in the lower part of the left side of the abdomen five months before admission to the hospital. The patient had lost thirty pounds, was anemic, and practically all of the five months had suffered from pain in the lower part of the abdomen. There had been no urinary disturbance. A tender, hard, irregular, but movable, mass was discovered in the left lower quadrant. Six inches of the sigmoid and descending colon were resected. The distal end of the bowel was closed, dropped in, and an artificial anus formed by the upper end. The patient was discharged in eighteen days, evidently in a satisfactory condition.

CASE II.—J. W., a woman, aged sixty-two years, was examined by Dr. C. Graham, on November 18, 1905, having been referred by Dr. Caldron, of Mumford, Iowa. Her family history was negative, and she had passed through her menopause at fifty-two, during which time there had been considerable uterine bleeding. For a few years previously there had been noticed at times a sensation of pressure in the lower abdomen, which was relieved only by drastic catharsis. Pelvic pains of an indefinite character had been complained of for a year. On the whole, however, the history was rather negative. Examination disclosed a moderately large mass low down in the left side of the pelvis, and a tentative diagnosis of ovarian tumor was made. At operation the mass was found to arise from the sigmoid. A resection of eight inches of the bowel was performed and followed by an end-to-end suture anastomosis. A pathological diagnosis of fibrolipoma, diverticula, with ulcerating fecaliths, was made. The patient recovered satisfactorily.

It will be noted in this case that there was considerable history of constipation. There had been no attacks of abdominal pain, however, and instead of a mass being found in the left iliac fossa there was one in the left side of the pelvis. These same points may be noted in Case IV, a woman, and in Sampson's case, also a woman.

Digitized by Google

The male patients we have seen presented a mass higher up. This may be due to the fact that the woman's pelvis is roomy and the sigmoid movable.

CASE III.—J. W., male, aged fifty-five years, weight about 150 pounds, was examined on June 19, 1906, by Dr. W. J. Mayo. The patient gave a history of some gastric flatulence for a year preceding. On June 2 he had noticed some general abdominal pain. Two days later he had a slight chill, and his temperature rose to 101.5°. A tender, sausage-shaped tumor was discovered in the left iliac fossa. There had been no severe, acute, abdominal colic. General pain and localized tenderness continued, and the mass gradually decreased in bulk, until at the time of examination it was about one-half of its original size. The patient was eight pounds under weight. At operation, seven inches of the sigmoid were resected for fibrolipoma, secondary to an ulcerating fecalith. An uninterrupted recovery followed and the patient is now doing well.

It will be noted in the above case that the onset was sudden and the formation of tumor rapid. The attack of abdominal pain was not as sharp as in appendicitis, nor was there vomiting. Indeed, the absence of vomiting seems to be a common thing unless the attack of pain is very acute.

CASE IV.—W. J. M., a woman, aged fifty-two years, was examined by Dr. C. Graham on July 31, 1906. She had had typhoid fever twenty-five years previously. There was a history of marked obstruction and it had been nearly impossible to secure bowel movement. Five years before there had been an operation for ovarian cyst, and some complaint had continued ever since. Intermittent stomach trouble of a mild degree had existed for years. The patient had suffered from periodical attacks of pain across the lower bowel for five or six months, these spells lasting four or five days, never severe, and not accompanied by vomiting. She was twenty-five pounds below her normal weight. Examination disclosed a left-sided pelvic tumor. At operation, which was done mainly on account of obstruction, the mass was found to be in the sigmoid. This was resected. Pathological examination revealed

Digitized by Google

a large number of diverticula, some of them ulcerating. There were tuberculous glands upon the peritoneal surface, apparently a secondary infection. The patient died eighteen days after operation from general peritonitis, as postmortem examination showed.

CASE V.—W. S., aged fifty-two years, male, was examined by Dr. H. S. Plummer on January 19, 1907. Five months previously he had, for a week, complained of some pain and nausea. About three weeks before the examination the patient was attacked with severe pain and some fever lasting two days. There was no constipation and no blood was to be seen in the stools. Dr. Truesdale, of Fall River, Mass., who referred the case to us, had found a mass. There had been a loss in weight of about twenty-six pounds, with symptoms of obstruction. The patient was very well nourished, weighing over 200 pounds. The possibility of diverticulitis was mentioned upon the clinical report. At operation, ten inches of the descending colon and sigmoid were resected. The patient died on the thirteenth day of general peritonitis, as was shown by postmortem.

Beer,[3] in 1904, collected 18 cases of inflammatory disease of the large bowel. S. C. Plummer[4] reported 1 case in 1906. The addition of the above 5 cases of undoubted diverticulitis makes a total of 24. Many cases are reported which, in the light of present experience, might be considered diverticulitis. Surgeons have at times explored the abdomen, and finding what seemed to be an unremovable carcinoma of the sigmoid have sewed up, expecting a progressively downward course. To their surprise a marked improvement has followed. The mass has gradually disappeared, and the patient occasionally attained even perfect health.

In other instances a colostomy has been made above a supposedly malignant obstruction, and a surprisingly great improvement has followed. Some of these cases have even been reported as cures of cancer. On the other hand, one must be careful not to consider every left-sided pain as evidence of this malady until we have seen a greater number of positive instances and have become more familiar with the milder symptoms.

The foregoing five cases must be distinctly separated from the

Digitized by Google

Digitized by Google

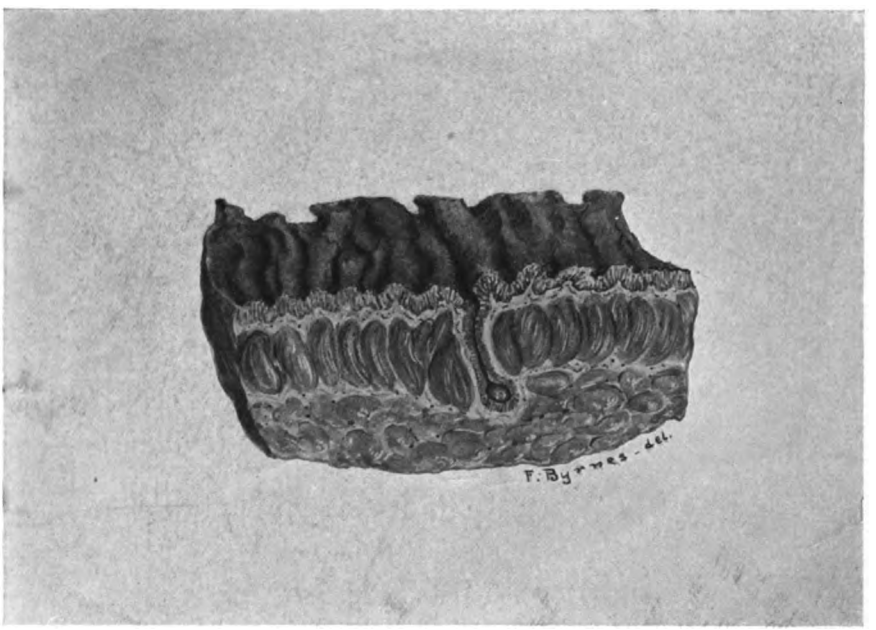

FIG. 9.—Peridiverticulitis. Case IV. (19305.) × 1 diam. Sketch of diverticulum with inflammatory deposit in subserosa.

Digitized by Google

EXPLANATION OF PLATES

(See stereoscopic plates in pocket at back of volume.)

FIG. 1.—Diverticulitis. Case I. (H 1903.) × ⅔ diam. Sigmoid laid open longitudinally. A diverticulum containing a sloughing ulcer is seen at the lower right hand; another is sectioned near the label needle.

FIG. 2.—Diverticulitis. Case I. (H 1903.) × 1 diam. Section through ulcerated diverticulum shown in Fig. 1.

FIG. 3.—Diverticulitis. Case I. (H 1903.) × 3 diam. Enlarged view of sectioned diverticulum shown in Fig. 1. Note muscularis in wall, occluded lumen, and inflamed submucosa.

FIG. 4.—Peridiverticulitis. Case II. (16736.) × ⅔ diam. Inflammatory mass, surrounding sigmoid dissected away, showing outer ends of numerous diverticula protruding through the muscularis. Several contain enteroliths.

FIG. 5.—Peridiverticulitis. Case III. (18856.) × ⅔ diam. Specimen shows pocketed mucosa, section of sigmoid wall with defective muscularis, and two diverticula—one having a pin thrust through it and the other with end removed, showing enterolith. The inflammatory mass has been dissected from about the diverticula. A swollen gland is shown.

FIG. 6.—Peridiverticulitis. Case IV. (19305.) × ⅔ diam. Sigmoid divided longitudinally. Note defective musculature and the diverticula. Inflammatory mass dissected away near label needle.

FIG. 7.—Peridiverticulitis. Case IV. (19305.) × 2½ diam. Enlarged view of two diverticula, and one point of defective musculature seen in Fig. 6.

FIG. 8.—Peridiverticulitis. Case IV. (19305.) × $3\frac{3}{10}$ diam. Enlarged view of the diverticula, one of which is seen in Fig. 6, the other having been exposed by removing a thin section from the surface shown in Fig. 5. The inflammatory deposit in the subserosa has been dissected away.

FIG. 10.—Peridiverticulitis. Case V. (20202.) × ½ diam. External view of necrotic portion of sigmoid resected at second stage of operation.

Digitized by Google

Digitized by Google

following group of probable cases. Pathological examinations is the only basis for a positive diagnosis. Even macroscopically, at operation, one cannot surely differentiate it from carcinoma. However, the following 4 cases which have come under our observation simulate diverticulitis so closely that a report of them ought to be of some value.

CASE I.—The history was kindly furnished by Dr. John W. Bell, of Minneapolis. O. C. W., male, aged seventy years, became suddenly ill with chills, fever, and vomiting on February 24, 1906, and a mass was discovered in the region of the sigmoid, on deep palpation. Upon operation an inflammatory condition was found about the sigmoid, and there were adhesions, especially to the bladder. These were freed. The patient recovered and is now in excellent health.

CASE II.—H. C. C., a physician, weight 240 pounds, was examined by Dr. H. Z. Giffin, in July, 1906, and presented an unusually interesting history. The patient's father had died of carcinoma, and the mother of tuberculosis. The patient had been healthy until his fifteenth year, when he had had an attack which was essentially like appendicitis, save that the localization was in the left iliac fossa. Between the ages of fifteen and twenty he experienced intermittently mild paroxysms of pain in the left lower quadrant. When twenty years of age he was put to bed for five weeks with a fever of 104° and 105°, chills, vomiting, distention, obstinate constipation, and severe abdominal pain. After this his general health was good until he was thirty-two years old, when there occurred another attack of abdominal pain, with vomiting and fever, and localization in the left iliac fossa. This was similar to the attack he had had at fifteen. In twenty-four hours a mass as large as a child's head had formed in the region of the sigmoid. Under medical treatment it disappeared in four weeks, and was thought to have been an abscess which had discharged by the bowel. The patient was then quite well for a year. When thirty-three he was kicked in the abdomen by an insane patient, and a small mass formed in the left iliac fossa. There was a large quantity of pus discharged by the urethra. This material was

Digitized by Google

examined every day for a month, but no tubercle bacilli could be found. The patient recovered again under medical treatment, but for some months following there was an occasional fever; then the patient was well for four years. On May 3, 1905, he had his third sharp attack, which resembled appendicitis, but with the localization on the left side. A mass formed in three days. Cystoscopic examination and catheterization of the ureters showed only some redness of the left side of the bladder. An abscess was drained by Dr. J. F. Erdman, of New York. There was a marked improvement and the patient went back to work, but the sinus had persisted to the time of examination. In October, 1905, five months later, there was a fourth attack. A diagnosis of appendicitis with left-sided abscess was made. A median incision by Dr. Erdman disclosed a normal appendix. A small amount of pus was obtained and the sinus resulting from this had also persisted up to the time of examination. Occasionally there had been a discharge of material having a fecal odor, and twice fecaliths had been obtained. The bowels had been moving quite satisfactorily and the patient was very well nourished, markedly inclined to obesity and able to work, having lost but three days on account of a mild attack of pain and fever since examination in July, 1906. The fistulæ still exist.

CASE III.—M., a Bohemian, aged fifty-one years, male, presented himself in 1896, with symptoms of an enterovesical fistula. There was a history of symptoms similar to appendicitis, save that the localization of the pain was on the left side. His condition improved for a while but later became worse, and a mass, which was quite tender, developed low down in the left side of the abdomen. A discharge of pus with a fecal odor occurred by urethra, and continued, though the bowels were moving naturally. A diagnosis of appendicitis with left-sided abscess was made. At operation, however, the appendix was found to be normal, but in the pelvic portion of the sigmoid there was a moderately large sausage-shaped tumor embedded in a mass of adhesions and attached to the bladder. This was stripped away, and an attempt made to close both the bladder and the bowel openings. Combined fecal

Digitized by Google

and urinary fistula developed in a week. The urinary fistula healed by granulation rather promptly, but the fecal fistula persisted, and when the patient was last seen, two years afterward, there was still occasional discharge of gas and hardened fecal masses.

CASE IV.—P. V. R., a clergyman, aged sixty-three years, weighing 260 pounds. The history was furnished by Drs. J. B. McCaughey and W. F. C. Heise, of Winona, Minnesota. The illness dated from August, 1905, when there were occasional attacks of moderately severe pain across the lower abdomen, associated with diarrhea. These attacks grew worse in December, 1905, and in January, 1906, he was taken down with fever ranging from 99° to 102°, which continued three weeks. During this time there had been two spasmodic attacks of pain which required morphine. The pain was localized in the left inguinal region, and seemed as though it might have been due to a stone passing through the ureter. There was, however, no blood or gravel in the urine. After the disappearance of the fever there occurred a third similar attack. The pain continued intermittently during the spring, and in midsummer the patient started for Europe in the hope of improving with change of scene and climate. In August the pain became worse, and during the latter part of September a swelling and a tender area developed in the left inguinal region. The patient's physician in Berlin advised him to return home. Upon his arrival, in the latter part of October, he was found to be twenty pounds under weight, and an indurated area, apparently inflammatory, had developed along the course of Poupart's ligament, extending into the testicle. Upon lancing this, pus, blood, gas, and fecal matter were obtained. Five or six days later an intestinal obstruction ensued, and was relieved by colostomy on October 28, 1906 (operation by Dr. W. J. Mayo). There followed an immediate improvement both in local and in general conditions. Six weeks after operation the bowels moved, per rectum, for about three weeks. Since then the feces have passed per rectum intermittently. The pelvic abscess continued to discharge pus and blood until March 21, 1907. The colostomy wound has been

Digitized by Google

gradually growing smaller. The patient complains of pain when constipated, and there is some hurry in urination. There was so much urinary disturbance at one time that a stone in the bladder was suspected. Cystoscopic examination was done by Dr. M. C. Millet, but proved to be negative. The patient has now regained most of his loss in weight, and is gradually getting back to his work.

We have presented five *positive* and four *probable* cases of diverticulitis. All of the positive cases and most of the probable ones were over forty years of age, and all were within the common cancer limit. Of the positive cases, two (women) presented left-sided pelvic masses with obstructive symptoms, and in three cases (men) there were left iliac tumors with abdominal pain localized in the left lower quadrant. The history of acute attacks of abdominal pain, first general and then localized in the left iliac region, with or without vomiting, is striking.

Of the probable cases, three proceeded to abscess formation, two had enterovesical fistulæ, and one caused a complete stenosis.

Beer[3] classified the cases which he had collected into: First, those which produced stenosis, of which there were six instances. Second, those in which perforation into the peritoneum had occurred. He draws attention to the fact that the sigmoid should be examined in all cases of perforative peritonitis when in doubt as to the source. Third, those which led to abscess formation. Fourth, those with intestinovesical communication. In 20 cases of these fistulæ, Chavannaz found 9 inflammatory, 5 tuberculous, 4 carcinomatous, and 2 traumatic. The frequency of the inflammatory form will be noted. Fifth, those which seemed to show some causative relation between diverticula, mesenteritis, and volvulus of the sigmoid. Sixth, instances of appendicitis in which diverticula had been found in that organ. Seventh, those in which carcinoma had apparently developed in false diverticula. Hochenegg[5] has reported one such case.

Digitized by Google

CLINICAL DIAGNOSIS.

A clinical diagnosis of diverticulitis cannot be made positively. Left-sided pain, low in the abdomen, coming in intervals and associated with constipation, brings it to mind. The occurrence of a more acute abdominal pain, general at first and later localized to the left iliac fossa, would suggest it very strongly. The rather sudden formation of a mass in the left lower quadrant following such an attack of pain would make the diagnosis yet more probable. Carcinoma would have been more gradual in growth, but this point cannot be relied upon, from the fact that the patient may not have noticed such a mass at its beginning. The occurrence of blood mixed through the stools is an important sign in favor of carcinoma. Only one of our cases was correctly diagnosticated.

The following case is instructive from a diagnostic standpoint: J. T., aged fifty-three years, was examined by Dr. H. Z. Giffin on July 30, 1906. There was an old history of stomach trouble suggesting ulcer. Two weeks previously to examination he had had a severe attack of epigastric pain, colicky in character, coming on and disappearing suddenly. Morphine was required. Three more attacks, lasting about twenty minutes each, followed during the day. Eleven days before examination the patient had noticed tenderness and the formation of a mass in the left lower quadrant. Repeated irrigation of the bowel failed to remove this. He had been having six or seven stools a day, none containing blood. He had lost about twenty pounds in two weeks, but had eaten nothing. Sigmoidoscopic examination was negative, the mass being too high. The hemoglobin was 90 per cent.

From the above history one would have expected an inflammatory growth, but at operation a cancer of the descending colon and sigmoid was found and excised. It is impossible to tell even by the gross appearance of such a tumor whether it is inflammatory or malignant. Microscopic examination alone can positively diagnosticate the condition. In women one must think of the possi-

Digitized by Google

bility of diverticulitis upon finding a left-sided pelvic tumor, especially if associated with much bowel trouble.

Actinomycosis of the sigmoid may occur. Tuberculous peritonitis may be localized in this region. Appendix abscess may be left-sided, and chronic sigmoiditis may cause a thickened and palpable gut. In these instances the previous history will generally give a clue. It is also said that normal epiploical appendages may be enlarged, tender, and suggest the existence of a mass.

Bibliography.

1. Chlumsky. Ueber verschiedene Methoden d. Darmvereinigung. Beitr. z. klin. Chir., 1899, Band xxv.

2. Gordinier and Sampson. Diverticulitis Causing Intestinal Obstruction. Jour. Amer. Med. Assoc., May 26, 1906, vol. xlvi, pp. 1585–1591.

3. Beer. Some Pathological and Clinical Aspects of Acquired Diverticula of the Intestine. Amer. Jour. Med. Sci., vol. cxxviii, p. 135.

4. S. C. Plummer. Technique of Removal of Tumors of the Large Intestine, Causing Obstruction. Surg., Gyn. and Obstet., June, 1906, vol. ii, pp. 696–697.

5. Hochenegg. Thirty-first Congress of German Surgeons.

Digitized by Google

THE DIVERTICULUM ILEI AS A CAUSE OF COMPLETE INTESTINAL OBSTRUCTION IN A MANNER HITHERTO UNDESCRIBED.

By FREDERIC HENRY GERRISH, M.D.,
PORTLAND, MAINE.

COLLECTIVE investigation of the surgical bearings of the diverticulum ilei has been recently made with so much care as to render superfluous a review of the main subject at this time. Abdominal crises, due to misbehavior of the diverticulum, are not, however, so frequent that they have ceased to attract attention, either on account of the way in which they cause trouble or the necessity which they occasion for surgical interference; and it seems to be a duty to report all such cases in the hope that light, at present conspicuously lacking, may be thrown upon their diagnosis without resort to abdominal section. The purpose of this paper is to report a case in which the diverticulum established such relations with neighboring parts as to cause complete obstruction of the intestinal tube (a rather common effect of diverticular eccentricity), but did this in a manner which, as far as I have been able to learn, is perfectly unique.

On March 23, 1906, I went to Freedom, N. H., by invitation of Dr. G. W. Lougee, to see the case. The patient was a vigorous male, twenty years old. For four days he had had no defecation, although previously there had been no recognized intestinal difficulty. Cathartics had been administered until they were found to be worse than useless. Many enemata had been given, with no result, except that the last one brought away a little mucus slightly tinged with blood. The pulse was of good quality, the temperature substantially normal, and the moral tone of the patient excellent. Examination of the belly showed that the large

Digitized by Google

intestine was empty, the small considerably, but not extremely, distended. The opinion was expressed that there was complete obstruction near the lower end of the ileum; but I was unable to make a closer diagnosis. I confess that the possibility of the real cause did not occur to me.

The abdomen was opened in the right linea semilunaris. The obstruction was readily found at about 50 cm. from the ileocecal junction. The intestine proximal to this point was distended and highly congested; the distal portion was empty, shrivelled, and very pale, with a bluish tint. The occlusion was caused by the passage of a diverticulum from right to left through an arched opening in the attached border of the mesentery, and its retention in this abnormal situation by a prolongation of its free end into a slender cord, which extended ventrocaudally to the anterior abdominal wall. The precise point of attachment of this cord was not determined, as it broke on gentle manipulation, and the practical needs of the patient so engaged my attention subsequently that this detail was slighted.

The diverticulum was not adherent to the intestine, and was easily withdrawn from the mesenteric opening. Immediately it and the distal part of the ileum assumed the appearance of the proximal portion, becoming equally distended and of a deep-red color. The diverticulum was nearly 10 cm. long, and its diameter was equal to that of the bowel from the free border of which it sprung. It was manifestly unsafe to trust so erratic an organ in the abdomen in view of the vicious tendencies of its kind; and, therefore, I clamped its base with a long hemostatic forceps, placing the blades in line with the longitudinal axis of the bowel, cut it off, sewed the stump with a continuous stitch of chromicized catgut, which included all the coats, concealed the pedicle by depressing it into the lumen of the intestine, and retained it there with a Cushing suture. As the appendix was easily reached and could be rapidly ablated, it also was removed. The abdominal wound was closed without drainage. The subsequent history of the case was so typically satisfactory that its details need not be rehearsed.

Digitized by Google

I do not undertake to explain the production of this very peculiar relation of the diverticulum to the adjacent parts. That it was of recent origin seems unlikely, considering its prolongation to the abdominal wall by a fibrous cord—a condition which obtains in a noticeable, though not exactly ascertained, proportion of cases in which a diverticulum is present. But if this vestigial organ had been in this extraordinary situation for a long time, one is puzzled to understand why it did not cause some appreciable trouble from the beginning of its predicament, especially considering the suddenness of the attack and the completeness of the constriction of the intestine.

With our present knowledge it is impossible to distinguish cases of obstruction which are due in some way to a diverticulum from those depending upon some other causes. Statistics show that the mortality of operations in diverticular cases is very high—a result clearly due to delay in the resort to surgical help. Porter, in his admirable paper,[1] probably does not state the case too strongly in saying that, in proportion to the frequency of its presence, the diverticulum ilei is one of the most pregnant sources of grave abdominal difficulty, and that it is a greater menace to life than an appendix vermiformis. The diverticulum should be removed whenever discovered, unless the condition of the patient forbids the additional risk that its ablation involves. In the latter case the patient should be informed of the existence of the diverticulum, and instructed to invoke competent surgical help on the appearance of any trouble such as can fairly be attributed to this mischievous vestige of the embryonic state.

[1] Abdominal Crises caused by Meckel's Diverticulum. By Miles F. Porter. M.D., of Fort Wayne, Ind. Jour. Amer. Med. Assoc., September 23, 1905.

Digitized by Google

A CONSIDERATION OF THE ETIOLOGY OF CERTAIN CASES OF LEFT-SIDED INTRA-ABDOMINAL SUPPURATION (ACUTE DIVERTICULITIS).

By GEORGE EMERSON BREWER, M.D.,
NEW YORK.

During the past ten years the writer has observed six cases of acute intra-abdominal abscess, all originating in the left lower quadrant, and each presenting symptoms so similar to an acute appendicitis as to lead the observer to consider the possibility of a transposition of the viscera.

The first of these cases occurred at the City Hospital. A middle-aged woman was admitted to the surgical ward, suffering from pain, tenderness, and muscular rigidity in the left inguinal region. The history of the origin of the symptoms was difficult to obtain, but as she regarded the condition as one of acute indigestion, it is probable that it was sudden in its onset, and in the beginning it was associated with nausea and vomiting. When first seen by the writer there was moderate fever, some acceleration of the pulse, and, on careful palpation, a well-defined mass could be felt occupying a position midway between the left anterior superior spinous process and the median line. Operation revealed a well walled-off intraperitoneal abscess, containing about three ounces of foul-smelling pus. There was no escape of gas, and no evidence of a fistulous opening; in fact, the intestines were so matted together with fibrinous exudate that they could not be recognized, and no effort was made to separate them. The wound was closed with drainage, and she made a rapid and satisfactory recovery.

My second case was also seen at the City Hospital. An elderly woman was admitted suffering from pain, tenderness, muscular

Digitized by Google

rigidity, and a mass in the left inguinal region. These symptoms had been present for several days. On admission she had a slight elevation of temperature, and looked moderately septic. The indurated areas in this case were situated somewhat nearer the iliac spine, but in all other respects it clearly resembled the case just reported.

On operation the peritoneal cavity was apparently not opened, the incision, which was quite near Poupart's ligament, leading directly to a large abscess cavity, which contained perhaps eight ounces of thick pus. The cavity, which was freely explored through a large incision, was seen to extend inward, apparently beneath the descending colon, and upper part of the sigmoid; the under surface of the latter apparently forming a part of the roof of the cavity. The bowel wall at this point was covered with a thick, fibrinous exudate, and it was thought by several who saw it that there had been a small perforation which had been closed by the exudate. After the evacuation of the pus the wound was partly closed, and the cavity packed with sterile gauze. She made a slow but satisfactory recovery.

In both of these cases my records are imperfect, and I am obliged to rely largely upon my memory, but I distinctly recall that the cases made a strong impression upon my mind, and that I discussed their possible etiology with several of my colleagues. In the beginning I was strongly in favor of the belief that we had to do with a transposition of the viscera and a left-sided appendicitis. In my second case, however, this theory was easily disproved, as we had a retroperitoneal abscess, which, if it had been caused by a perforated appendix, would certainly have shown some trace of the organ by our careful inspection. My final conclusion was that in all probability the infection took place through some very small perforation of the sigmoid, as from a fish-bone, or other pointed foreign body; or, possibly, through a small area of necrosis occurring in a dysenteric or tuberculous ulcer.

My third case was observed three or four years later at the Roosevelt Hospital. A man, aged sixty years, was admitted to the hospital with a diagnosis of abdominal tumor. On questioning

Digitized by Google

him it was elicited that he had always enjoyed good health, but had been constipated for a number of years. Four weeks before his admission he had complained of more or less severe abdominal pain, which had prostrated him and compelled him to take to his bed. This continued for several days, and, he thought, was associated with some fever. As the pain and fever subsided, he noticed a painful swelling in the left inguinal region, which gradually increased in size until his admission to the hospital, when it was as large as a small cocoanut.

On examination there was practically no muscular rigidity, inspection revealed an oval mass midway between the umbilicus and the anterior spine of the ilium on the left side. This mass was flat on percussion, somewhat movable, smooth on the surface, of the density of an ovarian cyst, and was elastic but not fluctuating. The tenderness to pressure was so slight as to strongly suggest a new-growth rather than an inflammatory mass. This view was also strengthened by the absence of fever.

Under ether anesthesia an exploratory incision was made through the left rectus muscle. The subperitoneal fatty tissue was edematous. On dividing the peritoneum the incision opened into a large abscess cavity which contained nearly a pint of creamy odorless pus. The walls of the cavity were made up of omentum and several loops of intestine, all matted together with a dense fibrinous exudate. The cavity of the abscess was washed out, the wound partly closed by layer suture, and a large drain inserted at the upper angle. He made a satisfactory convalescence.

This case, while it cast no additional light on the etiology of this condition, served to reawaken my interest in the subject.

About this time, in discussing the cases with my colleague, Dr. Evan Evans, he suggested as a possible cause the rupture of a small acquired diverticulum of the sigmoid or descending colon. These diverticula are of fairly frequent occurrence in elderly people, are generally multiple, and, on account of their thin walls, might easily rupture if inflamed or distended by a foreign body.

I therefore made a systematic inquiry of a number of pathologists of my acquaintance, who were making large numbers of

Digitized by Google

autopsies; and, while most of them had seen these diverticula, occasionally present in large numbers, none could recall an instance in which rupture had occurred as a result of pressure of a foreign body organ inflammatory process.

Intestinal diverticula, as is well known, are divided into two general classes—the congenital and acquired (true and false). The most frequently observed type of a congenital intestinal diverticulum is the one known as Meckel's diverticulum. As recently described by Léon Cahier,[1] in his admirable essay upon the subject, a Meckel's diverticulum possesses the following characteristics: It is single; it has a rectangular implantation into the free border of the terminal portion of the ileum, generally in the neighborhood of the ileocecal valve; it is made up of all of the coats of the intestine; it is generally more than 2 cm. in length; and it has a terminal filament which may be free or attached to the abdominal wall, the mesentery or another part of the intestine. The acquired or false diverticula, on the other hand, are, as a rule, multiple small, thin walled, and round or ovoid in shape; they may be found in any part of the intestinal canal, but are more frequent in the left colon and rectum. They are in reality hernial protrusions of the mucous membrane through the separated fibers of the muscular coat.

While the congenital diverticula have been known since the early part of the eighteenth century to be the not infrequent cause of intestinal strangulation, and during the last fifty years to be the occasional cause of peritonitis from gangrene or perforation, the pathological importance of the acquired diverticula in the production of intra-abdominal abscess has been practically ignored by clinicians, and barely mentioned by pathologists.

Wallmann,[2] in 1858, reported 9 cases of acquired diverticula of the colon, of which 1 was in the ascending portion, 3 in the transverse, 3 in the descending, and 2 in the sigmoid. In no instance, however, was there present any other pathological lesion. Leube[3] has described these diverticula as hernias of the mucous membrane, and stated that they occur most frequently along the mesenteric border of the bowel. Klebs called attention to the relationship between these protrusions and the bloodvessels of the bowel.

Digitized by Google

In 1900 Hodenpyl[4] exhibited, in the New York Pathological Society, two specimens of acquired diverticula: one of the duodenum, and one of the colon. The latter (see figure) presented seventy-nine distinct pouches, the majority being in the lower segment of the gut. He expressed the opinion that they were probably due to internal pressure caused by chronic constipation. Other communications on the subject have been made by Max Edel[5] and Graser.[6]

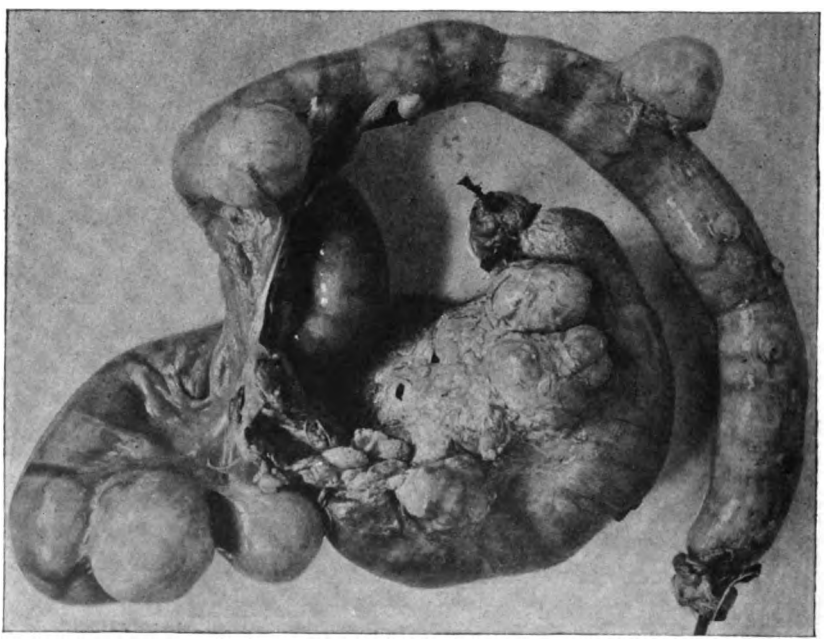

Hodenpyl's specimen of multiple acquired diverticula of the colon (sigmoid flexure).

Regarding the pathological importance of these diverticula, the writer has been able to glean very little from literature.

Sydney Jones,[7] in 1858, was perhaps the first to mention it. He described a case of intestinal-bladder fistula which he believed to be due to ulceration of a sigmoid diverticulum. Loomis,[8] in 1887, described a case of peritonitis due to inflammation of multiple diverticula of the left colon, several of which contained concre-

Digitized by Google

tions. Birch-Hirschfeld,[9] in 1887, called attention to the possibility of diverticulitis with perforation and the formation of intra- or extraperitoneal abscess. George Biggs,[10] in 1894, presented to the New York Pathological Society a specimen showing multiple diverticuli of the sigmoid, one of which had perforated and caused an extraperitoneal abscess. Fischer,[11] in 1900, reviewed the entire subject, described four specimens, and expressed some doubt regarding the role of constipation as a causative factor. Edwin Beer, in 1904, presented a paper on the pathological and clinical aspects of the lesion, and described the various types of acute and chronic diverticulitis.[12]

It will thus be seen that, from time to time, during the past half century pathologists have observed and reported pathological specimens showing inflammation, necrosis, and perforation (with or without the presence of fecal concretions) of these false diverticula of the left colon, and clearly demonstrated the relationship between these lesions and a general or localized peritonitis.

For the most part, however, these communications have been buried in the transactions of pathological societies or have appeared in periodicals not largely read by clinicians. This circumstance, and the rarity of the condition, will easily account for the fact that the disease is not described in our clinical text-books, nor generally recognized by the profession.

The writer has long been impressed with the probable relationship between these diverticula and left-sided abdominal abscess, but was unable to verify this impression until quite recently. The following case, while it does not prove the relationship absolutely, presents features which render it highly probable.

F. M., aged forty-seven years, was seen by the writer in consultation in August, 1906. The patient for twenty years had been a high liver and a hard drinker. One year before he had had an attack of acute nephritis with uremia, from which he had partially recovered. Six weeks before being seen by the writer he had experienced an attack of abdominal pain with nausea and vomiting. The pain was at first located in the centre of the abdomen, but later shifted to the left lower quadrant. There was mod-

Digitized by Google

erate fever and a considerable prostration during the first few days following the onset of the symptoms. Later, a tender swelling was noticed just to the left of the median line and below the umbilicus. This mass slowly increased in size, and at times would be so painful as to interfere with sleep. The symptoms were only of moderate severity, however, and he remained under medical treatment for several weeks in the country, until increased fever, chilly sensations, and augmented tenderness in and about the mass led his medical adviser to advocate his removal to a hospital. He was accordingly brought to New York and placed under the care of my colleague, Dr. E. B. Shelby, with whom I saw him in consultation on the following day.

At my first examination I found the patient with a temperature of 102°; pulse 118. He complained of no discomfort except when moved about or palpated. On inspection a swelling could be distinctly seen below and to the left of the navel. On palpation there was slight rigidity of the left rectus muscle and an oval mass about the size of an egg-plant could be felt, which was distinctly tender to pressure. The appendix region was free from tenderness. The free border of the liver could be felt well below the costal arches, the spleen percussed large, but could not be palpated. The blood showed a moderate leukocytosis with an increased percentage of polynuclears. The heart and lungs were negative, the urine showed a trace of albumin with casts, but was sufficient in quantity.

He was removed to the Roosevelt Hospital, where, under general anesthesia, an incision was made through the outer border of the left rectus muscle, which exposed a large well walled-off abscess containing gas and about 500 c.c. of foul-smelling pus. On account of the poor physical condition of the patient no effort was made to break up the adhesions with a view to determining the point of intestinal leakage. He rallied well from the operation and made a slow convalescence. The wound healed slowly, one small sinus persisting which led downward toward the pelvis and through which small quantities of gas would occasionally escape. On three or four occasions, during his convalescence, secondary

Digitized by Google

abscesses would form in the neighborhood of the sinus. These, as a rule, would discharge spontaneously. He was up and about, however, and after October 1st was able to go down town and attend to his business.

Later, as his health improved, an attempt was made to find and close the intestinal opening. On December 5, under ether anesthesia, after evacuating and packing an abscess of the abdominal wall, the sinus was followed down to the region of the sigmoid flexure in the pelvis without opening the peritoneal cavity. A second incision was made to the right of the median line, and the peritoneal cavity opened and explored. The intestines were generally free from adhesions. Two portions of the gut, however, were firmly adherent to the wall of the abscess, the first, which was in all probability the primary lesion, was situated about the middle of the sigmoid; the second, probably a secondary communication, was a loop of small intestine adherent to the upper part of the abscess wall, above and to the left of the umbilicus. Both of these adhesions were separated, and the minute openings closed with purse-string sutures. The right abdominal wound was united by layer suture, the wound on the left side exposing the abscess cavity was partly united and drained with gauze. The patient bore the operation well, but vomited a good deal after coming out from the ether. There was practically no reaction during the first twenty-four hours; later, the temperature and pulse rose gradually. The vomiting was troublesome, and on the second day after operation he vomited a large quantity of dark fluid, with clotted blood, which greatly weakened him. This was repeated several times, and eventually resulted in his death. At no time were there any local signs of peritonitis. The gastric hemorrhage was attributed to cirrhosis of the liver.

In my next case the relationship between an acute diverticulitis and an intra-abdominal abscess is clearly proved.

S. D., aged forty-five years, had always enjoyed good health; he had never suffered from digestive disturbances, suggesting appendicitis, gallstone colic, or peritonitis.

In August, 1902, he was suddenly seized with an attack of

Digitized by Google

abdominal pain, nausea, and faintness, while at dinner, which necessitated his leaving the table and returning to his room. The severity of the attack soon passed off and he was able to join his friends later in the evening.

The following night proved a restless one, as he had more or less constant pain in the lower portion of the abdomen, which prevented sleep, and at times was accompanied by nausea and general bodily weakness. The following day he continued to feel badly, but kept up and about for the reason that he was a guest at a country house, and did not wish to inconvenience his host.

Later in the day he went for a drive, and suffered acutely from the jolting of the vehicle. In the evening he was obliged to call a physician, who, after an examination, pronounced the case one of colitis. He returned to the city the following day, and as the symptoms continued, he remained in bed. During five days he continued to suffer with pain in the lower left quadrant of the abdomen, fever, and general malaise.

When first seen by the writer the temperature was 103°; pulse, 110; leukocytes, 17,000.

There was marked rigidity of the left rectus muscle and a tender mass in the iliac fossa.

He was immediately removed to the Roosevelt Hospital, and, under ether anesthesia, an incision was made over the most prominent portion of the tumor. After dividing the tissues of the abdominal wall, a large abscess cavity was entered, which contained about 150 c.c. of foul pus and an oblong, fecal concretion. On washing out the abscess cavity a small ulceration was seen in the wall of the sigmoid through which escaped a small amount of fecal discharge. The cavity was packed with sterile gauze, the wound partly united and a dressing applied.

After operation the temperature and pulse rapidly declined to the normal, the pain ceased, and the appetite returned. The discharge from the abscess cavity gradually diminished until a cathartic was administered on the fourth or fifth day. This gave rise to a very abundant fecal discharge, which continued for several days. It gradually diminished after this period, and the sinus

Digitized by Google

finally closed in about six weeks from the time of operation. He has since been in perfect health.

One year later the following case was observed, which clearly demonstrated the relationship between an acute perforative diverticulitis of the sigmoid and a generalized fatal peritonitis.

A. W., aged fifty-four years, was admitted to the Roosevelt Hospital in August, 1905, suffering with the evidences of a rapidly developing general peritonitis.

Four days before admission the patient had experienced severe pain in the abdomen, which was soon followed by nausea and vomiting. The pain at first was located in the region of the umbilicus, but later shifted to the lower abdomen, and finally became localized. In the beginning of the attack there was little or no fever, the chief complaint being the irritability of the stomach which led to the belief, on the part of his attendants, that the patient was simply suffering from an acute attack of indigestion.

Accordingly a cathartic was administered, and other appropriate treatment advised. On the third day the symptoms became worse; there was more pain in the lower abdomen; a gradual rise in temperature, and a progressive increase in the pulse rate. The abdominal tenderness increased, and a gradual distention appeared with a renewal of the vomiting and a rapidly advancing prostration.

When admitted to the hospital his temperature was 103°; pulse, 128; leukocytes, 16,000.

The abdomen was greatly distended, everywhere tender, and tympanitic to percussion. Muscular rigidity was well marked as much on the left as on the right side.

Examination of the heart and lungs was negative. The urine was loaded with albumin, granular and hyaline casts.

Acting on the belief that we had to do with a perforating appendicitis, with spreading peritonitis, under ether anesthesia, an incision was made through the right rectus muscle. As soon as the peritoneum was opened there escaped a quantity of thin, foul-smelling pus. The intestines were deeply injected and matted together, and in places covered with a fibrinous exudate.

Digitized by Google

The appendix was sought for and found to be intact, and no more inflamed than the surrounding viscera. As the pus seemed to well up from the pelvis the incision was enlarged, and the intestines drawn upward out of the cavity. At the bottom of this space we found an oval fecal concretion somewhat larger than a date seed, and nearby a deeply congested loop of the sigmoid, on the free border of which was the gangrenous perforated remains of a small diverticulum. The perforation was closed by Lembert sutures, the entire cavity washed out with normal salt solution, the wound partly united, and a cigarette drain carried down to the bottom of the pelvis.

The patient rallied well from the operation, but after forty-eight hours of improvement the vomiting returned, the abdomen became more distended, the urine diminished in quantity, the temperature and pulse rose, and he became progressively weaker. All attempts to move the bowels were unavailing, and he died at the end of three days.

The last two cases prove conclusively the relationship between acute perforative diverticulitis of the sigmoid and a localized intra-abdominal abscess in one instance and a spreading peritonitis in the other. They suggest also the probability that the concretion in each instance acted as a predisposing cause of the lesion.

That the condition is rare there can be no question, but that it is far more frequent than one would suppose, from the scanty reference to it in medical and surgical literature, the writer believes to be highly probable. While in four of my cases the relationship between a diverticulitis and the abscess is not proved, still the similarity in the symptoms between them and the last two cases is so striking as to lead one to the belief that they might well have had a similar origin, especially as it is difficult to account for their origin by any other theory.

Digitized by Google

BIBLIOGRAPHY.

1. Léon Cahier. L'inflammation des diverticules intestineaux ou diverticulite. Revue de Chirurgie, September, 1906.
2. Wallmann. Virch. Arch., 1858, Band xiv.
3. Leube. Ziemssen's Spec. Path. and Therapeutics.
4. Hodenpyl. Trans. New York Path. Soc., March 29, 1900.
5. Max Edel. Virch. Arch., 1894, Band cxxxviii.
6. Graser. Münch. med. Woch., 1899, Nr. 22, and Arch. f. klin. Chir., 1899.
7. S. Jones. Trans. Path. Soc. of London, 1858.
8. Alfred Loomis. Trans. New York Path. Soc., 1877.
9. Birch-Hirschfeld. Path. Anat., 1877.
10. G. Biggs. New York Path. Soc., March 28, 1894.
11. Fischer. Journal of Experimental Medicine, 1900, p. 333.
12. Beer. Amer. Jour. Med. Sci., July, 1904.

Digitized by Google

DISCUSSION ON THE PAPERS OF DRS. MAYO, GERRISH, AND BREWER.

DR. S. J. MIXTER, of Boston.

I think the profession owes a debt of gratitude to the gentlemen who have made this subject so much clearer than it has been before, and especially for the pathological work that has been done, which is of special value. Those who are familiar with abdominal surgery must have seen a considerable number of these cases. I recall two cases of acute perforation followed by death and autopsy, in private practice, and I have one case especially to speak of which shows the beginning of this condition. This was a man of middle age who was seized with sudden violent abdominal symptoms presenting those of the appendix, but on the wrong side, and on opening the abdomen an abscess was found extending from the lower part of the cecum into the omentum between the layers of the mesentery. The whole sigmoid was inflamed; a loop was brought out, an artificial anus made, and the abscess opened. It contained fecal pus.

In addition I am sure we have all seen these chronic cases resembling malignant disease, and I know of several where I have done exploratory laparotomy. I remember two cases in particular because they were afterward cured by cancer quacks. These cases presented masses connected with the sigmoid, and apparently malignant, but so firmly adherent that there was no question of excision, at least not in my mind. The abdomen was closed, a bad prognosis was given, and both of these patients subsequently went to some healer, Christian Science or something of that sort, and were treated and recovered. They could not have recovered if the conditions had been malignant. These must have been perisigmoid inflammatory masses.

DR. ELLSWORTH ELIOT, JR., of New York.

I want to put on record a brief abstract of a case of abscess of the left iliac fossa in a child aged six years, operated on after a four days' attack, in which the wall of the abscess was formed in part by the sigmoid flexure, but in which no positive cause for the abscess could be learned. The child recovered, a sinus eventually closing. A year after a second attack occurred, which came to my notice very promptly, and on median laparotomy the appendix was found extending from the right iliac fossa across the median line in front of the sacrum to the left iliac fossa, the tip of which had been the source of previous trouble. The appendix was removed and the patient made an uneventful recovery.

Digitized by Google

DR. REGINALD H. FITZ, of Boston (by invitation).

The communication of Drs. Mayo and Wilson, followed by that of Dr. Brewer, in addition to the experience of the other members of the Association who have taken part in the discussion, make a fairly complete picture of what must be recognized as a new disease of the lower abdomen: diverticulitis of the left quadrant analogous to appendicitis of the right quadrant.

The comparative frequency of the false diverticula of the descending colon and sigmoid in elderly people, and especially when fat, is well known to pathological anatomists. The fact that they may give rise to subacute and chronic paracolitis and parasigmoiditis, simulating malignant tumors, so far as I am aware, is altogether new. One of the cases reported was seen by me in consultation with Dr. M. H. Richardson and the physical characteristics of the tumor were such as to stimulate a malignant growth of the intestine, the presence of which was considered probable. An exploratory operation was suggested, although more than palliation was not anticipated. The possibility of diagnosticating such cases in advance of the operation is favored by the occasional presence in the stools of inspissated feces so molded as apparently to have been shaped in such diverticula of the lower portion of the large intestine.

The communication by Dr. Gerrish reminds me of a study made many years ago and published by me in the *American Journal of Medical Sciences*, in 1884. The relation between persistence of the vitelline duct or of omphalomesenteric vessels and intestinal obstruction was considered at length. The vessels in particular, usually obliterated and transformed into a delicate, fibrous cord, are a not uncommon cause of internal strangulation of the bowel and often have been reported as "adhesions," with the thought of their inflammatory origin. It is to be remembered that Meckel's diverticulum, the persistent remains of the vitelline duct may be found within the mesentery and then may assume the characteristics of an intramesenteric cyst, even of a duplication of the intestine.

DR. W. L. ESTES, of South Bethlehem, Penna.

Grasser suggests that these conditions occur as a result of a myocarditis. His theory is based upon the fact that the mesenteric vessels which supply the intestine run perpendicular to the mucous membrane; in conditions of very low heart and arterial pressure the capillaries are not entirely filled, from these empty spaces lacunæ are formed, transudation from the intestine enlarges these lacunæ, they become infected by the intestinal bacteria; an abscess is formed which involves the mesentery, causes thickening and contraction of the mesentery; then

Digitized by Google

of the intestine itself, and thus produce flexures and diverticula. These abscesses may rupture into the intestine or into some neighboring cavity (bladder or vagina, for instance). These abscesses and distortions are located almost invariably at the sigmoid flexure. I have had two cases of suppuration in the left iliac region which I did not understand, and in looking up the literature for a possible explanation I found Grassi's explanation. One of my cases was a middle-aged man who undoubtedly had myocarditis, and his case would come under the "acquired" class of Dr. Mayo in its manifestations; the other was a young girl. I would like to ask Dr. Mayo if he has noticed any myocardial affection in any of his middle-aged cases?

DR. GEORGE TULLY VAUGHAN, of Washington, D. C.

I have seen at least four or five cases of abscess on the left side of the abdomen which I did not understand. The appendix could be exonerated at any rate, but I was not able in any of my cases to trace the condition to a diverticulum. I have seen one case of diverticulum which had apparently done no harm in a patient operated upon for hernia on the left side. The hernial sac contained the sigmoid flexure of the colon, and attached to this was a diverticulum containing a little hard lump of fecal matter. The diverticulum was cut off, the opening in the bowel sewed up, and the patient recovered.

DR. HARVEY CUSHING, of Baltimore.

I would like to ask Dr. Mayo for information in regard to one anatomical point in this connection. Is it not usual for the diverticula to be found more often at the mesenteric border of the intestine; in other words, where the bloodvessels enter the intestinal walls? We have had some experimental evidence pointing in this direction during the past winter. One of the students in the Hunterian Laboratory has been studying the effects of resection of a large percentage (75 per cent. to 85 per cent.) of the small bowel. In cases in which there is subsequent hypertrophy leading to a widening of the bowel we have occasionally seen diverticula which appear just at the point where the mesenteric vessels enter the gut and separate the muscle fibers, as they penetrate to the region of the submucosa. The same thing might occur at the side of the bowel where there is another layer of penetrating vessels, but this we have not seen in our experimental cases.

DR. C. B. G. DE NANCRÈDE, of Ann Arbor, Mich.

I saw a case in consultation recently where we believed it was an inflammation extending from the colon between the layers of the mesentery, and from what I have now heard on this subject I believe the case

Digitized by Google

was one of diverticulitis. I had another case two or three years ago which I believe must have been due to the same condition, as it evidently had its origin in the colon. The first patient was an obese, elderly man; the last one a young girl. I am satisfied that the origin of trouble in both cases was in the sigmoid and was almost certainly the result of a diverticulitis.

DR. MAYO. I have a firm conviction that if some of the Fellows will go over their jars of specimens of resection of the sigmoid for carcinoma they will be surprised to find that a considerable percentage of them will prove to be diverticulitis. I had one case of exactly this type; the specimen had been cut through and was apparently typical of carcinoma, but careful examination showed diverticulitis. Now the question is, What are we going to do with these cases of diverticulitis with tumor? Can we tell before section whether they are carcinoma or diverticulitis, for this might change the operative procedure? I fear that the diagnosis cannot always be made on the operating table.

The obstruction in two of our cases was so extreme that they were operated upon for obstruction of the bowel from tumor.

Regarding the point brought up by Dr. Estes: I think none of these patients had any trouble with the heart. The histories show that except for the condition under discussion they were quite healthy persons.

Dr. Wilson has, I think, demonstrated that these diverticula do not necessarily occur along the line of the bloodvessel, but that they may take place at any point in the circumference of the intestine.

DR. WILSON (by invitation). We have purposely omitted all mention of literature in reading these papers, though when printed they will contain a bibliography. I desire, however, to call attention here to Dr. Beer's paper in the *American Journal of the Medical Sciences*, May, 1904, which is far the best report seen so far. He reported one case of his own and carefully reviewed the literature and pathology of seventeen other cases, making eighteen in all. It is a most excellent report and one well worth reading. In regard to the occurrence of carcinoma Hochenegge has reported one case of carcinoma following an ulcerated diverticulum. I have gone very carefully over all our cases of carcinoma of the colon, but found none of them related to diverticula.

DR. GERRISH. Diverticulum ilei occurs in 2 per cent. of all cases. The unique feature in the case reported by me was the very peculiar arrangement of the parts. The diverticulum came from the free border of the ileum, passed downward on one side of the mesentery, apparently

Digitized by Google

squeezed itself through an arched opening in the attached border of the mesentery, and then curved up on the other side, fastening itself to the abdominal wall by the intervention of a thin cord. This attachment is seen in a great many of these cases. I am still in the gall of bitterness as far as my assertion that these cases of diverticulum should be operated upon is concerned, in spite of Dr. Fitz's views. Once since the case which I have reported I have come across a case of appendicitis, seen with me by Dr. Bristow, in which there was gangrene of the appendix and abscess, and the condition of the patient was such that, although I found there was a diverticulum, I did not dare increase the risk to the patient's life by removing it. The patient knows that she has this diverticulum, and will be on the lookout for any of the frequent signs of trouble. The diverticulum in this case, as well as the one in the case reported, had no mesentery, which I think is a very common condition, the diverticulum being nourished through the intestine itself from which it springs.

Dr. Brewer. Dr. Mayo has just spoken of the possible association of carcinoma with these diverticula. One case was recalled to my mind which I saw some years ago in consultation. A man with left-sided abdominal abscess. The consensus of opinion was that he had carcinoma with a probable perforation or peritonitis resulting in this abscess. The patient's condition was not good at operation, and the abscess was simply drained. Contrary to our expectations the abscess closed rapidly, the man made a rapid recovery, and for six, or eight or ten months was perfectly well. He then began to decline in health, and gradually acquired symptoms of obstruction. The sinus reopened, and the surrounding abdominal wall became infiltrated with carcinomas. This man probably had an acute diverticulitis with abscess, and as a result of inflammation there developed, subsequently, carcinoma. He lived for about two years after his first operation.

Digitized by Google

REMARKS ON THE SURGICAL TREATMENT OF FACIAL PARALYSIS AND OF TRIGEMINAL NEURALGIA, WITH EXHIBITION OF PATIENTS.

By HARVEY CUSHING, M.D.,
BALTIMORE.

Two patients, who had recently been operated upon, were exhibited; one of them had been a sufferer from *tic convulsif*, the other from *tic douloureux*. The historical as well as the physiological relationship of these two maladies was briefly considered—the former being an affection of the motor nerve to the expressional musculature, the Nervus facialis; the latter, of the sensory nerve to these same muscles and their overlying skin field, the Nervus trigeminus.

Case I.—In the case of *tic convulsif*, after purposeful division of the facial nerve at its emergence from the stylomastoid foramen, a spinofacial anastomosis was performed a year ago, this being the speaker's eighth case of this form of anastomosis. Reasons were given for preferring this method to the hypoglossofacial operation, under the conviction that the results of the former are uniformly better than when the motor nerve to the tongue has been employed. The arguments advanced by Ballance and Spiller favoring the hypoglossofacial operation on physiological grounds are largely conjectural, and the thickness of speech consequent upon the hemilingual paralysis is an undesirable sequel of this method.

It was shown in the patient exhibited that she had regained in considerable degree the normal *emotional* control of the expressional musculature, the only instance of functional restoration of this type heretofore recorded, so far as the speaker was aware. Indeed, in this patient the first indication of returning movement

Digitized by Google

occurred six months after the anastomosis as a certain emotional control in the act of smiling. (See Figs. 1 and 2.)

One other of the speaker's spinofacial operations had been performed for an even more severe case of *tic convulsif*, and Kennedy, of Glasgow, based his early report of this method of anastomosis on the study of a patient who had been operated upon for the same malady. The muscle spasm, which in severe cases becomes associated with painful muscular cramps, ceases immediately after the division of the facial nerve; and, with the return of control by way of the Nervus accessorius, the spasms have not returned in any of the recorded cases.

CASE II.—The second patient had been recently operated upon (eight weeks) for *tic douloureux*. She was the fifty-second case of ganglion operation in the speaker's series. Her neuralgia had begun in the first or ophthalmic division of the trigeminus, and in the five months during which she had been suffering had extended into the field of the second or maxillary division, and there was an occasional twinge in the mandibular division. Realizing that unless completely relieved she was destined to a neuralgic life, and not wishing to procrastinate through peripheral operations of short-lived benefit, the ganglion operation was performed as a primary measure.

The speaker emphasized that all operations on the peripheral side of the ganglion in cases of genuine trigeminal neuralgia, whether they include nerve section, evulsions, or injections into the nerve trunks of mordant fluids, must be regarded as measures which serve merely to postpone the day when complete and final severance of the nerve proximal to the ganglion must be contemplated, in order to secure permanent relief. This applies not only to peripheral extracranial operations, but also to those intracranial procedures during which only a portion of the ganglion is removed, or in which, after intracranial division of its lower branches (maxillary and mandibular) foreign substances are interposed either in the course of the divided nerves or in the foramina which they traverse. Particularly is this true of those patients whose neuralgia has originated in the ophthalmic division, as in the patient shown.

Digitized by Google

FIGS. 1 and 2.—Case VIII of spinofacial anastomosis, showing closure of eye, with but slight action of other expressional muscles; also symmetrical action of muscles in act of smiling, unassociated with shoulder movements.

Digitized by Google

Furthermore, when the first or ophthalmic division is left intact, as in many of the above-mentioned procedures, it sooner or later becomes involved in pain, even if the paroxysms have not originated there.

On the patient shown, the speaker demonstrated the position of the incision which has been employed in his last thirty-one cases. It obviates the surgical division of the highest branch of the pes anserinus which innervates the occipitofrontalis—an unavoidable consequence of the omega-shaped incision employed in all other methods of approach. Owing to this incision, and to the careful closure in four layers of the soft parts over the temporal fossa, no observable trace of the operation remains, for there is no appreciable asymmetry of the face, either from atrophy of the masticatory muscles or in consequence of the loss of power to elevate the eyebrow.

Postoperative photographs, taken on or about the tenth day after the neurectomy, in the thirty patients similarly treated, were shown (see Figs. 3 and 4, an example), giving further emphasis to this improvement in the technique of the operation, so far as it concerns the approach to the ganglion. The incision, in many of these cases, is absolutely invisible, even on the shaved scalp a few days after the operation, owing to the painstaking method of closure. It was shown also that it is needless to shave more than the temporal region of the afflicted side in preparation for these operations, healing in all cases having been absolutely perfect, and only one or two out of the thirty cases having been drained for forty-eight hours, owing to a continuance of the venous oozing.

A further point in regard to the treatment of the ganglion was then emphasized. In the speaker's last thirty cases the ganglion has not been removed and the operation has been conducted merely at its posterior border, between the edge of the mandibular division and the meningeal artery. When the ganglion has been sufficiently freed at this point a properly curved, blunt dissector is inserted under and around its sensory root (often before the root has been brought clearly into view, for this sometimes is impossible) and the sensory root is then carefully hooked forward and avulsed

Digitized by Google



FIGS. 3 and 4.—Case LIII of ganglion operation. Patient sixty-seven years of age. Neuralgia of fifteen years' duration, having advanced to extreme type of "neuralgia quinti major." Several earlier peripheral operations. Had become a profound morphinist. Sensory root avulsed. Photographs taken on tenth day. Note practically invisible scar, despite clear detail of negative.

Digitized by Google

from the pons, so that it is turned out of the opening which it traverses at the attachment of the tentorium, and lies forward over the ganglion. In the original operation the attempt was made to remove the ganglion in toto, a procedure which occasions considerable bleeding, particularly during the liberation of the first and second divisions. The avulsion of the sensory root, together with the ganglion, was always attempted in these earlier operations; but at the present time the speaker is content with the avulsion of the sensory root alone, and leaves the ganglion in its bed without freeing the ophthalmic and maxillary divisions, for the liberation of these branches is the chief cause of operative delay in many cases, owing to the resultant bleeding. Once only in the writer's entire series of sixty-two ganglion operations has the meningeal artery been injured, either at its entrance into the skull or at its fixed point in the parietal bone.

Emphasis was also laid by the speaker on the fact that operations on the Gasserian ganglion are not measures to be attempted other than by those who, through special training, have perfected themselves in safe methods of conducting these delicate intracranial manipulations.

Digitized by Google

DISCUSSION.

DR. S. J. MIXTER, of Boston.

I hesitate somewhat to even discuss the paper of Dr. Cushing, considering his very remarkable successes in this branch. I have had some experience in this line. I wish that Dr. Cushing had said a little more about his method of operating. The old method of removal of the whole ganglion was, and still is, a dangerous one. In fact, as Dr. Cushing has said, this operation will always be a dangerous one; I wish to go a little farther than he did and say that even in the most skilful hands it will always be a dangerous operation. No two cases are exactly alike. When it comes to the question of choice of an operation I think it must depend largely upon the operator's experience. Personally, during the last few years in twenty or more cases I have done a modification of the Abbe operation, and I think that I shall continue to do that operation until I see some reason, which I do not now see, for abandoning it, because my results so far have been satisfactory both to me and to my patients. These cases extend now over a period of three to four years, and so far as I know, and I have been able to follow these cases pretty thoroughly, there has been no recurrence of the pain.

I divide the second and third divisions of the nerve, injecting the nerve either before or after division with osmic acid introduced into the trunk, and then after dividing the nerves push them out of sight, fill the foramina with amalgam filling, also the fossa, making a complete dam of considerable size between the stumps of the nerve and ganglion. During an operation of this sort one of my patients died almost on the table; I have never been able to explain this death, as this operation seems to me very much less dangerous than the old operation, which I cannot understand anyone now using, and I consider the operation I do is even less dangerous than the method Dr. Cushing uses. It certainly is simpler, even though it may not be as quick.

DR. ALLEN STARR, of New York (by invitation).

I want to congratulate Dr. Cushing on the results that he has obtained in both of his cases. I have had a number of cases operated upon by the hypoglossal operation, and I have never seen as good a result as in Dr. Cushing's case here presented.

In regard to the treatment of trigeminal neuralgia, I have been accustomed for many years to send all my cases to Dr. Hartley for operation. I think that neurologists are pretty well convinced that the source of disease in neuralgia of the fifth nerve is in the changes that occur in the Gasserian ganglion. This has been shown pretty conclusively by

Digitized by Google

Mills, Spiller, and Keen, who have demonstrated clearly the existence of degenerative changes in the Gasserian ganglion. It then stands to reason that it is useless to divide the nerves in their peripheral course. My experience has shown me that while the peripheral operation may relieve for a few months, possibly a year or two, the pain is almost sure to return along the branches of the fifth nerve. Therefore, in every case I should advise the early radical operation.

Regarding the pathology. I cannot be quite sure that the division of the nerve trunks on the distal side of the ganglion is destined to remain a feasible curative operation. I should much prefer to divide the nerve between the ganglion and pons, or tear the root of the nerve out of the pons. As Dr. Cushing has devised this operation of tearing this root out he has conferred upon us a great benefit by making an operation that is sure to be a successful one in every case. It gets at the root of the matter and it absolutely cuts off that ganglion from the conscious centres in the brain, thus preventing any recurrence of the pain.

DR. STEPHEN H. WEEKS, of Portland, Maine.

I am sure we are all indebted to Dr. Cushing for his excellent contribution, but I think no surgeon would think of removing the Gasserian ganglion until the nerves had been removed outside the cranial cavity. It often happens after these operations that the pain sooner or latter returns, and the only thing the surgeon can do is to remove the ganglion. At my last operation, which was only a few weeks ago, a point occurred to me which I think worthy of mention. In my operation I make the osteoplastic flap, and after exposing the nerves previously to their passing through the foramen, the first nerve that comes into view is the superior maxillary just before it passes through the arytenoid. The proximal end is pulled upon firmly and the ganglion will be found embedded in its depression. The next step is seizing the inferior maxillary, by rough dissection carefully severing from the meningeal artery close by, and then seizing the canal and cutting it off, and then, by making traction on the proximal end, the Gasserian ganglion is lifted from the depression and comes directly into view, and then with the scissors one can cut off as much of the ganglion as he pleases. I believe it is an advantage to leave a portion of the ganglion.

DR. CUSHING. I believe, with Dr. Starr, that the ganglion cells represent the seat of war in cases of trigeminal neuralgia, although I do not believe that any of the pathological changes in these cells which have been found in extirpated ganglia are a specific lesion of the disease. They represent rather the residual cell alterations resulting from earlier peripheral operations and are comparable to the changes in spinal

Digitized by Google

posterior-root ganglia after amputations. As the ganglion cells are the actual "seat of war," and as all of them, first or last, become involved, those of the first division included, total extirpation or permanent severance from their encephalic connections is the only thing which can assure a final cessation of painful impulses. Much as I respect, therefore, Dr. Mixter's unusual surgical skill and judgment, I am inclined to regard the method that he has described as only a temporary measure, particularly for cases in which the first division has been or is likely to become involved. The very fact that he uses three different measures to accomplish the destruction of the ganglion cells or to prevent regeneration is an evidence of no great assurance in the efficacy of any one of them, and I doubt not but that esthesia remains in the field of the ophthalmic division after a large percentage of these operations, indicating only partial destruction of the ganglion. An operation which is limited to the removal or destruction of the second and third divisions, leaving the first division intact, gives no assurance of permanent relief from pain, as I have learned to my sorrow in two earlier cases in which, from operative difficulties, I failed to remove the entire structure. If the skull has been once entered, a central operation, provided that with practice it can be simply and safely done, is far preferable to any measure or combination of measures directed toward the distal branches of the ganglion or the lower groups of ganglion cells.

Digitized by Google

THE DESIRABILITY OF EARLY OPERATIONS UPON THE NERVES IN ISCHEMIC PARALYSIS.

By LEONARD FREEMAN, M.D.,
DENVER.

VOLKMANN'S ischemic paralysis, as is well known, occurs with few exceptions in children, following fractures of the forearm, and is nearly always due to tight bandages or splints. The muscles, being deprived of blood by pressure, their cells undergo disintegration and absorption, and are replaced by connective tissue. When the circulation is rapidly cut off, it has been estimated that the muscles die in about seven hours; but when the process is slower, death may not result for days or weeks, and may then be only partial, permitting more or less complete regeneration. The immediate result of this local muscular death is a form of rigor mortis, causing contractures similar to those seen in the cadaver, thus explaining why the fingers are occasionally found strongly flexed upon removing the splints but a few hours after their application. Such postmortem rigidity, however, is only the first step in ischemic paralysis. The real process develops later, resulting from the slow solidification and contraction of connective tissue. The affected muscles become hard and shrunken, resembling, in extreme cases, mere bands of tough, fibrous material. The fingers grow permanently flexed, occasionally to such a degree that the nails dig into the palm. Rarely the dorsal muscles are more strongly contracted than the palmar, resulting in extension of the wrist and proximal phalanges, with flexion of the terminal phalanges, leading to a peculiar claw-like deformity.

Just how much the nerves are concerned in the phenomena of

Digitized by Google

ischemic paralysis seems to be uncertain. In some instances they do not appear to be involved at all; while in others, sensory and trophic disturbances are the causes of very distressing symptoms. A primary neuritis is not uncommon, due directly to splint pressure, aided by an insufficient supply of blood, and manifesting itself by the usual disturbances in sensation. This may disappear, especially if the splints are promptly loosened; or it may pass directly into the later and more serious form of pressure neuritis, due to cicatricial contractures of the muscles, to which I especially desire to call attention. The damage from this latter form may be slight, or it may be so great that the nerves are changed into fibrous bands and almost pinched out of existence, their functions being correspondingly destroyed. They are often irregular and nodular when pressed upon, while above this point they are thick, soft, and congested. Nothing could be more evident than these nerve lesions—they are often so marked as to instantly force themselves upon the attention of the operator. They result in sensory and trophic disturbances of the hand, varying all the way from slight anomalies in sensation to that deplorable condition in which the skin is glazed, bluish, and perhaps blistered, and the sense of touch destroyed. The hand may become so sensitive and painful as not only to inhibit its usefulness, but to render it an intolerable nuisance to its possessor. One of my patients, an extreme case, even went so far as to beg me to amputate his arm if there was no other way to relieve his distress.

It is justifiable to assume that Volkmann's paralysis originates in the muscles, hence treatment should first be directed toward their recovery by removal of constricting bandages and splints, persistent massage, electricity, passive and active motion, etc., and in many instances success will be achieved. It must not be lost sight of, however, that *the condition of a muscle depends largely upon the condition of its nerve.* If the nerve is badly injured, the muscle suffers until the nerve is repaired. In other words, a species of "vicious circle" exists—cicatricial changes in the muscles injure the nerves by compression, and the injured nerves in turn prevent the regeneration of the muscles. Hence we are

Digitized by Google

forced to give attention to the nerves, when involved, as well as to the muscles.

The above considerations naturally lead to the following conclusions:

1. Every case of ischemic paralysis, whether slight or marked, whether nerves are involved or muscles alone, should first be treated by massage and electricity, combined with such active and passive motions as are best adapted to lengthen the contracted muscles or prevent their further stretching. The massage should be vigorous and persistent, and the stretching of the muscles, by simultaneous extension of wrist and fingers, as decided as the patient can bear. As mentioned by Fergusson, however, too violent extension, especially under anesthesia, might be disastrous, by causing rupture of the nerves imbedded in the cicatricial muscles.

2. In many cases, under this treatment, when the lesions are purely muscular, or when the nerves are but slightly implicated, improvement will occur in time, followed often by more or less complete recovery, although the tendons may require lengthening by some plastic operation. And even when the nerves are badly pinched, as evidenced by changes in sensation and nutrition, the results may still occasionally be good.

3. *If, however, in these bad cases improvement in nerve function does not begin promptly and progress satisfactorily an early operation should be done to relieve the nerve trunks from pressure before they become hopelessly injured, and, also, for the purpose of aiding the recovery of the muscles by improving their innervation.* Nevertheless, following an operation, other methods of treatment should never be neglected.

When we consider the prolonged, and, perhaps, permanent disability and suffering produced by pinching of the nerves the atrophy which they plainly show, and the rapid degeneration which they undergo, it seems remarkable that early operations have not been urged in the past, or even alluded to, as far as I have observed, particularly as such operations are neither very difficult nor very dangerous. Even in cases where recovery ultimately takes place, early liberation of the nerves would often prevent

Digitized by Google

many months of useless pain and incapacity. When, under other circumstances, a nerve is caught in a cicatrix, or pressed upon by callus or a spicula of bone, the indications are always plain—the difficulty must be removed as soon as possible. A similar plan is invariably followed in dealing with the brain and spinal cord. Why, then, should the surgeon hesitate to act just as promptly when the injurious pressure arises from a cicatricial muscle? The only reason seems to be that attention has not been directed to the subject.

Theoretical considerations, corroborated by my experience, indicate that the nerves are apt to be pinched at certain points—the *median* in passing through the pronator radii teres;[1] the *ulnar* in its course between the two portions of the flexor carpi ulnaris, just below the internal condyle; and the *posterior interosseous* in traversing the fibers of the supinator brevis below the elbow. These points are easily reached by longitudinal incisions, which may be extended upward or downward to suit the requirements of the case. A good plan is to expose the nerves above the place of compression, which is readily done by reason of their large size, and then follow them down as far as may be necessary. They may be so intimately incorporated with the cicatricial muscles in bad cases that they can only be liberated by the most painstaking dissection, thus emphasizing the marked effects of pressure. In order to prevent a recurrence of trouble, it is often desirable to lift a nerve out of its cicatricial bed to a more superficial position beneath the subcutaneous fascia, or, possibly, to excise a portion of a hopelessly damaged muscle.

The cases on which I have operated have made a deep impression upon me.[2] They are as follows:

CASE I.—A girl, aged about ten years, who had broken both bones of the forearm some three months before I saw her. Splints

[1] As a matter of interest in this connection, it may be mentioned that strong voluntary contraction of the pronator radii teres, if continued for a time in the normal arm, may produce a tingling sensation in the portion of the hand supplied by the median nerve.

[2] I desire to acknowledge indebtedness to Dr. S. D. Hopkins for valuable advice and assistance in the treatment of these cases.

Digitized by Google

were used for four weeks, followed by a plaster-of-Paris cast for several weeks longer. There was satisfactory union. Upon the palmar surface of the forearm and hand, and upon the back of the hand, were several recent scars, the result of pressure necrosis. Cyanosis was present from defective capillary circulation, although the pulse was good. The skin had a drawn and glazed appearance, with a tendency to trophic disturbances, and was almost completely anesthetic. The fingers were strongly contracted, the muscles of the forearm indurated and paralyzed, and the hand useless. Owing to the great disability from involvement of the nerves I decided to operate at once.

Operation. Through appropriate longitudinal incisions the median nerve was found to be decidedly pinched by the cicatricial pronator radii teres, the ulnar to a less extent by the flexor carpi ulnaris, and the radial but slightly, if at all, involved. Above the points of compression the nerves were large and soft. After freeing the nerves, they were brought up beneath the subcutaneous fascia and the muscles reunited beneath with catgut. Primary healing. In a few days tingling sensations were felt in the fingers, which were followed by steady improvement, until at the end of three months, during which time massage was employed, sensation and motion in the hand were almost complete, and the circulatory trophic disturbances had disappeared. On February 17, 1907, over three years after the operation, the hand and arm were in nearly perfect condition, with no atrophy or induration of the muscles, full motion of the wrist and fingers, and normal nerve function. No inconvenience was experienced from the superficial position of the nerves beneath the skin.

CASE II.—A young man, aged nineteen years, who had received an injury of the fleshy portion of the right forearm about a year before he came under my care. No splints had been used, bandages alone having been applied, but nevertheless pronounced ischemic paralysis had developed, the fingers beginning to flex in a few weeks. The forearm was pronated when I saw him; the muscles hard and shrunken, especially near the elbow, and the fingers strongly flexed. The capillary circulation was poor and the

Digitized by Google

sense of touch absent, rendering the hand useless. The pulse was good. The patient complained bitterly of pain and burning sensations, and there was a tendency to blistering and ulceration of the skin. So marked were these symptoms that an amputation was requested, providing relief could not otherwise be obtained. An operation was decided upon in the hope of relieving the nerve symptoms alone, there being apparently but little, if any, chance of bettering the condition of the muscles.

Operation, on December 12, 1906. The median and ulnar nerves were found badly atrophied and pinched, the former by the pronator radii teres, and the latter by the flexor carpi ulnaris. They were irregular in size and nodular. In order to ensure permanent freedom of the median nerve, a portion of the useless pronator was removed, and with the same purpose in view, the ulnar was transplanted to a position beneath the skin. Primary healing.

The pain, burning, and other disagreeable sensations soon disappeared following the operation, and the sense of touch returned to a considerable degree. The trophic disturbances also underwent marked improvement. Up to the present time, however, about five months, there has been but slight gain in motion, but it can be said that the hand is no longer a source of annoyance and suffering.

CASE III.—A boy, aged sixteen years, who had broken the left olecranon process two and one-half years before he came under my observation. A plaster cast had been employed in treatment. About two weeks after the removal of the cast contractures of the fingers began, and became quite marked at the end of three months. When I saw him, digital flexion was almost complete, the skin somewhat livid from poor capillary circulation, and sensation very imperfect. There was a good pulse. The muscles of the pronated forearm were atrophied, and the hand practically useless, in spite of the fact that the fingers could be moved slightly. There was but little pain, and no trophic disturbances existed. As in the previous case, an operation was done upon the nerves, solely in the hope of restoring sensation to the fingers, the condition of the muscles being considered beyond relief.

Digitized by Google

Operation, February 8, 1907. Through longitudinal incisions, the median and ulnar nerves were dissected with some difficulty from the cicatricial pronator radii teres and flexor carpi ulnaris, and placed subcutaneously. They were firmly pinched and adherent, especially the ulnar, and resembled mere fibrous bands, rather than nerves. Above the points of compression they were abnormally large, soft, and congested. When the case was last seen, perhaps a month after the operation, there was already an improvement in sensation, which, it is hoped, will continue.

These three cases serve to illustrate the point which I have already emphasized, that when the nerves are badly involved in ischemic paralysis, and show no signs of prompt recovery, they should be liberated from compression early, before hopeless degenerative changes set in. This was done in Case I with an eminently satisfactory result. In Cases II and III, operation was delayed until the end of one year and two and one-half years, respectively, when, although improvement in nerve function was obtained, the results were, nevertheless, incomplete. I believe they would have been much better if the nerves had been liberated sooner.

Digitized by Google

DISCUSSION.

DR. WILLIAM J. MAYO, M.D., of Rochester, Minn.

I think we all occasionally see these cases, most of them the results of unfortunate surgical judgment at the time of putting on the splints; not always from adjusting them too tightly, but often because of the swelling which takes place afterward, and due to neglect in not carefully watching the cases. It seems to me that Dr. Freeman's contribution is distinctly a step in advance. It is worthy of note that when Volkmann brought out "Ischemic Paralysis," in 1875, his case was one of the only two in the lower extremity which had been reported.

It was Lesser who developed the pathology of the condition, in 1884, although practically all that was done up to that time was to call attention to the important group of cases under discussion. Up to the present, attempts at relief of these victims has been orthopedic. Mikulicz cut out a piece of both radius and ulna, shortening the bones to equal the contracted muscles, while Battle lengthened the muscles by plastic operation.

We have then in this contribution of Dr. Freeman's a distinct addition to the orthopedic correction of deformity, by a well-directed surgical relief of imprisoned nerves.

DR. B. FARQUHAR CURTIS, of New York.

The only personal experience I have had with ischemic paralysis was in a case of resection of the elbow in which a hemorrhage took place under the dressings, making them very tight and bringing about unfortunate pressure; this was due to a careless assistant. The case made a slow but complete recovery in the course of a year after operation. I have tried the removal of portions of the bones to lessen the tension on the muscles in these cases with very great improvement of motion, and I would recommend that from the orthopedic side. A great deal more will come of this resection operation than one would think possible in seeing the cases. It is wonderful how the muscles soften and regain power after being relieved of the tension.

I too am glad to hear of this new method of treatment, and shall try it in the next case I have, because I do not think the bone-removal operation answers at all for relief of pain and abnormal sensations in the parts.

DR. HERBERT L. BURRELL, of Boston.

I feel indebted to Dr. Freeman for his paper on "Ischemic Paralysis." I entirely agree with Dr. Mayo as to its value. It has been my fortune

Digitized by Google

to have a number of these cases, particularly in children. I have operated upon some of them and have done temporizing operations, that is, of division or lengthening of the tendons. These operations have been followed by a very mild degree of improvement. The operations have always seemed to me inadequate, and I have been anxious to know of a better method of relieving these very troublesome and serious cases. May I ask Dr. Freeman how early he would cut down on and expose the median and ulnar nerves in the event that massage did not relieve the beginning of an ischemic contraction and paralysis?

DR. FREEMAN. Such a question as has been asked relative to the time of operating is an extremely difficult one to answer. It could only be answered after sufficient experience had been accumulated. All that I can say is that, if after a few weeks of trial with massage, passive motion, and electricity a satisfactory improvement does not take place in the condition of the nerves, then it would be time to consider strongly the liberation of the nerves before they become hopelessly injured. I am speaking of the nerves, not of the muscles. When the nerves do not show the results of compression, I do not think an operation would be indicated.

Digitized by Google

FIBROID TUMOR OF THE NASOPHARYNX REMOVED BY TEMPORARY RESECTION OF BOTH SUPERIOR MAXILLÆ (KOCHER).

By FREDERICK KAMMERER, M.D.,
NEW YORK.

For large tumors of the nasopharynx which cannot be removed from the anterior nares—without or after preliminary operations on the soft parts of the face, Kocher has devised a procedure which in a number of cases has answered an excellent purpose. The records of such cases are few, however, and I have not been able to find any in our own medical literature. The method consists in separating the alveolar processes of both superior maxillæ with a chisel in a horizontal direction, beginning in each anterior opening of the nares. Both superior maxillæ, and if necessary the entire soft palate, are then divided in the median line, whereupon the alveolar processes can be forced to either side, opening up the nasal cavity after division of the mucous membrane lining its floor. The method has been fully described by Lanz[1] in 1893. It not only opens up a passage of such size that the largest tumors can be removed en masse, but it has the additional advantage of bringing into view the origin of the tumor at the base of the skull or the anterior surface of the upper vertebræ, thus enabling thorough removal of the same. No doubt, recurrences of benign tumors of the nasopharynx, springing from the base of the skull behind the posterior end of the septum, are generally due to failure in sufficiently exposing the base of these growths. In the case I am about to describe an unsuccessful attempt had been made by one of our New York surgeons to remove the tumor by the Chassaignac-von Bruns method (deflection of the entire nose to one side), but it had to be abandoned on account of alarming hemorrhage.

Digitized by Google

The case is the following:

A. O., aged nineteen years, had scarlatina and, following this, an otitis media during infancy. His present illness began in December, 1898, when he first experienced gradually increasing difficulty in respiration. He was seen by Dr. Gleitsman, of New York, at that time, who removed some polypi from the left nasal cavity. This treatment resulted in an apparent cure until November, 1902, when his breathing again became obstructed. Dr. Gleitsman at that time extracted a much larger polypoid mass from the same nasal cavity, which operation gave the patient further relief from all symptoms until July, 1903, when according to his own statement the growth had again attained considerable size. During the succeeding six months frequent attempts were made to improve his condition by removing small parts of the tumor. In December, 1903, another attempt was made to remove the entire mass with the snare. Failing in this, his physician now referred the case to the surgeon, who in February, 1904, as I have previously stated, tried to do a radical operation according to the method of Chassaignac-von Bruns, but failed. From this time on, until July of the same year, when I first saw him, the patient had no further surgical treatment.

Shortly before he came under my observation he began to suffer from severe epistaxis and gradually the discharge from the left nares became more abundant and offensive. At this time he was indeed in a very low condition. He was pale and emaciated. The hemoglobin had dropped to 40 per cent. He was slightly feverish and drowsy, and could scarcely leave his bed. He was suffering from an almost continuous pain in the left frontal and temporal regions. A pointed tumor mass of firm consistency and pale-red color was protruding from the left nostril. The soft palate on the left side bulged into the mouth and on passing the finger behind the same a soft mass could readily be felt filling up the entire posterior nares. Considering the fact that a fair attempt had been made to remove the growth by extensive dissection of the soft parts, I decided on one of the osteoplastic methods, and of these the Kocher operation seemed the most feasible for so large a tumor.

Digitized by Google

The operation was performed on July 11, 1904. The patient received one-fourth grain of morphine before chloroform was administered. Both external carotid arteries were then ligated, the incisions being immediately closed without drainage. The upper end of the operating table was now slightly raised, elevating the head and shoulders, and the head firmly grasped by the hands of an assistant standing at the end of the table. The steps of the operation as described by Kocher were strictly adhered to, viz., splitting of the upper lip in the median line into the left nostril; division of the mucous membrane where it is reflected from the lip upon the the superior maxillæ in horizontal direction far enough to expose the maxillary border of the nasal aperture; separation of both alveolar processes with a chisel, passing from the nasal aperture in a backward direction through the antrum but leaving the mucous membrane on the lateral aspect of the upper jaw intact; finally, division in the median line with a chisel, thus loosening up the alveolar processes on both sides. Sufficient space for all further manipulations was gained in my case without complete section of the soft palate. The alveolar processes were readily displaced in an outward direction with retractors after division of the mucous membrane on the floor of the nasal cavity and the lower aspect of the growth was thus exposed. The septum had been pushed to the right side, almost obliterating the right nares. The lower part of the tumor was unattached and was readily pushed forward into the large wound cavity, thus bringing into view the upper portion of the growth and its attachment to the base of the skull. After very little dissection at this point and slight traction upon the tumor, the entire mass suddenly came away. Some venous oozing occurred at this moment, which was controlled by a tampon of gauze, and when this was removed a few minutes later, pulsation of the brain was visible, showing that the growth had destroyed part of the bony structure at the base. Hemorrhage had now practically ceased. A small tampon was placed against the dura, its end protruding from the left nostril, the alveolar processes were allowed to come together in the median line, and the incision in the soft palate was closed by several interrupted silk sutures. A

Digitized by Google

medium-sized silk ligature was passed around both middle incisor teeth and firmly tied. This seemed to keep the divided bones securely in place. Finally, the upper lip was sutured.

The tampon was removed after a few days; the silk thread about the incisors was retained about a week. There was a strong discharge from the nose which lasted for several months and for which mild antiseptic nasal douches were given. A pin-hole opening

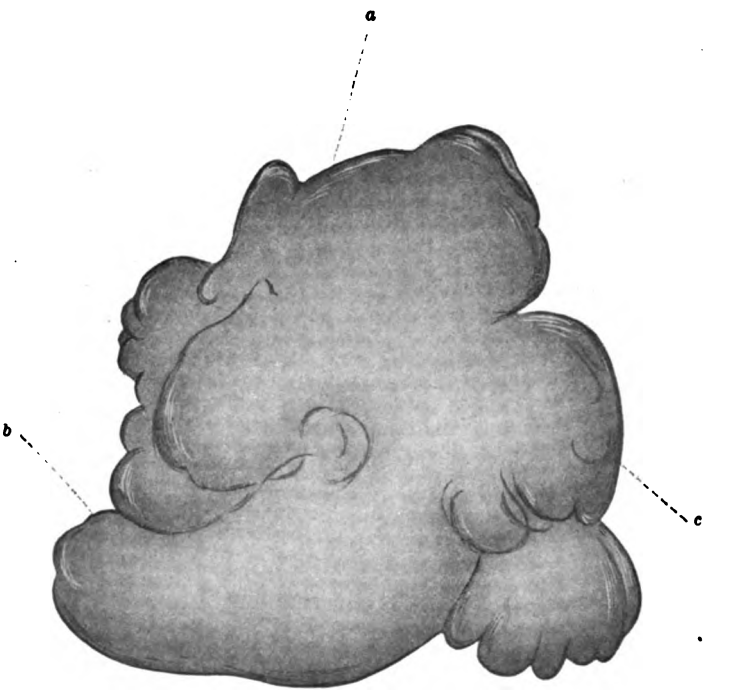

FIG. 1.—Lateral view of tumor after removal; exact size: *a*, attachment to base of skull; *b*, front; *c*, back

appeared in the soft palate. This closed, however, after several applications of nitrate of silver. Convalescence was naturally delayed owing to the enfeebled condition of the patient. His headaches, which had come on before operation, continued after the same, and were very severe at times. They were confined to the left side, and finally disappeared. The tumor macroscopically showed the usual characteristics of a fibrous polyp. The pathol-

Digitized by Google

ogist's report was angiofibroma molle. The patient was examined several months ago. No recurrence of the growth was found in the left nasal cavity. The septum was still very much crowded toward the right side, narrowing the right choana to a mere slit,



FIG. 2.—A. O., aged twenty-one years; two and one-half years after bilateral temporary resection of both superior maxillæ (Kocher) for tumor of nasopharynx.

but the patient could breathe with some difficulty through the right nasal passage.

The above photograph, taken two and one-half years after operation shows no deformity in the upper jaws. No injury has

Digitized by Google

resulted to the upper row of teeth from the operation. The patient is otherwise in excellent health.

The great advantage of Kocher's operation over the other osteoplastic methods is the slight ultimate deformity which it causes, the line of suture through the upper lip being the only resulting disfiguration. The tendency of both alveolar processes to fall back into their normal position, and the ease with which in all published cases they seem to have been retained in the same, make the operation preferable to Partsch's[2] modification in which a similar horizontal section is made through the jaws, but in which both alveolar processes, without separation in the median line, are turned downward into the mouth. Payr's[3] claim that this procedure does not expose the field of operation as thoroughly as Kocher's is, I think, justified.

Kocher's first operation in 1891, reported by Lanz, was done on the hanging head, without any preliminary ligation of arteries. Rather severe hemorrhage must have occurred, since Lanz says: "This operation requires a cool-headed surgeon and one well-versed in the arrest of hemorrhage." In the fourth edition of his surgery (1902) Kocher, in speaking of the operation, recommends preliminary ligation of both external carotid arteries. In 1898 Depage,[4] operating a second time according to this method, applied a temporary ligature to both external carotids. Today the advantages of preliminary ligation of one or both external carotid arteries before operations on the bony structures of the face are so well recognized that no surgeon could willingly miss them. In my own case at no time was there any severe hemorrhage. This was no doubt in part due to the fact that the patient's head was raised almost to the vertical position during the operation on the face itself. The patient, to be sure, was only very superficially narcotized. But, although the external carotids were tied, the head raised, and the patient himself in an anemic condition, his pulse never showed any signs of weakness. It is certainly easier to operate in the erect than in the inverted position of the head, as we are more familiar with anatomical conditions in the former. Kocher favors an inclined position of the body with the neck at

Digitized by Google

the lowest point, the head in turn being slightly elevated. In this way anemia of the brain, venous hemorrhage, and aspiration of the blood into the lungs are avoided. This position seems preferable to the one suggested by Payr, where the body is inclined at an angle of 25 to 40 degrees, the shoulders and neck at the highest point and the head hanging back over the end of the operating table. The head is firmly fixed by some device in this position, but the operator is compelled to stand on an elevated plane to conveniently reach the field of operation. It is well to remember in this connection that operations of the nature of the one under consideration do not often occur in the practice of the same surgeon. While it is easy to accustom one's self to certain positions in familiar operations, in rare and difficult ones one should seek to work with the greatest personal comfort. I have always thought that for operations on the bony structures of the face elevation of the head and shoulders and very light narcosis answer the best purpose. I should feel disposed to try Crile's method of tubage through the mouth, and tamponade of the pharynx for anesthesia in another case of this kind.

REFERENCES.

1. Deutsche Zeitschrift f. Chirurgie, vol. xxxv.
2. v. Langenbeck's Archiv, vol. lvii.
3. Ibid., vol. lxxii.
4. Bulletin de l'Académie royale de médecine de Belgique, 1898.

Digitized by Google

ANEURYSMAL VARIX.

A CASE OF PULSATING EXOPHTHALMOS, TWO CASES OF ENORMOUS DILATATION, AND ONE CASE OF MODERATE DILATATION ON THE CARDIAC SIDE OF THE WOUND.

By GEORGE TULLY VAUGHAN, M.D.,
WASHINGTON, D. C.

ARTERIOVENOUS aneurysms include two varieties known respectively as *varicose aneurysm*, in which the artery and vein communicate with each other through a sac or aneurysm, and *aneurysmal varix*, in which the communication is immediate, without the medium of a sac.

Naturally such conditions occur most frequently where large arteries and veins run in close relation to one another, as in the thigh, the arm, the neck, where traumatism seems to be the invariable cause, such as the passage of a bullet, knife-blade, or other weapon between the two vessels, wounding both and causing a communication at once or later, after distention and giving way of the coats of the vessels. There is one situation where wound or rupture of the artery alone leads to direct communication between the artery and vein, where a large artery runs within a still larger vein, namely, the internal carotid artery in the cavernous sinus. Here the wound may be caused by a fragment of bone in fracture of the base of the skull, or by a rupture of the artery which may or may not have had an aneurysmal dilatation on it, into the cavernous sinus as the result of a blow or strain. The influx of arterial blood under high pressure into the venous current of low

Digitized by Google

pressure going in the opposite direction causes obstruction to the current in the ophthalmic veins, leading to dilatation of those veins, congestion, edema and swelling of the parts drained by them, and to proptosis and pulsation of one or both eyeballs—a condition to which the name of *pulsating exophthalmos* has been given. Pulsating exophthalmos may be caused by several conditions, but the most common cause seems to be a communication between the internal carotid artery and the cavernous sinus—a fact men-



FIG. 1.—Aneurysmal varix of right common carotid and internal jugular vein.

tioned by Rivington more than thirty years ago, when he found in twelve necropsies on pulsating exophthalmos subjects, six cases in which there was such communication. Other causes are aneurysm of the internal carotid in the cavernous sinus without communication with the sinus (case of Barnard and Rugby, *Annals of Surgery*, May, 1904), although, according to Rivington, such aneurysms may exist without symptoms of pulsating exophthalmos, in proof of which he quotes the cases of Holmes and of Hutchinson respectively; simple dilatation of the internal carotid artery; and aneurysm

Digitized by Google

of the ophthalmic artery. Certain vascular tumors, as angioma and sarcoma, may give some of the symptoms of pulsating exophthalmos, and in about 25 per cent. of the cases no lesion of the artery has been found on postmortem examination (Wilder, *Transactions American Ophthalmological Society*, 1907). Both eyeballs may be affected, although the lesion may exist on only one side, owing to the free communication between the two cavernous sinuses through the medium of the circular sinus. The symptoms are well shown in the following case:

Right Pulsating Exophthalmos—Probably Arteriovenous Aneurysm of the Internal Carotid Artery and the Cavernous Sinus; Ligation of the Internal Carotid; Death.

This patient, a woman, aged fifty-three years, who was usually nauseated when travelling on cars, was taken ill while travelling by rail six weeks before I saw her. The symptoms were nausea and violent vomiting, during which she felt something give way in the right side of the head about the ear, followed by a rushing sound which has continued ever since. The nausea and vomiting continued for several days after reaching home, and soon the eyes began to protrude, especially the right. I was called in by Dr. S. M. Burnett and found the patient in bed, in a highly nervous condition, being unable to eat or sleep with any satisfaction, moaning and refusing, on account of the pain, to permit anything like a thorough examination of the eyes. The pulse was 75 and there was no evidence of heart or lung disease. On examining the head, immediately or with a stethoscope, a loud, blowing sound, closely approaching a whistle, was heard all over the head and half way down the right side of the neck, the maximum intensity being in the temple behind the right orbit. A distinct thrill could be felt over the upper half of the great vessels of the right side of the neck, and a marked pulsation was visible on the same side, none on the left. The eyeballs protruded so that the lids could not close over them—the right protruding more than the left—and both pulsated. The patient not only suffered pain in the eyes

Digitized by Google

and head, but was annoyed by the loud, blowing sound, which never ceased.

A diagnosis of aneurysmal varix between the internal carotid artery and cavernous sinus was made and operation advised.

Under chloroform the common carotid artery was exposed at its bifurcation and Dr. Burnett was requested to note the effect

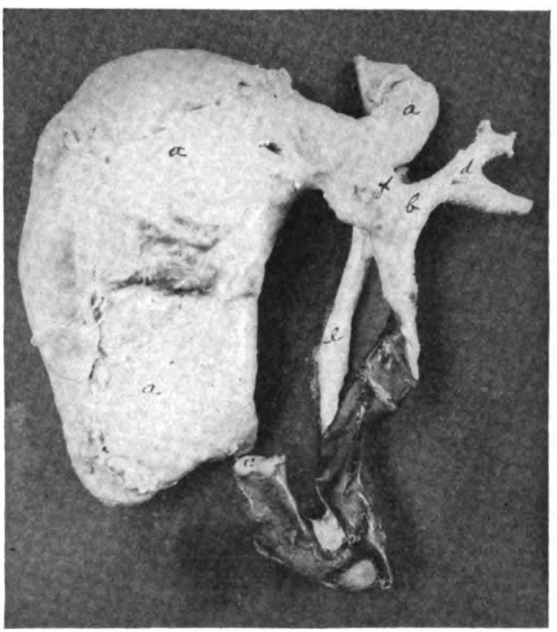

FIG. 2.—Aneurysmal varix, anterior view—communication between artery and vein, just proximal to bifurcation of artery. Sac stuffed with cotton. Carotid artery had shrivelled from drying. *a, a, a.* Internal jugular vein. *b, b.* Common carotid artery. *c.* Arteria innominata. *d.* Bifurcation of common carotid artery. *e.* Pneumogastric nerve. *f.* Communication between artery and vein.

on the sound by auscultation over the temple. Compression of the common carotid stopped all sound and abnormal pulsation; so did compression of the internal carotid, so the latter vessel was ligated about three-fourths of an inch above its origin. The patient was put to bed in good condition, with a pulse of 80. In an hour or two she recovered from the anesthetic, vomited a little,

Digitized by Google

spoke a few words complaining of burning in the neck, and soon became unconscious again. Next morning she was still unconscious, pulse 100, breathing good, eyes about normal as to swelling, no pulsation, and no bruit. At 5 P.M. there were signs of left-sided paralysis; pulse 110. Death occurred next morning, about forty-two hours after the operation. As there was no necropsy it cannot be stated with certainty whether death was caused by pressure of a blood clot or by cerebral anemia. The interval of consciousness on recovery from anesthesia, followed by unconsciousness, would argue in favor of blood clot, while the hemiplegia showing that a large portion of brain was affected—larger than could be involved by the pressure of a clot in the cavernous sinus—would indicate cerebral anemia, the more likely cause of death. The risks of operation are given as follows: (1) Infection. (2) Hemorrhage, immediate or secondary. (3) Cerebral complications. (4) Blindness on the affected side, partial or complete.

Erichsen, quoted by Barnard and Rugby (*Annals of Surgery*, May, 1904), says that cerebral complications occur in 25 per cent. of the patients operated on.

It is difficult to imagine how any other method of treatment in this patient could have been followed by a more favorable result. Digital compression could not have been tolerated by the patient; ligation of the common carotid would have been equally as, if not more, dangerous than the operation performed; and ligation of the common carotid, the external carotid, and superior thyroid all at once—Legouest's method as practised by Ransohoff (*Surgery, Gynecology, and Obstetrics*, August, 1906), would have been still more dangerous in more effectively preventing collateral circulation and in producing cerebral anemia.

Aneurysmal Varix of the Right Femoral Artery and Vein with Enormous Sac Composed of the Femoral and Iliac Veins.

This patient was a white man, aged thirty-one years, whom I exhibited to my classes in surgery in April, 1904. His family history is unimportant. When eleven years old he accidentally

Digitized by Google

stabbed himself with a long-bladed jack-knife about ten inches above the right knee, on the inner side of the thigh. Hemorrhage was severe at first, but it was soon checked by pressure; the wound healed and no further trouble was felt until three years later, when he noticed a peculiar throb at the point of injury. Shortly before this time varicose veins began to appear below the knee and then ulcers. When nineteen years old he was operated on for varicose ulcers, some of the veins below the knee being cut and tied, according to his statement, without improvement. All this time his right thigh, hip, and iliac region were getting larger, and when twenty-one years old he began the use of cocaine, having been told by several surgeons that his case was inoperable, and believing that as he had only a short time to live he might as well be comfortable. He has been using cocaine ever since.

Present Condition. Numerous varicose veins, some of enormous size, are seen extending from the foot up to the ribs, and the entire extremity is enlarged. Thrombi, with calcification, can be felt in some of them. A pulsating swelling is seen and felt along the femoral vessels, with a thrill and bruit most marked about the middle of the thigh. This seems continuous with a very large swelling of similar character which occupies almost the entire right iliac region and extends upward nearly to the ribs.

This patient was undoubtedly for many years a favorable case for operation, and even now a cure might result by cutting off the communication between the femoral artery and vein, either by arteriorrhaphy or by ligation of the artery. The pulsating swelling along the femoral vessels and in the iliac fossa could be nothing else than the enormously dilated femoral and iliac veins and perhaps some of their branches. Cutting off the entrance of the arterial blood would so lower the pressure in these venous sacs that they would probably return, almost if not quite, to a normal condition.

The remarkable fact that the dilatation of the veins is on the cardiac side of the wound, in the direction of the feeble venous current, rather than on the distal side of the wound, in the direction of the strong arterial current, will be discussed after reporting the next cases.

Digitized by Google

Aneurysmal Varix of the Left Femoral Artery and Vein with the Sac Composed Chiefly of the External Iliac Vein.

I saw this patient through the courtesy of Dr. T. N. McLaughlin. He is an officer in the United States Army, about fifty years old, and was wounded during the Spanish-American war; the bullet, a Mauser, entering the left thigh over the femoral vessels, about one inch below Poupart's ligament, and emerging behind. An aneurysmal varix developed very soon, and on examination eight years later the following signs and symptoms were noted: On auscultation a low murmur is heard most distinctly over the region of the old wound, but it can be traced downward along the vessels as far as the popliteal artery and upward as far as the aorta. On palpation a strong pulsation and thrill are felt over the vessels, extending some distance above and below. An oblong, pulsating swelling can be felt distinctly extending upward for about three inches above the wound, evidently the dilated external iliac vein.

This I regard as another favorable case for operation by arteriorrhaphy and venorrhaphy or by pressure on the femoral artery or by ligation of the external iliac artery in combination with arteriorrhaphy and venorrhaphy.

Aneurysmal Varix of the Right Common Carotid Artery and Internal Jugular Vein; Enormous Dilatation of the Vein.

The patient was a colored male, aged fifty-eight years, and a laborer. Nothing noteworthy in his family history. General health always good; he had the usual diseases of childhood; denied venereal disease. Twenty-three years ago he was struck on the right side of the neck by a stone, which cut through the skin in the region of the right carotid artery and caused hemorrhage. He continued at work, but at the end of two hours he had lost so much blood that he became unconscious. A surgeon was called and the wound was sutured. He seemed to make a good recovery from this injury, but nine years later he was injured in the same region

Digitized by Google

by a blow from a piece of timber. A scar is visible in this region. Nothing unusual was observed then, but later he was attacked by occasional paroxysms of sharp, lancinating pain in the cervical region, and after the lapse of one year he first noticed the presence of a small, pulsating swelling on the neck near the jaw, which

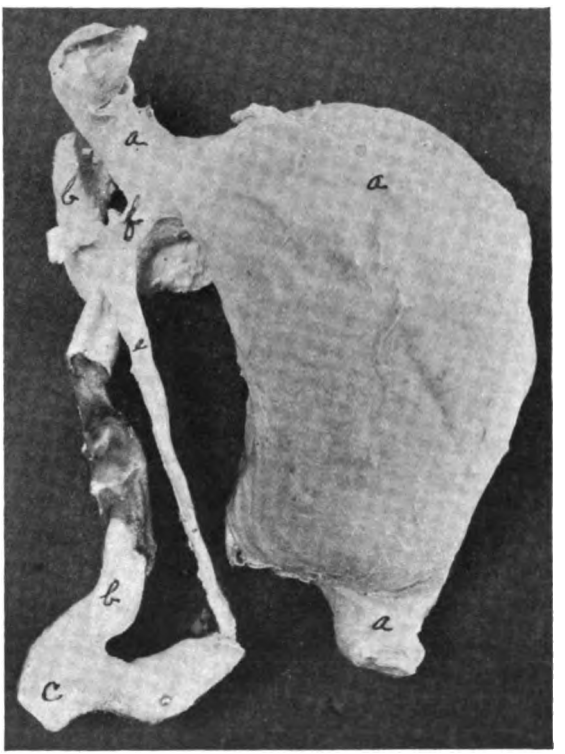

FIG. 3.—Aneurysmal varix of common carotid and internal jugular, posterior view—sac formed by enlargement of internal jugular.

gradually and progressively increased in size to about three years ago, when its growth became much more rapid. As the swelling increased in size dysphagia and tinnitus aurium came on and dyspnea which was not relieved by lying down. Hearing in the right ear is impaired and he occasionally has palpitation of the heart, accompanied by a spasmodic "fluttering" in the neck. The

Digitized by Google

skin over the swelling is normal; the anterior and posterior jugular veins are dilated and distended. The space between the lower jaw and clavicle is filled by a large swelling, almost round, extending from 2.5 cm. below the ear to the clavicle; circumference at base 47 cm.; semicircumference longitudinally, 20 cm.; semicircumference transversely, 27 cm. On palpation a thrill and expansile pulsation synchronous with the radial pulse are felt. Strong compression almost empties the sac, but on relaxation it immediately refills. There is dulness on percussion. On auscultation a low, harsh murmur is heard, loudest at a point one inch below the ear, over the carotid arteries; loudest during systole, but continued through diastole. The murmur is heard all over the chest, especially on the right side, where it obscures the vesicular sounds. The heart is much hypertrophied and has a strong, heaving impulse. No evidence of sclerosis of the arteries.

A diagnosis of aneurysm of the carotid artery was made and operation advised.

Under ether the operation was begun, a pillow being beneath the patient's shoulders in order to make the neck prominent. The pulse was strong, but somewhat rapid, 120. My intention was to expose the great vessels low in the neck and control the circulation by means of padded forceps on the carotid artery. An incision was made over the swelling from above downward to the sternoclavicular articulation, where it was joined by another incision along the upper border of the clavicle, the anterior and external jugular and inferior thyroid veins were doubly ligated and divided, and the angular flap thus made, including part of the origin of the sternocleidomastoid muscle, was turned up, exposing the sac, which was seen to have a very dark color. About this time the pulsations in the swelling were observed to be weaker and slower than they had been, having fallen from 120 to 80 a minute and at the same instant respiration ceased. Artificial respiration was tried for a long time without success, although the heart continued to beat feebly for between five and ten minutes after respiration had ceased. As there had been no injury to the phrenic, pneumogastric, or recurrent laryngeal nerves, and there had been no loss

Digitized by Google

of blood, death was attributed to the anesthetic, ether. A partial necropsy showed that the swelling was caused by the enormously dilated jugular vein, which communicated with the common carotid artery about 2 cm. proximal to its bifurcation by a round opening large enough to admit the tip of one's little finger. The vein, from this point of communication to the jugular foramen and below, where it joined the subclavian, was dilated only slightly beyond its normal caliber. The aneurysmal sac was composed of almost the entire jugular vein, extending from about 4 cm. below the jugular foramen to within about 2 cm. of its union with the subclavian vein. An examination of the photographs submitted will give an idea of the nature of the condition.

In the last three patients there was aneurysmal varix, with dilatation of the vein on the cardiac side of the point of communication. One might think that the greater force of the arterial current would drive or hold back the weak venous current and the result would be that the maximum of dilatation in the vein would be just at the point of meeting of the opposing currents, or on the distal side of this point, in the direction in which the arterial current flows. Two questions are suggested: First, is it the rule to have the maximum of venous dilatation on the cardiac side of the point of communication between the two vessels; and, second, if so, what is the explanation? It would seem that the first effect of the entrance of the arterial current into the vein in opposition to the venous current would be dilatation of the vein at that point as a result of the pressure of the two opposing currents. If the entire arterial current were turned into the vein the effect would be complete reversal of the venous current, and that portion of the vein distal to the point of communication would practically be converted into an artery as to the direction of its blood current. But only a part, perhaps a very small part, of the arterial current enters the vein, not enough to reverse the venous current, yet enough to increase considerably the blood pressure in the vein, and this pressure, according to the law of hydraulics, is transmitted equally in all directions—against the walls of the vein, with the venous current, and against the venous current. If there were no other force acting and the resist-

Digitized by Google

ance were the same on all sides, the effects of this pressure would be the same on all sides and there would be a general dilatation at this point; but the resistance is not the same on all sides. It is undoubtedly least in the direction in which the venous current flows and greatest in the direction from which the venous current comes, so that the venous current, weak as it is, is yet strong enough to move the volume of blood in which this excessive pressure is being made, in the direction of least resistance, which is that of the venous current.

Thus the vein on the proximal side is subjected to excessive pressure until the force of the arterial current so transmitted is gradually exhausted. That there is some resistance to the venous current is shown by the varicose condition of the vein and often of its tributaries on the distal side. This resistance probably depends on the size of the opening of communication and the size of the arterial jet which enters the vein.

Is it possible also, as suggested by Dr. Paul Johnson, that the *direction* of the opening or channel of communication may determine the direction of maximum dilatation of the vein?

Digitized by Google

CONGENITAL DISLOCATION OF THE HIPS.

By OSCAR H. ALLIS, M.D.,
PHILADELPHIA.

The term congenital is open to criticism. It is too comprehensive; it embraces every condition that presents itself at the moment of birth.

The intra-uterine term of existence is not merely one long term of nine months, but, physiologically considered, consists of two periods as distinct from each other as the building of an engine and the management and care of it after it is built. The initial period of intra-uterine existence is the constructive period. It is properly designated by the term embryonic, is the rudimentary stage of existence, and, rudely speaking, embraces the first month and a half of uterogestation. During this time the master builder, from an amorphous vivified cell must construct a perfect miniature human being. During this, the embryonic period, he must construct a framework, joints, ligaments, muscles, vascular nervous nutritive systems, clothe each with its respective garments, and, at the time limit, viz., at the end of six weeks, hand over his work to his successor.

The initial embryonic constructive stage cannot be too carefully considered, nor its importance overestimated. Just who the presiding genius of construction is, where he resides, how he manages his cordon of master workmen, how the countless processes of construction move on without clash or interference, but in perfect harmony, are matters that do not concern us; but that there is such a chief presiding master-spirit, ruling with a firm, exact, intelligent influence, cannot be doubted.

If all goes well, a perfect being will be formed, and punctually

Digitized by Google

at the completion of the time-limit the master genius resigns his charge to his successor. But all may not go well. The artist to whom was entrusted the construction of the mouth and lips may take offence, throw up his half-completed work, and the master builder, unable to induce him by threats or bribes to resume his work, is obliged to hand it over to his successor marred, unfinished, incomplete.

The second stage of intra-uterine management is presided over by a genius of a very different order. Hers is not the bold, resolute, venturesome work of the builder; hers is the gentle fostering care of the mother—hers to take the tiny miniature being and nurse it until it is strong enough to enter upon an independent existence; hers is to take whatever is handed over to her care, no matter what its defects. If a being with exstrophy of the bladder, imperforate anus, bifid spine, eyeless, earless, armless, is put under her charge, hers is to feed and nourish it with a mother's tenderness. She has no power, no skill—if she cared to do so—to take up the imperfect, unfinished work of her predecessor, and complete the lips or give sight to the eye.

The abandoned, unfinished work of the embryonic stage is often spoken of as "arrest of development." This is certainly true, and no better term could be employed if the same term were not used in describing fetal, *i. e.*, *postembryonic* conditions. If a child were born at full term with a hand or foot withered or distorted, while the other foot or hand was plump and fully developed, the former might properly be designated an *arrest of development;* but if the foot or hand were covered with skin, if the digits were tipped with nails, if each member had its full quota of joints, tendons, and muscles, the so-called arrest of development must be assigned to a period *subsequent* to the *embryonic.* During the fetal period accidents and diseases may attack the new being, but blotches, broken bones, and withered limbs belong to a different period—arise from different causes—and are amenable to different remedies than the deficiencies of the embryonic period.

I have made the assertion that the defects, the *deficiencies*, the arrests in the constructive stage of the embryo are not repaired

Digitized by Google

during the probationary term, but appear at birth just as they were left at the conclusion of the embryonic time-limit. I now go farther and say that *all embryonic deficiencies are incapable of completion.* The surgeon can patch up a harelip; he can drain a kidney into an intestine in case of exstrophy of the bladder, and finally close the belly wall in front; but he has supplied no *deficiency.* No matter how deftly he repair the harelip, a smile or laugh will expose his awkwardness and deride his skill.

The reader may think that I have delayed unnecessarily long in emphasizing the two periods of intra-uterine existence, but my reason for doing so will be clear when I state that writers and teachers upon this subject refer the so-called congenital dislocation to the embryonic stage, and state that in some instances the hips were never in their sockets, *as no sockets ever existed.* If no socket were formed and no femoral heads and necks, then, certainly, these defects are properly referable to the embryonic stage; but here a most inextricable dilemma arises, for the same authors and teachers who claim that the dislocation was an embryonic defect also claim that such cases are capable of perfect recovery. It remains, therefore, for them to show why the hip-joint should be the only embryonic defect that is capable of complete repair, or to acknowledge that the so-called congenital dislocations are *postembryonic* defects.

The statistics in regard to congenital dislocations present many interesting and instructive features. One of the most arresting and puzzling of these is that nearly nine-tenths of the cases occur among girls. Dislocations of this particular type have been noticed for centuries, and for centuries the relative proportion between the sexes has been the same, and that which militates strongly against its being an *embryonic* defect is that the victims are usually so fair, well nourished, and well proportioned, that not a suspicion of any congenital deficiency arises until the infant makes its first attempt at walking.

As I have denied the possibility of so-called congenital dislocations being of embryonic origin, so now I deny the reasonableness of the oft-repeated assertion that there is an abnormal relation between the sockets and the heads of the femurs, that the latter grow

Digitized by Google

too rapidly and soon become too large for the shallow and scanty socket, and are hence forced out of it—or that disease attacks the sockets, and in the course of its progress forces the head from its normal position. All these assumptions are mere gratuities, and one answer will serve for all. If they are the result of disease in utero, or disproportioned development, by what logic is the surgeon to assume that a postnatal reduction will restore them to normal physiological conditions, and if disease and asymmetry of development is the cause, why should it involve the hips more frequently than the shoulders—or girls more than boys?

As a possible solution of the origin of congenital dislocations, it has been suggested that they may occur during birth processes, that a deformed (maternal) pelvis, or abnormal position, or the manipulation of the accoucheur may be responsible for the defect; but here, again, I urge the well-known fact that male children are larger at birth than female, and if the foregoing theory be correct, then the greater frequency of congenital dislocation should be found in male children.

Another theory, that the dislocation may be due to fetal muscular action, has been brought forward. Against this theory it may be urged that autodislocations can scarcely be conceived of prior to the fifth month, when the mother recognizes the active movements of the child; and the same arguments hold true that, if due to automuscular action, the male child, which is larger and stronger, should present the defect with greater frequency.

No writer with whom I am acquainted has ventured to assert that congenital dislocations occur under perfectly normal conditions, and are due to the application of forces that under similar conditions produce dislocations in later years. Nor has anyone ventured to explain why congenital dislocations are so much more frequent in females than in males. The views put forth and supported in this article are *that congenital dislocations are traumatisms —that they are due to uterine contractions, and occur during the birth processes.*

For a dislocation to occur under normal conditions, two factors are necessary: First, there must be adequate force; and, second,

Digitized by Google

the force must be applied in the position calculated to effect the result.

First as to the requisite force: This we have in the uterine contractions. It is *during* the processes of the birth act that danger to the uterus itself is most imminent. It is during the stage of active labor that the womb, prodigiously augmented in size and strength, ripe for the climax of its great function, and stimulated by the restless energetic action of the fetus, puts forth its supreme effort. The strength of uterine contractions have been variously estimated, but I have no desire to quote them; suffice it to say, that only to the pregnant uterus and only in the birth act, and at no other time and under no other conditions, is rupture of the uterus possible. Rupture of the uterus, with extrusion of its contents in whole or in part into the abdominal cavity, is fortunately not a frequent accident, but sufficiently so to occasion no surprise. *Here, then, we have a force sufficient to produce dislocation of the hips*, and it only remains to show how such a force can accomplish such an end.

One of the arguments, and possibly its strongest, urged against the possibility of traumatic dislocations from uterine contractions and during the passage of the fetus through the birth canal, is that the limbs of the fetus cannot be made to assume a position that would make dislocation from uterine contraction possible. This theory is based upon the teachings of Sir Astley Cooper and accepted by his long line of followers, viz., that dorsal dislocations are due to force applied to the long axis of the limb, *i. e.*, when it is extended upon the trunk. Such a position cannot be assumed in utero, and were the theory sound, the argument against the possibility of dislocations from uterine contractions within the uterus, *i. e.*, during the birth processes, would be conclusive and unassailable. But the theory of Sir Astley Cooper is unsound. His theory that dislocations take place when the femur is extended cannot be verified in experimental work, and, if not impossible, is extremely improbable, while dislocation of the flexed femur is easy of accomplishment.

In experimental work upon the adult cadaver with the femur flexed to a right angle with the trunk, dislocation is possible and easy

Digitized by Google

of accomplishment without injury to any part of the bony pelvis; but attempts to dislocate the hips in the extended position with force exerted in the long axis of the femurs, will be followed by fractures of the rim of the socket, of the socket itself, or the pelvis, or some part of the shaft or neck of the femur. In the extended position, the rim of the socket, which receives the brunt of the attack, is strongest and deepest, the socket has its greatest depth, and the portion of the capsule that covers the head is its strongest part. All of this is reversed when the femurs are flexed to a right angle with the trunk. Under these circumstances the head of the femur can be forced from the socket without injury to the bony parts. With appropriate apparatus, I have repeatedly dislocated both thighs in the adult cadaver simultaneously by means of force applied to the knees flexed at right angles to the trunk. I am well aware that there is not a close analogy between uterine contractions upon the fetus in the birth act, and force applied to the flexed knees of the adult cadaver through powerful levers, but the conditions are sufficiently analogous to suggest to any unprejudiced mind that the flexed position is a possible, and not, as declared by the opponents of the theory, an impossible one, for dislocations.

MECHANISM OF DISLOCATION OF THE HIPS THROUGH UTERINE CONTRACTIONS.

Another question and one that has always resisted every attempt at elucidation is, Why is the disproportion of cases so largely in excess among female children?

Let us imagine the relations of the uterine content to the uterine container. The latter is a symmetrical muscular structure, rudely pear-shaped. Transverse sections would approximate the circle; longitudinal sections, that of an egg. To such an enclosure the uterine content must accommodate itself. The head must be bent forward on the chest, the vertical column arched backward, the thighs flexed upon the abdomen, and the legs flexed upon the thighs (Fig. 1). While the uterus is in repose there would be no undue

Digitized by Google

pressure upon its contents, but during the birth act, uterine contractions, sometimes uniform and symmetrical, sometimes partial or unequal, alternating with periods of uterine relaxation, may present conditions favorable for catching the knees of the half-born child (Fig. 2) at right angles to the trunk, and in a position I have found experimentally the most favorable to effect dislocations of both hips at the same instant.



FIG. 1

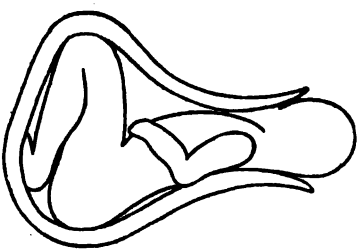

FIG. 2

But the possibility of dislocation from uterine contractions does not explain why congenital dislocations are relatively so much more frequent among female children, and to this point I feel that we have an argument in the size and weight of the sexes at birth. Sta-

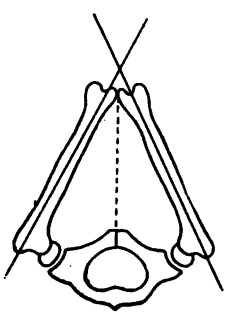

FIG. 3

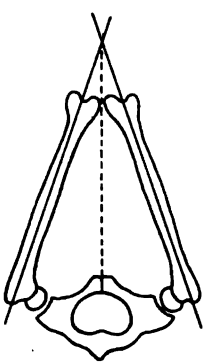

FIG. 4

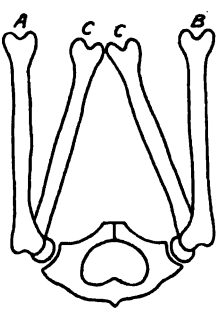

FIG. 5

tistics show that male children are longer, larger, and heavier than female. If, now, we assume that the pelvis of the female at birth is as wide as that of the male, we will see that pressure applied to the

Digitized by Google

knees in the female (Fig. 3) will be applied more obliquely than to the male (Fig. 4), from the fact that the femurs of the female are shorter than the femurs of the male, and this greater obliquity is highly favorable to dislocation from pressure. When I have dislocated single hips by means of leverage and direct pressure, I have found it much easier to do so in a state of adduction (Fig. 5, *c c*) than when the force was applied perpendicularly, as in *A* or *B*. To the foregoing reason, a purely mechanical one, I attribute the greater frequency of dislocations of the hips in female children.

Again, it will be said that were this a recent traumatism the newborn child would manifest it by crying out with pain. But what infant at birth does not cry out lustily? Indeed, if it does not, the accoucheur generally spanks it until it does. Further, it is alleged that if the hips were dislocated, the attending physician would notice the deformity, but not if the limbs are moderately flexed on the belly, and who ever attended a birth process that did not see the newborn infant with flexed or semiflexed limbs? Indeed, I have seen a nurse often strenuously resisted, in her efforts to apply the diaper impeded by the strongly flexed thighs of the newborn babe. Congenital dislocations of the hips are infrequent, and hence unlooked for. Where is the physician who ever discovered an imperforate anus? This is as frequent as congenital dislocation, yet no physician ever detected one at birth. It is owing to the fact that the diaper remains unsoiled that attracts the attention of the nurse to the possibility of something wrong.

There is a question that presents itself in this connection, and should not be passed, viz., that occasionally a child will be found with single dorsal dislocation, and, still rarer, when the dislocation will be on the inner plane of the pelvis. In experimental work, when attempting to dislocate both hips simultaneously, I have not infrequently dislocated but one, and this has suggested the answer to the first query, viz.,, that the uterine contraction may catch only a single knee; or, even catching both, the conditions may change the instant one hip is dislodged, and with its dislodgement the contraction ceases and the other hip escapes. Even when both have been dislocated, I believe the manipulations of

Digitized by Google

the nurse may restore a recently dislocated hip to its socket. In washing the nates and in putting on the diaper she will flex both hips, even lifting the after-parts of the child from her lap (Fig. 6). She may then forcibly separate them (Fig. 7) to get the diaper between the limbs and then press down the knees (Fig. 8), and these manipulations are precisely the same that a surgeon would follow were he intending to restore dislocation of the hip. In clinical efforts to restore a hip by measures similar to these, a dorsal dislocation has been converted into an inward or obturator, and this may account for the occasional dislocation inward of the so-called congenital variety. Only by manipulation of the nurse can an outward dislocation of the hip be converted into an inward. I cannot conceive it possible for the thigh to be flexed and *abducted*, two essentials for the production of an inward dislocation, while the thighs of the fetus are still within the uterine cavity.

FIG. 6

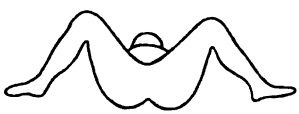

FIG. 7

FIG. 8

The fact that no inconsiderable number of so-called congenital dislocations are unilateral, the other hip being sound and perfect, militates against the theory of embryonic defect, or disease, or muscular action of the fetus, since it is hardly probable that a single hip would be involved as an embryonic deficiency, or intra-uterine disease or accident while the remainder of the entire construction were perfect.

The pathology of this affection is now being enriched by the observations of many careful workers, but, as few children with congenitally dislocated hips die at birth, the profession will wait a long time to get reliable information upon this point. The older writers met with a few scattering cases in pathological museums and in dissecting-rooms, and from these made deductions that

Digitized by Google

largely influenced the medical profession in its treatment of this condition. I have examined a number of these specimens and find quite a uniform condition in the changes produced in the pelves, the most important of which is the uniform, shrivelled, shallow, somewhat triangular condition of the acetabulum. The changes in head and neck of the femur are less uniform. These may be classed as follows: (1) Those in which the head of the femur is entirely absent, with scarcely a trace of the neck and no vestige of the head; (2) where the head is flat like a button with short sessile neck; (3) when the head is undeveloped, but moderately round or slightly faceted with fairly good neck.

Here we have three distinct, clearly defined conditions, markedly dissimilar, all of which are susceptible of explanation after the theory I have advanced, viz., that congenital dislocations are traumatisms and occur as the result of uterine contractions in the process of labor.

I will take up the three pathological conditions in the order given: First, those in which there is no head or neck, in which the shaft of the femur ends apparently in the great trochanter. It is this class especially that have given rise to the belief that there never was either head or socket. In this class I am of the opinion that there never was a true dislocation, but that the uterine contractions (Fig. 2) broke the neck of the femur, or, what is practically the same thing, separated the head from the neck, leaving the head in the socket and driving the trochanteric end of the shaft outward and downward as in a dislocation. This suggestion as an explanation of the pathological condition referred to is derived from experimental work. I have never been able to dislocate the femur of a full-term fetus; my efforts invariably separated the shaft and neck from the epiphyseal head. Were such an accident to take place, the child, when it reached the age for walking, would present all the symptoms of congenital dislocation. The little spur of a neck would gradually shrink, atrophy, and disappear, and the shaft end in the great trochanter. The child would walk supported mainly by the untorn part of the capsule, precisely as it does in congenital dislocation.

Digitized by Google

Second. Cases in which the head is flat like a button. In this class of cases the head is probably forced through a rent in the capsule, bringing the head directly against the bony wall of the ilium, where it is to make its new socket. As the head is entirely outside of the capsule there is nothing to compel it to retain its spherical globular form, and when the child begins to walk the head becomes flattened like a silver dollar against the dorsum of the ilium.

In the third class the uterine contractions expelled the head from the socket without rupturing the capsule, hence the head always had its sheath or capsule and was controlled as in a sling. As it no longer had a perfectly fitting socket, the movements of the child compelled the head of the femur to move upon uneven bony surfaces, and hence the inequalities or facets that I have noticed on a small, round, facetated head of an adult that had suffered from birth from dislocated hips.

The fact that I have never been able, after repeated efforts, to dislocate a hip at birth might lead to the conclusion that it could not be done in utero, but the conditions are greatly altered. My own efforts were made through rotation, and this is unlike the intra-uterine procedure. Again, dislocation through pressure on the flexed knees, if done in utero, gives the infant's pelvis a strong, well-fitting base of resistance (Fig. 2), which would make dislocation possible without injury to the pelvis, while attempts to dislocate the hips through vertical pressure after birth cannot be as favorably contrived.

In regard to the prognosis in this class of cases, it is hardly necessary to say more than that the unfortunate victims are handicapped for all active duties of life. While the affection is not painful, it is crippling, and the gait renders the person awkward and conspicuous. No girl with congenital double dislocation of the hips should marry, as her only hope of issue must be through Cesarean section. Every case of congenital dislocation that has attained to puberty and walked from infancy has too narrow an anteroposterior diameter of the pelvis to admit of safe parturition, and all such pregnant cases should fall into the hands of the experienced laparotomist.

The diagnosis of this affection deserves careful consideration

Digitized by Google

from every practitioner of medicine. This is especially important, for it is not infrequently the assurance of the family physician that there is nothing the matter that leads the anxious mother to dismiss her fears. I make this statement from no small experience. As a rule, the mother will notice that her child does not walk right. Under such circumstances it should be stripped absolutely naked and permitted to walk up and down the room. The most notable sign in double dislocation is the *protuberant* belly, and the *forward arched* lumbar vertebra. Both of these signs are due to the same defect, namely, the position of the heads of the femur posterior to

FIG. 9

the socket. This compels the child to throw its shoulders well back to preserve the centre of gravity. As the tendon of the psoas muscle is dragged backward this muscle will tend to drag the lumbar vertebra forward.

In double dislocation the trunk of the child will be apparently lengthened, while the limbs correspondingly shortened. As the child walks there will be a noticeable limp if only one hip is out, but a swagger, loose-jointed gait if double. If the examiner's hands are placed over the hips while the child walks the trochanters will seem loose and wobbly.

For the recumbent examination, a perfectly flat surface should

Digitized by Google

be selected—a bed or cushioned lounge is not as reliable. With the child lying flat on its back, press both knees down upon the table. If this is accompanied with decided forward arching of the spine it will be due to the same cause as mentioned in the erect posture (Fig. 9). Most reliable information can be obtained by comparing the knees when flexed at a right angle with the trunk. Under normal conditions the femur equals in length the tibia and tarsus, *i. e.*, the distance from the knee to the socket is about equal to that of the knee to the sole of the foot.

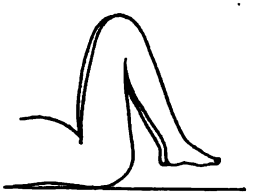

FIG. 10

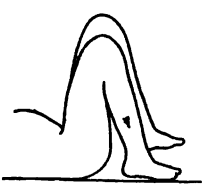

FIG. 11

FIG. 12

FIG. 10.—Represents normal conditions, both heels on level with hip-joints when knees are perpendicular, and both above the surface of the table.

FIG. 11.—Represents right hip dislocated dorsally; under these circumstances the knee can be flexed to the perpendicular and the foot be made to lie on the table. Compare right and left knee—right and left foot

FIG. 12.—End view of Fig. 11.

It is a confirmation of the above symptoms if the head of the femur can be readily made to shift its position. If dorsally dislocated, the child recumbent, the pelvis resting upon the operator's hand, the femur can be flexed and extended, raised or depressed and the head will be felt to move. In comparing the lengths of the femurs, if one or both are dislocated, the pushing up of one and drawing down of the other will show discrepancies that will not be possible in normal thighs. Finally, if there is doubt, the *x*-rays will settle the question and bring out the condition of the head and neck, and furnish much information relative to the outcome of treatment.

TREATMENT. *Open Surgical Methods.* These are now generally reserved for cases that have resisted milder measures, and, fortunately, are not as frequent as formerly.

Digitized by Google

Reduction by Means of Manipulation. The Lorenz Method. This is popularly known as "the bloodless method." It consists of extreme manipulations, in which all restricting bands are overcome prior to attempts at reduction. After anesthesia the thigh is hyperflexed until the toe can be made to touch the ear, then *hyperextended* to the extreme limit of safety, even endangering the femoral vessels, then flexed to the perpendicular and abducted. Abduction brings the adductor muscles into prominence, and these are ruptured by forced abduction with one hand on the knee and direct pressure in the groin upon the tendons of the muscles. When the abduction is complete the knee lies at a lower level than the pelvis, in an absolutely helpless condition. All this preliminary to any attempt at reduction.

To effect reduction, an assistant made extension by traction upon the ankle in the long axis of the body, while counterextension was made through a perineal band carried above the head and shoulders and fastened to a staple or entrusted to assistants. Professor Lorenz took his seat by the side of the child and, grasping the thigh and pelvis, brought direct pressure against the great trochanter by means of his two thumbs. Reduction was announced by the sudden passage of the head from an outward to an inward position. If the head resisted the efforts at reduction, the traction upon the thigh was varied, and if reduction was still found impossible, the thigh was again submitted to hyperextension, hyperflexion, and hyperabduction.

Having replaced the hips, the next step was to apply a retentive apparatus. This was by no means the least interesting and instructive part of the demonstration. The child, with thighs flexed and abducted to, or even below, the horizontal, was placed with the sacrum resting on a specially devised stool. The pelvis and thighs were then entirely enveloped in cotton and the entire pelvis and thighs encased in plaster of Paris. As the plaster was hardening, it was cut away from the perineum and belly, leaving sufficient above the pubes to bind the cast in front.

The advantages of this dressing are many. As it is applied by the surgeon, he alone is responsible for its effectiveness. It affords

Digitized by Google

an easy vehicle for transporting the child, and as it is to be retained without change for five or six months, the pains taken in its application are fully rewarded.

REDUCTION BY MANIPULATION—PRELIMINARY VERTICAL TRACTION—AUTHOR'S METHOD.

After full anesthesia the pelvis of the child is firmly secured to the table by means of bandages and hooks placed at the perineum

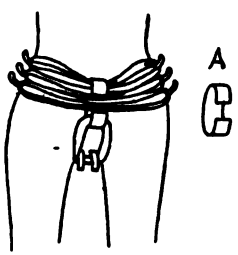

FIG. 13

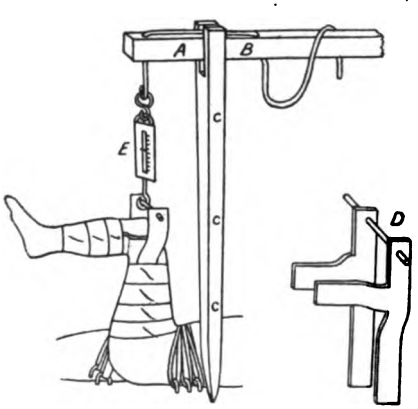

FIG. 14

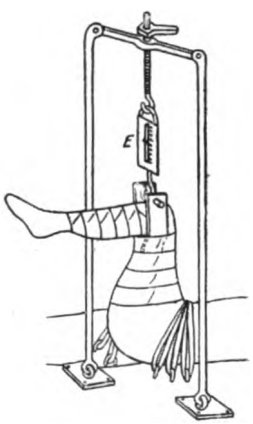

FIG. 15

and sides of the pelvis. To prevent the bandages from interfering with the free manipulation of the hip, it is passed over a bent piece of iron, as represented in (Fig. 13, *A*). After securing the pelvis to the table, angle irons (Fig. 14, *D*) are secured to the thigh and leg, and, this done, vertical traction through the lever is made

Digitized by Google

without fatigue for any length of time deemed necessary. With the spring balance (*E*) between the short arm of the lever, and the angle irons attached to the limb, the exact amount of traction can be seen. Traction of from twenty to thirty pounds is made for about fifteen minutes, when the lever is detached and an effort made to replace the dislocated femur. This is done by seizing the thigh with the right hand and lifting it upward until the head of the femur is upon a level with the socket and then making abduction against the thumb of the left hand, pressing against the great trochanter. The ease with which reduction is often accomplished, the entire absence of shock, the favorable condition the following day, all contrast strongly with the conditions I had witnessed in the method employed by Professor Lorenz. In the apparatus used, the long fulcrum *c c c*, Fig. 14, whose base is near the pelvis, and which is parallel with the femur, permits of every motion that is desired in applying traction. Thus I am able to lift perpendicularly, abduct, adduct, flex, extend, circumduct, and rotate, all the time gently increasing the traction, and this, too, with a knowledge of the amount of traction I am using.

I employed pelvic fixation and the lever for the first time in the hospital of Jefferson Medical College in the presence of Professors Gross and Brinton, Drs. Levis, Hearn, Barton, and others, in 1884, in efforts to reduce a recent dislocation in an adult, but I never thought of employing them in congenital dislocations until after witnessing the method of Professor Lorenz. Congenital dislocations are necessarily chronic and necessarily attended with shortening of certain structures, as muscles, tendons, ligaments, and fascia, which must be *stretched*, *ruptured*, or *divided*. I have never heard the reasons that induced Professor Lorenz to resort to rupture in preference to division of tendons subcutaneously, but I imagine that when he began his work he resorted to the tenotome, but found that after he had divided the most prominent tendons he was still baffled and was obliged to resort to force to overcome the remaining obstacles. Hence, he laid aside the tenotome and employed only rupture, and in his demonstrations in Philadelphia, at Jefferson Medical College Hospital, he ruptured every struc-

Digitized by Google

ture that opposed the freest, widest latitude of motion before he made a single effort at reduction.

What Professor Lorenz accomplished by rupture I have done with the lever. As already said, the long fulcrum enabled me to circumduct the limb so as to put traction upon resisting structures from all directions, but experience taught me that the long fulcrum rendered my lever somewhat *uncontrollable*, and suggested two parallel fulcra, as represented in Fig. 15. This still further differs from the first, as it substitutes the screw for the lever. In children under three years a force of thirty pounds, kept up for fifteen minutes, will often be sufficient, but in older children the traction force has been carried to 100 pounds.

There is another point that I feel is worthy of mention, and that is the difference in the method of reduction. Professor Lorenz employs *horizontal* traction. With the ankle in the hands of a powerful, experienced assistant, the head of the femur was brought down to a point opposite the socket, and then, by an effort, that to the onlookers seemed to call forth all the operator's strength, the head was forced from the outer plane into a position corresponding to the normal relations. That such a procedure would drive a portion of the capsule before the head seemed to me unavoidable—at least, in a certain number of cases—but whether it did or did not, the method adopted was the same in all cases. In the method I have adopted I have resorted to no force in the actual reduction, and hence I could feel as the head passed over the division between the two planes of the pelvis that it had entered a depression simulating the normal socket.

Professor Lorenz puts his cases immediately in plaster of Paris, and does not remove the first dressing for six months. A second plaster dressing is then applied, with the thighs slightly adducted and flexed to a position approximating extension, and this is worn four months more, after which there is no further plaster dressing. During the ten months of plaster encasement the child is allowed every rational privilege. It can sit in chairs devised for the purpose; it can be carried about by nurse or mother, and, in certain cases, locomotion is enjoyed by the little captive.

Digitized by Google

In my first case I adhered closely to the teaching of Professor Lorenz, but found that, with all possible care, the dressing was very irksome in the hot days of summer. The principle emphasized in the Lorenz dressing is sound, and cannot be departed from, viz., flexion and abduction, and the primary dressing of plaster of Paris is sound and practical; but, as a dressing after the first month, I think it objectionable. First, it does not permit that degree of cleanliness that is desirable. In a child, the entire body should be washed at least once a week, and this is obviously impossible while it is encased in plaster. But my most serious objection to plaster of Paris is that it does not permit any latitude of exercise. With the thighs flexed to a right angle and horizontally abducted, there is scarcely a possibility of redislocation; but this is the only advantage, and the question arises, Cannot the child be placed in an apparatus that will permit it to use the limbs *in an abducted position?* I have advantageously employed such an apparatus, which gave the child the freest flexion and extension, and which was so arranged that adduction was increasingly permitted. To accomplish this, however, I did not permit the child to sit up during the entire course of treatment. No hard-and-fast rules can be laid down, but, speaking generally, I would say that the child can be advantageously placed in plaster of Paris for a month, and in an apparatus for six or eight months, and without apparatus for the balance of the year, *but all this time* the child should be reclining. The advantage of the reclining posture is that when the child is exercising its limbs there is no greater weight to the newly constructed socket than that of the limb itself, and it is encouraging to the parents and interesting to the child to see the daily progress in the use of the limb in its new position. It will be objected that the child is kept on its back for an entire year, but when it is stated that it can have a daily bath, if necessary, that it can be carried about from room to room or out in a carriage, the privation is materially mitigated.

It will be urged, as in favor of the fixed plaster-of-Paris dressing that the child can even walk about, but it walks without using the hip-joints. The plaster dressing immobilizes the hips, and if

Digitized by Google

there is motion in the joints it is very limited and in very narrow range. The child may be able to walk about, but it walks by the aid of the plaster cast and by not the use of the new-formed joints. A year is short enough time to expect a good recovery, and the more of this year that the child can have for gaining the full range of motion of the hips, the better. Hence, I adopt an apparatus that limits adduction, but does not interfere with flexion and extension.

DEGREE OF SUCCESS.

In two cases that I have had, both under three years, females, with only one hip dislocated, the recovery has been, so far as ascertainable, perfect anatomical successes. It is only after a large experience that reliable data can be obtained, and one is not a little surprised to read that Professor Lorenz claimed only 50 per cent. of perfect recoveries. It would be interesting, as well as profitable, if the reasons for failure in 50 per cent. could be obtained. In attempting to account for failures, Müller quotes Lange, who says that in certain cases there is a change in the relations of head and neck of the femur to the shaft, that the angle is rendered more obtuse and the neck rotated upon the shaft. Adopting this view, Müller asserts that in this class of cases the Lorenz *reduction* is not a veritable reduction, but rather a shifting from one position to another, and the child recovers from a dorsal dislocation to find it has a forward intraspinous dislocation. Müller substantiates his theory by adopting a method of replacement suited to those cases, and claims recoveries that baffled the Lorenz method. He even asserts that by adopting his method the remaining 50 per cent. of cases can be perfectly cured. For his method the reader is referred to the report of the American Medical Association, held at Boston, 1906, section of Surgery and Anatomy.

The large percentage of failures has elicited much speculation and investigation among surgeons. I shall not attempt a summary of them, but content myself with two: First, the method of reduction; second, the mode of permanent dressing.

Digitized by Google

As to the method of reduction: This is through forced extension. It is the method of Sir Astley Cooper, who believed that the only resistance to reduction lay in the muscles. Hence, the great London surgeon resorted to emetics, the lancet, and, having reduced his patient to the limits of exhaustion, applied compound pulleys. As he believed the dislocation occurred with the limb extended, he argued that extension in the long axis of the body was logical and the only feasible method. Lorenz follows this theory to the letter. Believing that muscular contractions have been the chief hindrance, he tears every shortened muscle in two. He requires nothing but an anesthetic to render insensibility and relaxation complete. So much for the preparation. The reduction is *not done* by manipulation, but by most strenuous exertion. The traction is made from the ankle, and often the efforts of the

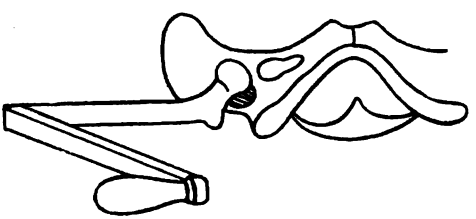

FIG. 16

powerful assistant are baffled. The head is never *replaced;* it is rather *forced* into the socket, and this forced replacement is accountable for a portion of the failures. There can be no reasonable doubt that the capsular membrane is at times forced before the head, or that the rim of the socket is seriously damaged by such heroic measures, or that the capsule may be torn up from its capsular attachment and driven before the head.

Second, the mode of permanent dressing: The plaster dressing is applied with the thighs flexed to a right angle and abducted *so that the knees lie at a point on a level with or below the socket.* What are the possible conditions? The reduction may have been happily accomplished and everything favorable. But in this extreme abduction the head is not in the *bed* of the socket, but pried out of it by the neck resting on the rim of the acetabulum (Fig. 16)

Digitized by Google

Under the most favorable circumstances the head cannot lie in the socket. The most that can be said of it is that it lies in the region of the socket. Even if the head has been reduced within the capsule the position of extreme abduction will tend to thin and stretch it, while the thickest and strongest part of the capsule, the ileo-femoral ligament, lies chiefly to the upper and outer side of the head. But there is another possible condition, viz., that the *trochanter* may be carried into the socket, and in such a case, when the limb is finally brought down in extension, the head will revolve to a position in the inner side of the inferior spine of the ilium, because the trochanter in the socket is the pivotal point of action.

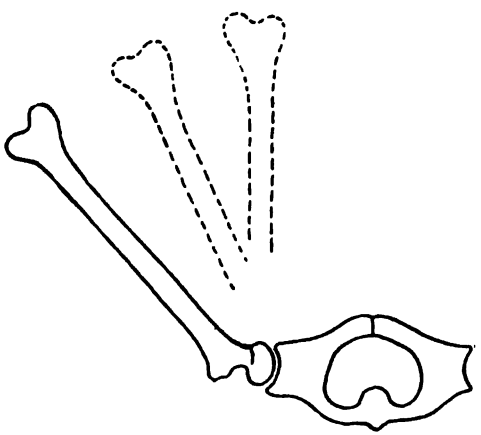

FIG. 17

The course that appeals to me, and which I have pursued with perfect satisfaction, is to fix the hip in plaster for the first few weeks. This I do for convenience and because the hip, being immobilized, will more rapidly recover from any traumatism that has been inflicted. At the end, then, of a month the child can be put in an apparatus with adjustable wings, to which the abducted thighs can be loosely bound, and gradually the adduction can be increased until the perpendicular is reached (Fig. 17). The apparatus I employ permits of free motion, save in abduction and adduction, *i. e.*, there is no obstruction to flexion and extension. In this way it is possible to anticipate the amount of service the child

Digitized by Google

will have when it begins to walk. As already stated, after ten months the apparatus is removed and the child allowed its freedom while still in the recumbent position, for two months or more.

After Professor Lorenz has ruptured every muscle that resists his preliminary manipulations, he invokes the services of a powerful assistant to make traction upon the limb, while he, by direct pressure, drives the head into the socket. What, I ask, is still resist-

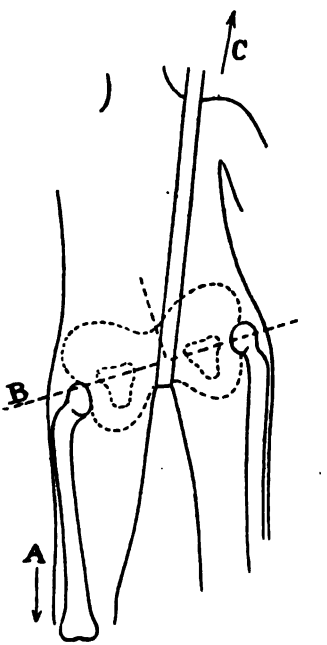

FIG. 18

ing him? He has torn all the muscles! The resistance must, therefore, come from something that he cannot tear, and that something is the iliotibial band. It is this that compels him to invoke the services of a powerful assistant. I have attempted to tear the iliotibial band in adult cadavers and have never succeeded. After the traction of one thousand pounds the pelvis has given way with a crash, but the *iliotibial* bands were as sound as before the experiment. When Professor Lorenz's assistant makes the traction

Digitized by Google

(Fig. 18 *A*, arrow) he also makes abduction, and through abduction and traction the head of the femur through powerful pressure is driven beneath the iliofemoral ligaments suddenly, as with a visible spring, which is apparent to every observer, and apparently into the socket. The canting of the pelvis and associated abduction removed the pressure upon the great trochanter from the iliotibial band which the traction created, permitted the head of the femur to descend to a point opposite the socket, when the operator, with the aid of his skilled and practical assistant, drives the head into the socket. Lorenz acts on the theory that if congenital dislocations are to be reduced at all they might as well be reduced at a single sitting, as during a protracted series of efforts. Hence, he does all his traumatism at once—forces the head into the socket region and hopes to benefit every case and to perfectly cure the majority.

In marked contrast with Sir Astley Cooper's method of treating recent clinical dislocations of the hip by horizontal traction method is the method of fixation of the pelvis and *perpendicular* traction. What the London surgeon often required hours to accomplish with compound pulleys is now happily accomplished in a few seconds by unaided manual traction, and the same principle holds good in congenital dislocations. Traction directly upward, *i. e.*, at right angles to the horizontal trunk, is made with flexed femur and flexed knee. When, in dorsal dislocations, the thigh is flexed to a right angle the *head* of the femur lies directly below the socket. In the flexed position, the skin, femoral vessels, adductor and flexor muscles, capsule and fascia, are all relaxed, and hence, though the dislocation is of long standing, will offer a minimum of resistance. Thus the surgeon with a lever or screws (Figs. 14 and 15), guarded with a spring balance, and with a minimum degree of traction, lifts the head to a position, if necessary, above the level of the socket and holds it there without effort for a space of fifteen or twenty minutes without fatigue to himself and a minimum of shock to his patient. During all this time his eye rests upon the spring balance, which keeps him informed of the exact amount of force employed, and when, in his judgment, a sufficient amount of

Digitized by Google

stretching has been secured, he unhooks the apparatus from the knee, seizes the thigh with one hand, lifts it to a level with the socket, and abducts, while with the thumb of the unoccupied hand pressure is made against the great trochanter. If, under these gentle measures, the head does not slip over the rim and into the socket, resort to stretching should again be made. The reduction should *be easily accomplished* if the hands of the manipulator are to judge of the replacement.

A final word upon the conditions after reposition of the head. If the head is replaced in the socket, whether it has been replaced within the capsule or driven a portion of the capsule before it, *two* aids must in all cases be invoked to secure a satisfactory recovery. The head must lie beneath the strong part of the capsule, *i. e.*, beneath the iliofemoral ligament. This part of the capsule is the safeguard against the ascent of the head in walking. It is the part of the capsule that in the erect posture prevents the head from jutting forward. If, therefore, the head has been carried into the socket it must lie beneath this part of the capsule; and, as no one can know positively whether a part of the capsule has been driven before the advancing head, it behooves the surgeon to give the patient ample time to make a new socket. Hence, I advocate a full year of dorsal recumbency, the greater part of which, with the thighs free to move with only restricted adduction.

Another most important *aid* to complete recovery is the fascia lata. Few are aware that the fascia lata preserves a gentle, continuous pressure upon the normal hip and keeps it adjusted to the socket; few are aware that progression would be impossible without the aid of the fascia lata. Hence, when the child has its hip replaced in the socket with the strong iliofemoral ligament in front of the femoral head and the iliotibial band making pressure against the great trochanter, the ultimate cure may be most satisfactory and the child have every assurance that normal development, with normal activities, will result. As the fascia lata during the years of dislocation will not grow as rapidly as it does in normal conditions, the child's first effort at locomotion may be hindered, and if only one hip has been treated, adduction may be restricted and the

Digitized by Google

formerly dislocated thigh may seem longer than its fellow. *This is a good sign of perfect reposition.* A few months of walking will remedy this, and then the cure will be established.

I cannot close without a word of thanks for the encouragement Professor Lorenz has given American surgeons in the treatment of this heretofore greatly neglected deformity. While few resort to his extreme measures, there are hundreds of surgeons today who are indebted to him, and who have had successes that a few years ago they would have deemed impossible.

Digitized by Google

SUBCUTANEOUS RUPTURE OF THE SPLEEN.

By ELLSWORTH ELIOT, JR., M.D.,
NEW YORK.

THE bibliography dealing with the subject of the subcutaneous rupture of the spleen has been so carefully collated in the statistics of Bessel-Hagen, of Berger, and of Carstens, as well as in the subsequent recent statistics of Hörz, that little attention need be devoted to that part of the subject. It is interesting to note that this condition was diagnosticated and the patient's life saved by splenectomy as early as the latter part of the seventeenth century, and that, subsequent to that time, isolated instances of successful splenectomy for either a prolapsed spleen or for rupture continue to be reported until, in modern times, the introduction of aseptic methods and the more widely diffused skill in diagnosis have greatly multiplied the frequency and success of this life-saving operation.

That pathological conditions of the spleen, especially those due to the infectious fevers, the acute and chronic forms of malaria, the various forms of pernicious anemias, and the different varieties of neoplasms predispose to rupture of that organ, and that, under such circumstances, rupture may occur after a relatively slight trauma, are well known facts. This paper is concerned only with the consideration of those cases in which, at the time of the accident, no one of these different conditions were present. Under these circumstances, the spleen may be ruptured by violence received directly from some rounded object in the left hypochondrium, beneath the costal arch, or indirectly through the contiguous ribs, of which one or more may be fractured; or the laceration may be due to some violence acting upon the abdomen as a whole,

Digitized by Google

such as occurs in run-over accidents. There are, also, a few instances of rupture of this organ in which the violence is received on the right side, a form of rupture by contrecoup, and, still more rarely, other cases in which rupture follows a fall upon the feet from a considerable height.

The lesions are not always limited to the spleen, but in many instances include damage to adjacent viscera, especially the liver, kidney, colon, stomach, and pancreas, the diaphragm and lung, and not infrequently, in addition to the broken ribs, fracture of other long bones, or even of the pelvis and skull. Such associated lesions, when not involving an abdominal viscus, are chiefly important not only in materially increasing the gravity of prognosis, but also in the fact that, by directing attention to distant organs, they obscure the more serious injury, and thus delay, or cause to be entirely overlooked, the rupture in the spleen.

The lesions in the spleen vary greatly. In the mildest cases the capsule remaining intact, the hemorrhage is small and infiltrates the parenchyma of the organ only which, from its soft, yielding consistency, may be almost doubled or trebled in size. In the severest cases the spleen may be completely divided into two or more fragments, which, if entirely detached from the pedicle, become loose bodies in the peritoneal cavity, and may even be found in as remote a part as the right iliac fossa. Simultaneously the laceration may invade the hilus and more or less completely lacerate the vessels which enter and leave at that point. The type of laceration also varies considerably; the organ may be so generally contused as to form a pulpy mass, or the lines of laceration may be well-defined and either regular, or of stellate shape, involving generally the internal more than the external surface. If not confined within the capsule of the organ, the blood passes almost in every case directly into the greater peritoneal cavity; if, however, the rupture involves the internal surface directly behind the hilus, the blood escapes into the omental bursa of the lesser peritoneal cavity. This condition, although necessarily rare, obtained in the case of Lamarchia, in which, after a suture of a rent in the outer surface of the spleen, the patient died, and the autopsy

Digitized by Google

showed an additional rent behind the hilus, leading into the lesser cavity, which had not been discovered at the time of operation. This case is often misquoted to demonstrate the futility of suture as an effective hemostatic in rupture of the spleen. As a matter of fact, the autopsy proved that the rupture had satisfactorily checked all bleeding, and that, barring shock or other unforeseen complications, recovery would have taken place had the sutured laceration been the only source of hemorrhage. Lamarchia frankly states that had the hidden laceration been discovered, he would have removed the spleen without hesitation.

A fatal termination is to be expected in those cases where the hemorrhage continues until the patient is exsanguinated. That the hemorrhage sometimes spontaneously ceases, however, is proved by a number of cases in which the patient had died from some associated lesion, where the laceration in the spleen has been found firmly closed by thrombus, as well as by other cases, in which, at the time of operation, the hemorrhage had ceased, and recovery had followed the removal of the clotted blood from the peritoneal cavity without disturbing the site of laceration. In such favorable circumstances, in the absence of operation, the extravasated blood would either be absorbed and disappear, or if present in large quantity, it might form a sharply defined cystic tumor in the left side of the abdomen.

The symptoms of subcutaneous rupture of the spleen depend upon the extent and rapidity of the hemorrhage. In a considerable number rapid loss of blood is fatal within a very short time. In a larger number, several hours may pass before there is any evidence of internal hemorrhage. Occasionally the first indication of hemorrhage will be delayed from twenty-four to seventy-two hours, or even longer, a clinical picture that can be explained by a sudden renewal of bleeding, temporarily checked shortly after the trauma, through some inadvertent movement of the abdominal wall or diaphragm, or possibly by the fact that the hemorrhage, at first confined within the limits of an untorn capsule, eventually ruptures that barrier and escapes freely into the peritoneal cavity.

It is needless to emphasize the importance of accurate diagnosis

Digitized by Google

before exsanguination takes place in all cases that are not immediately fatal. Hence, a careful consideration of the objective symptoms seems justifiable, for valuable time is often lost through error in diagnosis, and published reports of cases seem to indicate that, not infrequently, the strength of the patient is subjected to the additional strain of needlessly long and erroneously placed incisions in an effort to recognize the source of the hemorrhage.

During the first hours after the accident, the patient, in a condition of shock, complains of severe pain in the left hypochondrium, that is intensified by attempted movement of the body and by deep inspirations. Similar symptoms are observed in fracture of the ribs, differing, however, in the fact that in rupture of the spleen the shock is more intense, while the pain is more constant, severe, and of increasing intensity. There is frequently one or more attacks of vomiting. The position of the patient is usually dorsal with marked disinclination to move to either side, especially to the right. Respiration is chiefly thoracic, the descent of the diaphragm being scarcely perceptible in the upper abdominal segment, especially on the left side. There is no asymmetrical distention or bulging of the abdomen.

There is well-defined tenderness in the region of the spleen extending from that point a variable distance downward according to the extent of the hemorrhage. Muscular rigidity is nearly always constant and pronounced. Although present over the entire abdomen, it is much more marked over the upper part of the left rectus, involving, to a lesser extent, the lower part of the same muscle. It is also very prominent in the lower part of the costal arch, and any attempt to press the unbroken eleventh and twelfth ribs toward the vertebral column is not only painful, but meets with great resistance. In cases with extensive hemorrhage, the normal area of dulness is greatly enlarged in a downward and forward direction, the left flank giving a particularly dull, if not almost flat, note. The area of dulness is said by many to shift according to the position of the patient, but under such circumstances the rapid coagulation of the blood, together with the natural restriction of adjacent omentum and loops of intestine, must frequently

Digitized by Google

retard any sudden movement of the clotted blood as a whole to another segment of the abdomen. Theoretically, as Ballance has suggested, such a change should not influence materially the position of the coagulum, but only of its expressed serum. Practically, however, the quantity of serous exudate within the first twelve hours after the accident is so small that it could have possibly no effect on the percussion note, and for that reason the not infrequent presence of shifting dulness in these cases must be ascribed to the fact that the rapidity of hemorrhage favors the accumulation of a considerable amount of fluid blood in the peritoneal cavity. The propriety of eliciting this symptom must, however, be seriously questioned. The necessary change in the position is a great hardship, and might very easily increase the severity of the hemorrhage or bring about its renewal when it had spontaneously ceased. In both cases, reported in this paper, no attempt was made to turn the patient over to the opposite side, as the diagnosis and consequent operation seemed to be justified by the other symptoms. Small amounts of blood can sometimes be detected by auscultatory percussion, the stethoscope being placed over the centre of the suspected area and relative dulness being elicited by gently tapping, with the extremity of a finger, the adjacent abdominal wall. This should always be practised at the first examination in order that any change in subsequent examinations, repeated at frequent intervals, may be immediately recognized.

Considerable information may sometimes be gained by placing the end of the stethoscope in close contact with the abdominal wall and then quickly but gently depressing it toward the abdominal cavity. The accumulated blood is thereby sufficiently disturbed to yield a rubbing friction sound that is conveyed to the examiner's ear. The end of the stethoscope should be small and connected by tubing to the ear-pieces. This physical sign, elicited by what may be called "dipping" percussion, has been practised by the writer during the past six months, and during that time has yielded a positive result in several cases of extravasation of blood into the joint and connective-tissue planes, as well as in one case of ectopic gestation. It has also been of considerable value in deter-

Digitized by Google

mining the early presence of a fibrinous exudate in inflammation of the appendix.

Of these different symptoms, the most important, and those on which chief reliance must be placed in making a correct diagnosis, are undoubtedly the muscular rigidity and the dulness or flatness in the flank. The writer wishes especially to call attention again to the value of costal resistance, or the force encountered in depressing various segments of the costal arch toward the vertebral column. This has been repeatedly tested in inflammatory processes of the liver, gall-bladder, stomach, pancreas, and kidney, and in both cases reported in this paper its well-marked development materially aided in the diagnosis. It is also essential to keep this physical sign in mind in distinguishing between damage to the costal arch or ribs only, and damage to the spleen as well. If the lower part of the costal arch is the site of fracture or of dislocation, the eleventh and twelfth ribs are not usually involved, and, inasmuch as they are not connected with the costal arch, pressure directed against them will neither intensify the existing pain nor meet with any decided resistance; the reverse, however, is found to be the case, if in addition to the damaged arch, rupture of the spleen has taken place.

The writer has also been interested in the behavior of the rectus muscle in uncomplicated cases of single or multiple fracture of the ribs from the costal cartilages of which it springs. A number of observations during the past year have shown that, if present, the rigidity is confined to the uppermost part of the muscle. An associated fracture of the femur in the second case directed the writer's attention to the possibility of abdominal rigidity in this condition, but observation of several cases of isolated fractured femur have shown that, ordinarily, abdominal rigidity is absent, or, if present, is limited to the lower abdomen.

That the presence of rigidity after trauma is not always an indication of some serious intra-abdominal lesion is well illustrated in the following case:

Male, aged thirty years, admitted to the Presbyterian Hospital April 14, 1907. This evening, while crossing the street, patient

Digitized by Google

was struck in the sacral region by an automobile and was thrown a distance of several feet, striking the lower abdomen against a lamp-post. He was brought to the hospital in an ambulance and was unable to walk or stand upright. He had considerable shock.

Examination, shortly after admission, revealed the physical signs of contusions over the lumbosacral joint and over the lower anterior abdomen, with general tenderness, with but little if any rigidity. This latter symptom soon appeared, however, and thirteen hours after the accident a personal examination showed diffuse rigidity, especially in the lower part of the abdomen, slightly more marked on the left than on the right side. A distinct swelling, evidently that of a hematoma, could be felt in the left groin above Poupart's ligament. There was no rigidity of either costal arch, and pressure on the floating ribs caused no pain. No focal symptoms could be elicited, and the patient's pulse was under 100 and his general condition was very satisfactory. Although a rupture of an abdominal viscus was considered unlikely, yet the rapid development and spread of the rigidity, together with a general increase in leukocytosis to 23,600, seemed to warrant an exploration. An extensive properitoneal extravasation of blood was found through a mid-incision below the umbilicus, and, on opening the peritoneum, retroperitoneal hematomata were detected in both iliac fossæ and loins, especially on the left side. There was no rupture of any viscus, although an ecchymotic area, the size of a twenty-five cent piece, was observed in the posterior wall of the bladder just below the fundus. The wound was completely closed without drainage and primary union secured. By the end of the first week the rigidity had entirely disappeared. It is also interesting to note that for eight days the patient had to be catheterized, the inability to void urine being either due to some functional derangement of the lumbar enlargement, or, possibly, to the contusion of the bladder wall.

Rupture of the spleen is most satisfactorily treated by splenectomy. Suture of the laceration has been attempted, but is uncertain in that the soft consistency of the organ favors the cutting

Digitized by Google

through of the sutures and prevents an approximation of the divided edges with sufficient tightness to check the hemorrhage. Moreover, the laceration may be so situated that the insertion of the sutures is either difficult or impossible. Furthermore, the suture of multiple lacerations requires much more time than the ligature of a pedicle, and the condition of the patient is such that the operation should always be concluded in the quickest possible way. Finally, as in the case of Lamarchia, a laceration from which hemorrhage may continue in sufficient quantity to prove fatal may be overlooked. The pressure of the spleen by a carefully inserted tampon against the diaphragm and costal wall has been employed, but such a tampon does not always check the hemorrhage, and its subsequent removal may dislodge the clots and lead to a renewal of that alarming symptom. Moreover, this method is totally inapplicable in cases where one or more of the splenic vessels are torn at the hilus, for the reason that the degree of pressure necessary to check the hemorrhage would unquestionably, even although it were successful, be followed by necrosis of the organ. As the use of the Pacquelin or galvanocautery does not yield desirable results, splenectomy is evidently the only satisfactory method of treatment, and the value of that procedure is amply demonstrated by numerous successful cases with a steadily decreasing mortality.

The questions involved in this operation include the situation and extent of the incision, the treatment of the pedicle, the removal of the accumulated blood from the peritoneal cavity, and the problem of drainage.

A review of the literature seems to show that the wide variance of incision is to be ascribed to the uncertainty in diagnosis, and hence to the fact that the incision at first was chiefly exploratory. In cases where the diagnosis is made, a vertical incision parallel to the upper outer border of the left rectus, above the level of the umbilicus, supplemented by a second incision extending from its upper extremity outward along the costal margin, is preferable, in that the former provides sufficient space to rapidly explore the adjacent viscera for possible rupture, while the latter permits

Digitized by Google

adequate exposure of the splenic pedicle and accurate inspection of the source of the hemorrhage.

Such an incision is also less likely to be followed by subsequent hernia. All incisions which necessitate the application of the pedicle clamp by touch are to be condemned, for the pedicle, even under normal conditions, may be attached to the fundus of the stomach or colon, and portions of those viscera would then be included within the grasp of the clamp. Through an incision parallel to the costal arch, the application of the clamp may readily be preceded by the liberation of any portion of an adherent viscus. Should its deep position or adhesion to the diaphragm or parietes render the exposure of the spleen unusually difficult, additional space may be provided by the resection of one or more of the overlying costal cartilages.

After removal of the spleen, its pedicle, if not too broad, may be transfixed and tied with catgut. In both cases here reported, the pedicle was so broad that it was feared an attempt at ligature might easily result in partial failure, and that a renewal of the hemorrhage would seriously prolong the operation and jeopardize the chances of recovery. In both cases, therefore, two clamps were left in situ and the wound closed, with the exception of a small opening in the lower part, through which the handles of the clamps protruded. Prior to the closure of the wound the accumulated blood remaining in the peritoneal cavity was rapidly washed away by a warm saline solution, the slightly elevated portion of the lower extremity permitting the rapid escape of the clotted material from the wound. The clamps thus applied acted not only as hemostats, but also as drains, and were removed at the end of two and four days, respectively. The leaving of these instruments in situ did not prove uncomfortable, and their removal was painless. The leaving of the pedicle clamps in situ after splenectomy has been practised with good results in several instances. So far as the writer can ascertain, it was first done with success by Pauchet, in 1903. It was also suggested in 1904 by Auvray as a substitute for the customary chain ligature, and in another case, reported by Fontoynont, in 1905, the splenic

Digitized by Google

pedicle, together with a portion of the tail of the pancreas, were similarly treated. The use of the clamp in this way has long been practised in vaginal hysterectomy, and similar treatment of the splenic pedicle seems justifiable, for the artery, near its termination, is practically without collateral branches, and the resulting thrombus should be as secure as that which forms after the application of the usual ligature. The fact that the clamp or clamps may become accidentally unlocked, especially during an attack of post-operative vomiting, and lead to a fatal renewal of the hemorrhage, is the only valid objection to their use; but this accident can scarcely happen if the clamps are carefully selected. That some form of drainage should be employed seems rational, if for no other reason than to provide for the possible contingency of damage to the adjacent pancreas. The tail of that organ is in close proximity to the spleen, and may simultaneously be injured by the force of the trauma. Under such circumstances, a drain for several days, or even longer, would prove desirable, especially if pancreatic fistula seemed inevitable.

Such a complication was observed in the cases of Fontoynont and Bardenhauer and Böger. In the former, a woman, aged twenty-eight years, splenectomy was done two hours after the accident. The adjacent tail of the pancreas was also torn. The clamps on the splenic pedicle were left in situ and were removed on the third day. A tampon was also introduced, a pancreatic fistula forming, which eventually closed spontaneously. In the latter case a tear in the tail of the pancreas was sutured after the spleen was removed for rupture. Recovery.

A successful case of splenectomy for rupture is also reported by Morison, in which there was damage to the tail of the pancreas. This case was drained through a stab puncture in the left loin, the abdominal wound being closed completely. Primary union was secured, but there is no mention of a subsequent pancreatic fistula through the counteropening.

The only possible objection to splenectomy for rupture of the spleen consists in the fact that, in the absence of accessory spleens, which, by their hypertrophy, could easily and satisfactorily con-

Digitized by Google

tinue the splenic functions, it necessitates the sacrifice of an organ which, unquestionably, is important to the body economy. That its preservation is not essential, however, to a condition of perfect health is, of course, proved by the numerous cases of complete recovery after its removal. That, on the other hand, some temporary constitutional disturbance may follow splenectomy is clearly shown by the cases in which a long persistent anemia, with general emaciation, has been observed, as well as occasional instances of delay in the repair of associated lesions, particularly in the long bones. Thus in Nötzel's case, there was no evidence of callus formation in a fracture of the shaft of the humerus three months after the accident, and an operation, done at that time, for non-union, proved a total failure. Six months later union was secured by a second operation of an osteoplastic character. In the first case, reported by the writer, a simple fracture of the shaft of the femur united with no special delay, although with rather more shortening than usual.

The following instances may be cited in illustration of the disturbance of the body economy that sometimes follows splenectomy.

Ballance reports a case of a female, aged forty-five years, who made good progress during the first week after a splenectomy. Then the pulse became 120 to 130; the temperature 100° to 101°. There was threatened anorexia, pain in the limbs, especially along the tibia, and little urine. The patient showed a tendency to sleep all day. She fainted on changing her position in bed. The patient was fed on grilled spleen and on extract of spleen, with ultimate recovery.

The same observer also reports a second case, in a man aged thirty-six years. Two weeks after the operation this patient became cachectic, with loss of flesh and sunken face. There was weakness and thirst and the patient continued to lose ground for four weeks. He was given cod-liver oil and marrow on toast, but finally improved, and ultimately recovered on the use of arsenic. At the end of four months slight enlargement of the lymphatic glands could be detected.

Digitized by Google

Von Beck reports a case of slow recovery from an acute anemia following splenectomy, without any appreciable enlargement of the lymphatic glands or thyroid.

Heaton reports a case in a boy in whom anemia persisted for six months after operation.

Lewerenz reports a case of a man, aged twenty-seven years, in whom some psychical disturbance, with hallucinations, persisted for two months after operation.

That nature endeavors to provide a substitute for the loss of the splenic reparative power, if it may be so called, is shown in a considerable number of cases by a moderate hypertrophy of the lymphatic glands or of the thyroid, or of the marrow of the bones, the last mentioned indicated by a general soreness along the shafts of the long bones. Such an enlargement, which must be regarded as compensatory, probably follows all cases of splenectomy, although it may not be sufficiently pronounced to be demonstrated by palpation. The questions naturally arise whether complete restoration of the body economy depends upon the satisfactory adjustment of such compensation, and whether such a state of compensation can be disturbed or overthrown by the advent of any sudden infection or other grave illness. Unfortunately, the evidence relating to the latter question is very scant. It has been shown experimentally that the removal of the spleen in animals seems to increase their powers of resistance to various infections, but Hörz rightly states that, from that fact, no trustworthy analogy can be applied to the human race. Racovicco reports a case of typhoid fever which ran a mild course, in an epidemic of unusual severity, in a splenectomized female, aged nineteen years, and a few scattered cases of prompt uneventful recovery after operation for a subsequent ventral hernia, and in one case, that of Roeser, for acute ileus, due to a band formation, five years after splenectomy, are also mentioned. On the other hand the patient operated on by Roeser, after a persistent anemia, developed a pneumonia of the lower left lobe six months after the splenectomy. At the end of four weeks the patient convalesced slowly, and although prior to the pneumonia the blood count had been normal, yet after it had

Digitized by Google

run its course there was a considerable increase of the lymphocytes, especially of the larger varieties, though slowly decreasing, yet which persisted for many months after recovery had taken place. Nötzel's sixth case of splenectomy for a bullet wound of the thorax and abdomen is interesting in that in the absence of a peritonitis an empyema developed, and although drained by the excision of a rib, yet persisted to discharge under general pyemic symptoms masses of lung tissue, until it was thought that the major portion of the lower left lobe had come away. The recovery of the patient under such circumstances would indicate unusual reparative power, while, at the same time, the extensive sloughing of the lung would not probably have taken place had the damage been limited to the thoracic cavity.

The necessarily small amount of clinical evidence dealing with this subject certainly justifies the following interesting report of the sequel in the second case. The clinical histories of the two cases are first given.

J. B., aged twenty-eight years, male. Admitted to the Presbyterian Hospital May 28, 1906. There is an indistinct history of malaria. While falling a distance of five stories down an elevator shaft this morning the patient struck the left side against a bar. When brought to the hospital, shortly afterward in the ambulance, the patient complained of thirst, shortness of breath, and of pain in the left side and lower part of the chest.

Examination revealed a fracture of the ninth rib in the mid-axillary line, with cutaneous emphysema over the left side of the chest. The abdomen was full, but not distended, moving more on the right side in respiration. There was marked rigidity of the left flank and of the lower left costal arch. In the left flank there was dulness merging with the normal area of splenic dulness above. Elsewhere, the percussion note was normal. Pressure over the splenic area elicited marked tenderness.

There was also a fracture of the left femur and an extensive scalp wound. Pulse slightly over 100, and of increasing frequency. Temperature, 101°.

Splenectomy five hours after the accident.

Digitized by Google

Gas and Ether. A vertical incision along the upper outer border of the left rectus, above the level of the umbilicus, extending from its outer extremity downward and outward along and parallel to the costal margin, a distance of four inches. A considerable amount of semiclotted blood was found in the peritoneal cavity and rapidly wiped away, disclosing the spleen with a deep rupture two and a half inches long in its phrenic surface. The spleen was double its normal size, and at its pedicle was closely adherent to the fundus of the stomach. It was also moderately adherent to the diaphragm. The rent was still bleeding freely, but immediately ceased when the pedicle was compressed. After temporary control of the bleeding, the spleen was separated from the diaphragm above and from the fundus of the stomach below, and its pedicle clamped with two large strong forceps. The remaining clotted blood was then removed with saline irrigation and the wound closed, leaving an aperture at its lower extremity for the handles of the clamps. The operation required fifteen minutes, and toward the latter end the patient's pulse became feeble and rapid, responding, however, to an infusion of 1000 c.c. of saline solution.

During the first twenty-four hours there was considerable discharge from the wound, and the patient's general condition was such as to require a moderate amount of stimulation. The pulse, never higher than 140, decreased to 88 on the third day. The clamps were removed without pain on the second and third days, respectively, and without any sign of a renewal of the hemorrhage. Three weeks after there was a rise of temperature to 103°, and 30 ounces of clear fluid was withdrawn from the left chest. Thereafter the convalescence was uninterrupted and complete. At no time was there any indication of enlarged glands or of an enlarged thyroid, or any pain along the shafts of the long bones. The fracture of the femur united slowly, but satisfactorily, and the patient today is attending regularly to his work as a guard on the elevated railroad.

Laboratory Reports. The spleen was normal outside of the rupture, which penetrated into the hilus.

Digitized by Google

For a few days after the operation the urine showed a faint trace of albumin and casts.

The fluid from the chest was alkaline, of a specific gravity of 1015, and contained a large amount of albumin. It contained no growth of any kind.

The following blood counts were made: Number counted in each 300:

		June			
	On admission.	1.	4.	6.	8.
Polymorphonuclear	92.5	84.0	76.0	..	88.0
Transitional	2.5	2.6	5.5	..	5.0
Large mononuclear	..	..	4.0	..	3.0
Lymphocytes	4.0	13.0	12.5	..	4.0
Basophiles	..	..	..	..	..
Eosinophiles	..	1.0	2.0	..	..
Blood plates	Inc.	..	Inc.	..	Inc.
Leukocytes	54,000	24,000	23,100	..	30,000

	June				
	11.	13.	15.	20.	30.
Polymorphonuclear	64.5	66.0	75.0	55.0	69.0
Transitional	7.0	12.0	7.5	15.0	5.5
Large mononuclear	0.5	1.5	..	4.5	1.0
Lymphocytes	26.5	15.5	16.5	20.0	24.0
Basophiles	..	0.5	0.5	..	..
Eosinophiles	..	1.0	1.5	5.5	..
Blood plates	Much Inc.	Great Inc.	..	Inc.	Inc.
Leukocytes	20,000	..	17,000	..	15,300

One year afterward: White blood cells, 17,000; red cells, 5,800,000; polymorphonuclear, 52.5; transitional, 4.5; large mononuclear, 13.5; lymphocytes, 28.5; basophiles, 0.5; eosinophiles, 0.5.

There was considerable pallor of the red cell with moderate polychrom. There was 95 per cent. hemoglobin.

CASE II.—L. S., female, aged thirty-four years (May 14, 1906). Eight years ago patient was curetted for retained secundines. Four years ago she was operated on for ruptured ectopic gestation, in a condition of almost complete exsanguination. Since then she has been in excellent health.

This morning, at 10 o'clock, patient fell a distance of nine feet, striking the region of the lower ribs against the edge of an ash-can. She was unable to rise and there was severe pain in the left side,

Digitized by Google

intensified by movement and by deep respiration. To lie on her left side was impossible, and lying on her back was also painful. There has been no vomiting. The pain seemed to diminish for a time and then returned with increasing severity, and the patient began to feel weak and thirsty. Brought to the hospital in an ambulance.

Five hours after the accident the pulse was regular, 132, and of low tension. The respiration was shallow and increased in frequency. There was a fracture of the eighth and ninth ribs near the axillary line.

Examination of the abdomen showed a diminished respiratory movement on the left side. Rigidity present throughout the entire left side was most marked in the ileocostal space and over the left lower costal arch. Moderate pressure over the splenic area was very painful. In the left flank there was a dulness, merging with the area of normal splenic dulness above. Elsewhere the percussion note was unchanged.

The patient was acutely anemic and presented the usual appearance of a patient suffering from internal hemorrhage.

Splenectomy six hours after the accident.

Gas and Ether. A vertical incision was made along the upper outer border of the left rectus, above the level of the umbilicus, extending from its upper extremity downward and outward along the costal margin a distance of four inches. A considerable amount of clotted and fluid blood was found in the peritoneal cavity and rapidly evacuated, disclosing the spleen with a deep rupture two and one-quarter inches long on its internal surface, in front of the hilus, and on its outer surface, denuded of its peritoneal coat, an irregularly circular orifice three-quarters of an inch in diameter, communicating with the larger rent internally. The spleen was double the normal size and was still bleeding. The pedicle was clamped with two strong forceps and the spleen removed. The remaining clotted blood was then quickly washed away with saline irrigation, and, after the insertion of a cigarette drain to the pedicle, the wound was closed, leaving an aperture at its lower extremity for the handles of the clamps. The duration

Digitized by Google

of the operation was twenty-one minutes, and at its end, the pulse being 140 and weak, an infusion of 1200 c.c. of saline solution was given.

During the following night the pulse was at times almost imperceptible, and there were several attacks of vomiting, but the patient responded well to stimulation, and at the end of twenty-four hours was in a very satisfactory condition. The clamps were removed at the end of forty-eight and seventy-two hours, respectively. The healing of the wound was satisfactory, although there was a gradual rise of temperature to 103° on the fourth day and a continuation of a temperature averaging 102° until the fourteenth day, when it fell to normal. On the nineteenth day there was a sudden rise of temperature to 103°, with the physical signs of fluid in the left chest. At the end of ten days the temperature was again normal and the signs of fluid had entirely disappeared. The patient was discharged in excellent condition at the end of the forty-fifth day.

The following abstracts of successive blood counts are added:

	On admission.	Days. 2d.	4th.	6th.	8th.	10th.
Polymorphonuclear	94.5%	80%	77%	..	75%	80%
Leukocytes	296,000	68,000	28,000	36,900	39,400	32,900
Lymphocytes	5%	5%	8%	14%	..	17.5%

	Days. 12th.	14th.	16th.	18th.	20th.	22d.
Polymorphonuclear	..	67%	67%	66%	64%	..
Leukocytes	22,600	17,700	23,900	14,300	13,700	10,000
Lymphocytes	..	..	24%	25%	19%	..

	Days. 24th.	26th.	29th.	35th.	38th.	41st.
Polymorphonuclear	52%	53%	44%	61%	..	42%
Leukocytes	15,000	13,000	10,000	12,000	14,400	13,300
Lymphocytes	22%	25%	40%	18%	..	40%

Hemoglobin, 80%.
Red cells, 3,260,000.

Since her discharge from the hospital the patient has had several attacks of "indigestion," with pain of moderate or slight severity in the gall-bladder region. About forty-eight hours before admission, and ten and a half months after splenectomy,

Digitized by Google

she was seized with sharp, severe pain in the same region, which radiated to the back, although not to the shoulder, and was intensified by movement from one side to the other in bed and by respiration. There was constant nausea, but only one attack of vomiting on the afternoon of the day of admission, the vomiting consisting of the gastric contents. The bowels had moved each day. The prostration was marked, and, at the time of admission, the pulse was 110, the temperature 102°, and respiration 44. The patient looked acutely sick, and the pain, which had continued from the onset, was then very intense and prohibitive of any movement in bed.

On examination, the patient was in the dorsal position with the thighs flexed on the abdomen. The right side of the abdomen was held rigid and motionless and was exquisitely painful to the touch. There was intense rigidity of the upper part of the right rectus, and, to a lesser extent, of its lower portion as well. There was well-marked resistance of the upper part of the right costal arch, and pressure over the arch above the situation of the gall-bladder caused pain. The extreme tenderness prevented satisfactory percussion. Under a general anesthetic, the gall-bladder could be distinctly felt projecting below the border of the liver to a point opposite the level of the umbilicus, and forming an oval, smooth, and deeply elastic tumor.

Gas and Ether. Through a vertical incision parallel to the upper outer border of the right rectus muscle the peritoneal cavity was opened and the gall-bladder exposed, with the transverse colon and omentum moderately adherent. There was a small amount of clear serous fluid in the peritoneal cavity. The gall-bladder was double the normal size and its wall stretched and elastic. It was rapidly and easily separated from the liver above, and, after ligation of the edge of the gastrohepatic omentum and cystic duct with chromic gut, was cut away without its cavity being opened. The wound was closed in layers with chromic gut, a cigarette drain being inserted to the stump of the ligated duct. The patient was on the table less than forty-five minutes.

Digitized by Google

On opening the gall-bladder its cavity contained a considerable amount of turbid serous fluid; its walls were found to be thickened, and near the orifice leading into the cystic duct were two large calculi.

POSTOPERATIVE COURSE. First day after operation, recovery from the anesthetic took place without event. There was no nausea or vomiting and very little restlessness. During the day the patient was quiet, complaining at times of pain in the wound from which there was no biliary discharge. The quantity of urine passed was 24 ounces. There was a trace of albumin, but no casts.

Second Day. Patient's condition was satisfactory throughout the day. She vomited once 6 ounces of greenish fluid and was at times restless and complained of pain. The wound was dressed and the drain loosened a trifle. Toward evening she appeared drowsy and the pulse was a little more rapid. The total amount of urine passed was 39 ounces.

Third Day. The drowsy condition increased, deepened rapidly into coma, from which she could not be aroused. The patient lay flat on her face, unconscious, and did not even groan. The eyelids were closed. The pupils, equal, markedly dilated, reacted to light. Respirations were labored and rapid, and had both an inspiratory and respiratory effort. The prostration increased and seemed very marked. The temperature rose steadily throughout the day, and by evening had reached 103°. The pulse was also very rapid, varying between 130 and 148, but was of fair quality and of moderate excursion. The general leukocytosis was 55,000, with a polymorphonuclear of 90 per cent. Examination of the lungs showed a number of rales over the left base and a good many over the right base, but without noticeable change in the respiratory murmur. Abdominal distention gradually appeared, and during the day a profuse biliary fistula, discharging a large amount of yellow-brown material, was formed. There was no rigidity of the abdominal muscles or any sign of fluid in the peritoneal cavity. The urine was 1027; acid; good trace of albumin; no sugar. Microscopically, there were urates and many hyaline casts. Urea amounted to 3.3 per cent. There was no diacetic acid. There was a very faint reaction for acetone.

Digitized by Google

Throughout the day the patient received active stimulation of strychnine, digitalis, and whisky in clyses and saline enemata. For the distention, stupes and hypodermics of physostigmine salicylate were employed. At noon, hypodermic injections of adrenalin and thyroid extract were begun, the adrenalin in doses of 2-minim doses every hour for four hours, and afterward included in a clysis containing 3 drams of whisky and 1000 c.c. of saline solution with 15 minims of adrenalin once in four hours. Early in the afternoon feeding by spleen tissue was also begun in the form of 5-grain suppositories every six hours, and of enemata of spleen broth containing 5 ounces, twice a day.

Fourth Day. The condition of the patient grew steadily worse, and toward midnight was most alarming. At that time the pulse could scarcely be felt, and was counted at 150. Respiration was 36, and shallow. The temperature was 104°. The patient's condition seemed most extreme and she appeared moribund. In an effort to check what appeared to be a form of toxin absorption, lavage was given, followed by a cathartic with colon irrigation. At half-past two in the morning the patient appeared for the first time to be holding her own, and soon after began to show a continued but manifest improvement, in that the pulse became slower and stronger and the saline enemata brought away each time quantities of foul fecal material, with a considerable amount of flatus. The temperature also gradually fell to 102°. The coma continued without change and the pupils were still dilated. The condition of the abdomen showed no sign of peritonitis.

Fifth Day. Toward noon today the coma decreased and the patient seemed to be slightly conscious of her environment. Following a clysis, the patient had a chill with a rise of temperature to 105°, but by night the temperature had again fallen to 103°. Late in the afternoon the patient began to moan and could be aroused by effort. Although always in a very stupid condition, yet on several occasions she asked for water. Her entire condition showed great improvement, and during the day she was given 48 ounces of fluid nourishment. During the morning the right pupil was slightly larger than the left, but later on both were equal and contracted. This afternoon the pulse was as low as 90.

Digitized by Google

Sixth Day. Patient talked at intervals during the day, and said that she remembered nothing of what had transpired since the operation. Her mind was quite clear, and she took increasing quantities of fluid nourishment. Patient looked much stronger, the temperature was as low as 100°, and the pulse in the 80's. The abdominal condition was unchanged. There are still many crepitant rales over the left base as well as over the right base, although less abundant. On this day, although the biliary fistula was discharging freely, the conjunctivæ and skin became slightly icteric and the urine showed the presence of bile. Several cultures of the blood failed to disclose any organism.

Subsequent Course. The patient continued to steadily gain ground. The jaundice, at first somewhat deepened, had by the end of a week entirely disappeared. The temperature remained, however, irregularly and persistently high, varying between 99° in the morning and 103° at night. During this time the pulse varied between 94 and 115, being usually slightly over 100. On the twenty-sixth day signs of a small amount of fluid were detected by Dr. James over the right base and about 1 dram of slightly purulent fluid was withdrawn by the needle. On the following day the temperature rose to 103° and the pulse to 140, and immediate thoracotomy was performed under cocaine, evacuating a very small amount of pus. After the operation the patient was restless and somewhat neurasthenic, but never at any time showed any distinct manifestation of hysteria. The discharge from the opened pleural cavity was always small, and, after the removal of the tube, rapidly healed to a small sinus with excellent expansion of the lung. For more than two weeks the patient ran an irregularly high temperature, but since that time the temperature gradually fell to normal, where it has remained for more than a week. The patient is now up and dressed, feeling strong, and gaining steadily in weight. She is still taking spleen broth, and three suppositories are taken daily.

Laboratory Notes. 1. The culture taken from the fluid in the abdominal cavity at the time of the first operation showed no culture.

Digitized by Google

2. The gall-bladder presented somewhat thickened walls and had a deeply congested mucous membrane. The mucosa was somewhat eroded, and on microscopic examination showed chronic suppurative inflammation.

3. The blood culture and the culture from the gall-bladder were negative.

4. The culture from the fluid in the right chest showed rather thick bacilli, which gave all the reactions of the Bacillus coli communis.

The following differential counts were made on admission, 350 cells being taken in the first four, and 200 cells in the later counts:

	Days.					
	coma 1st.	coma 2d.	coma 3d.	4th.	5th.	6th.
Leukocytes	36,200 per ct.	35,000 per ct.	19,800 per ct.	19,800 per ct.	31,000 per ct.	36,000 per ct.
Polymorphonuclear	90 4	89.6	..	78.8	73.0	70.0
Transitional	6.8	6.4	..	6.0	6.5	7.5
Large mononuclear	2.4	2.8	..	4.4	10.0	2.5
Lymphocytes	0.4	1.2	..	8.8	8.5	9.5
Basophiles	..	..	..	..	..	..
Eosinophiles	..	..	..	2.0	3.0	..
Blood plates	Inc.	Inc.	..	Inc.	Inc.	Inc.
Pallor	Consid.	Consid.	..	Consid.	Inc.	Inc.
Polychromatophilic	Mod.	Mod.	..	Mod.	Mod.	Mod.
Poikilocytes	Mod.	Mod.	..	Mod.	Mod.	Mod.
Basophiles, granular	..	..	..	..	..	..
Normoblasts	..	1.0	..	..	..	..
Megaloblasts	..	..	..	..	.	..
Stimulating forms	..	..	..	3.0	..	..
Myelocytes	1.0	1.0	..	..	5.0	3.0

	Days.					
	7th.	8th.	9th.	10th.	13th.	16th.
Leukocytes	37,000 per ct.	27,400 per ct.	34,000 per ct.	28,800 per ct.	30,000 per ct.	29,600 per ct.
Polymorphonuclear	72.5	72.5	2.5	73.0	75.5	73.0
Transitional	7.0	6.0	9.0	8.5	6.5	6.0
Large mononuclear	10.0	12.5	1.0	12.5	8.5	13.0
Lymphocytes	9.0	11.0	7.0	6.5	9.0	8.5
Basophiles	..	..	..	..	..	..
Eosinophiles	1.0	0.5	0.5	0.5	..	0.5
Blood plates	Inc.	Inc.	Inc.	Inc.	Inc.	Inc.
Pallor	Inc.	Inc.	Consid.	Inc.	Inc.	Inc.
Polychromatophilic	Mod.	Mod.	Mod.	Mod.	Mod.	Mod.
Poikilocytes	Mod.	Mod.	Mod.	Mod.	Mod.	Mod.
Basophiles, granular	..	..	..	..	..	Mod.
Normoblasts	1.0	..	..	..	..	..
Megaloblasts	..	..	..	..	..	..
Stimulating forms	2.0	..	..	..	..	..
Myelocytes	1.0	1.0	..	..	..	..

Digitized by Google

Date and hour.	Medication, etc.	Number stools.	Urine ʒ	Notes on results of medication and the condition of patient.		
March 7, 1.15 A.M.	Magendie ♏ iij, hypo. stat.	0	24	Admitted from op. pav. at 1 a.m.	1	
3.15 A.M.	Repeat with atropine gr. 1/150 s. o s.	...	...	Into op. pav. 12.05 a.m.		
not necessary	Magendie ♏ iij, hypo. s. o. s.	...	...	Out op. pav. 1 a.m.		
11 45 A.M.	Magendie ♏ iij, hypo. s. o. s.	...	...	Condition good. P. 100, R. 28.		
9.00 P.M.	Magendie ♏ iij, hypo. s. o. s.	...	...	Drains i cigarette. Anti op. spec. to lab Quiet most of the time. Slept well. No nausea or vomiting. Complained of abdominal pain during day.		
March 8,	Strychnine gr. 1/30, hypo. t. i. d.	0	39	Very restless entire night Spec. to lab. Vomited ʒ vi greenish fluid. Dressed by H. S Wound irrigated—drain shortened.	2	1
March 9, 2.30 A.M.	Magendie ♏ iij. hypo. s. o. s.	...	...	Pulse rapid and of poor quality at 7 a.m.	3	2
7.40 A.M.	Whisky bbl. i, hypo. stat.	...	...	Responded somewhat to medicine for short time.		
7.45 A.M.	Saline ʒ vi, whisky ʒ i, p. r. q. 4 h., make strychnine q. 4. h., tr. digitalis ♏ x, hypo. q 4 h., alternating with strychnine. Med. shock blocks to feet.	...	...	Stupes given with very good result. Considerable yellowish-brown oozing from wound. Comatose condition all day. Responded sightly to clysis and medication. Abdomen soft—considerable flatus expelled p. stupes during p.m.		
8.30 A.M.	Turpentine stupes q. 2 h. Stop digitalis.	...	...	Stimulating enemata retained.		
11.45 A.M.	Sol. thyroid (♏ x = gr. ¾ ext.) ♏ v, hypo. stat. q. 4 h.	...	17	Per. cath. at 2.10 p.m , ʒ xvij obtained.		
12.00 NOON	Clysis 600 c.c. with adrenalin ♏ xv whisky ʒ iij, stat. q. 4 h.	...	...	Irrigations returned discolored, containing considerable fecal matter of foul odor. Lavage given by Dr. Draper. Dressing reinforced several times during day. No nourishment taken.		
11.55 A.M.	Adrenalin ♏ ij, hypo. q. 1 h., ad. 4. Suppos. of spleen tissue q. 6 h. (gr. v.)	...	8	Per. cath. at 10 p.m., ʒ viij obtained. Clysis at m.n. given by Dr. Jameson.		
2.10 P.M. } 10.00 P.M. }	Catheterize q. 12 h., s. o. s.	...	...	Distention less.		
10 00 P.M.	Colon irrigation of saline at 105° for 15 min. q. 3 h.					
11.00 P.M.	Prepare for lavage stat. follow by mag. sulph. ʒ ss.					
10 30 P.M.	Physostig. salicy. gr. 1/60, hypo. stat. and p. 2 h. Stop enemata.	0	25			
March 10, 8.45 P.M.	Stop adrenalin with clysis. Lavage stat. follow by R. cath. co. no. ij. Spleen broth ʒ v p. r.	v	20	Colon irrigations returned discolored brown with few particles of fecal matter. Dressed by H. S. (Dressing changed.) Abdomen soft. Clysis well taken.	4	3

Digitized by Google

March 10, 10.30 A.M. / 10.30 P.M.	Catheterize q. 12 h. s. o. s.		19 / — / 39	Per cath. at 10.30 a.m. ʒ xx. 10.30 p.m. ʒ xix obt. Clysis at 10.30 a.m. given by H. S Colon irrigations at night acted as enema—large amt. flatus expelled and considerable fecal matter. Spleen broth ʒ v p.r.		
March 11	Make irrigations q. 4 h. Make stupes q. 2 h. s. o. s. Make strychnine gr. 1/160 q. 6 h. Make thyroid q. 6 h. Make clysis q. 6 h. Spleen broth B. D. Spec. to lab. O. D. Exam. for bile acetone and diacetic acetone. Stop shock blocks.	Irrigation.	36	Tongue dry and coated. Spec. to lab. Irrigations returned fairly clear. Pt's condition seems much better. Conscious. Abdomen soft—no distention. Chill at 10.30 a.m. for 10 min., T. 104⁸, P. 112, R. 32. Fluids well taken. Irrigations at night returned clear with quantities of flatus. Complained of pain in region of wound. Dressing reinforced. Fluids ʒ 48.	5	4
March 12	Stop clysis. Make thyroid gr. v., t. i d. p. o. Make strychnine p. o. Make spleen suppos q. 8 h. Make irrigations q. 6 h. Full fluids.	Irrigation.	40	Pt. talking. Nourishment well taken. Dressed by H. S. Drain removed i cig. dr. inserted. Pt. complained of pain in arms and in region of wound at intervals during day. Irrigations returned with particles of fecal matter. Fluids ʒ 118.	6 7	5 6
March 13, 12.20 P.M.	Stop catheterization. Prepare for blood culture.	1	34	Slept most of night. 24 hr. spec. to lab. Coughs occasionally with small amount of expectoration. Blood culture by Dr. Draper. Spec. sent to lab. Irrigations returned cloudy with fecal matter. Spleen broth expelled. Fluids ʒ 106.		
March 14	Soft diet.	ij	45	Slept greater part of night. Spec. to lab. Dressed by H. S. Drain removed—irrig. of saline and peroxide, i cig. dr. inserted. Very comfortable day. Appetite good. Irrigations returned cloudy with considerable fecal matter.	8	7
March 15	....	iv	20	Slept well. Spec. to lab. Irrigations returned with considerable fecal matter.	9	8
March 16	Stop strychnine. Stop stupes Make irrigations q. 8 h. Heroine gr. 1/20 q. 4 h. Prog. diet.	ij	34	Coughs occasionally. Spec. to lab. Irrigations returned cloudy with fecal matter Very comfortable day. Dressing changed by nurse.	10	9
March 17	Codeia cough ʒ q. 4 h. alt. with heroine.	ij	20	Irrigations returned cloudy with very light yellow fecal matter. Dressed by H. S Sutures removed—irrig. of saline and peroxide. Wound strapped with sterile adhesive.	11	10
March 18	Make irrigation for 20 min. B. D.	ij	24	Colon irrigations returned clear.	12	11
March 19	Spec. to lab. q. 2 d.	ij	38	Colon irrigations returned clear. Dressed by H. S. Spec. to lab.	13	12
March 20	....	1	39	Slept well. Irrigations cloudy with fecal matter.	14	13

Digitized by Google

Date and hour.	Medication, etc.	Number stools.	Urine ʒ	Notes and results on medication and the condition of patient.		
March 21	....	i	24 +	Irrigations cloudy with fecal matter. Spec. to lab. Dressed by H. S. Profuse discharge.	15	14
March 22	Stop irrigations. Stop codeia cough. Diabetic diet. Make thyroid B. D. Hexaform gr. v B. D.	ii	24	Slept all night. Comfortable day.	16	15
March 23	....	i	34	Spec. to lab.	17	16
March 24	Stop heroine. Allow low back rest.	i	26		18	17
March 25	....	ii	16	Up in bed, slight fatigue. Spec. to lab.	19	18
March 26	R. Blaud gr. v t. i. d. p. c. Stop thyroid. Stop hexaform.	iij	28	Dressed by nurse.	20	19
March 27	Allow up in chair.	i	22	Up in chair in p.m. Slight fatigue.	21	20
March 28	....	i	20	Dressed by nurse. Spec. to lab. Up in chair 2 hrs.	22	21
March 29	....	i	24 +	Comfortable day.	23	22
March 30	....	i	20 +	Dressed by nurse.	24	23
March 31	....	i	27 +	Dressed by H. S.	25	24
April 1	....	ii	18 +	Dressed by Dr. Jameson.	26	25
April 2	....	iij	24	Pt. post chest explored by H. S., about ʒ i of pus obtained. Spec. sent to lab. Dressed by Dr. Jameson. Profuse discharge.	27	26
April 3, 12.25 A.M.	U. S. sol. ʒ i stat.	0	27	Pt m.n. complained of pain at site of exploration. Quieted by med. and slept Very uncomfortable this a.m.	28	27
not necessary . .	Repeat p. 1 h. s. o. s. Tonic No. 13 ʒ i t. i. d. p. c.	...	...	Dressed by Dr. Jameson. Prepared for op. locally.		
in op. pav.	Prepare for op. stat. Whisky, ʒ ss, Magendie ♏ iij, hypo.	...	...	Into op. pav. 5.54 p.m. Out op. pav. 6.03 p.m. P. 136, R. 56. Drains, 1 rubber tube.		
8.30 P.M.	Magendie ♏, iij hypo. s. o. s.	...	...	Complained of pain in wound in early p.m. Slept p. medication.		
April 4, 11.35 A.M.	Codeia cough ʒ i, stat. Codeia cough ʒ i, q. 4 h. Spleen broth ʒ v, B. D. Spleen tissue suppos. q. 8 h.	0	16	Breathing somewhat labored. Spec. to lab. Mod. amt. light-red discharge from wound Dressing reinforced twice during night. Complains of pain in back. Coughed frequently p. 11 a.m.	29	28 1
5.00 P.M.	Heroine gr. 1/12, stat.	...	...	Wound dressed and explored by H. S.		
not necessary . . .	Repeat p ½ h. s. o. s.					
April 5, 10.15 A.M.	Pil, cath. co., no. i, stat.	...	...	Very comfortable this a.m.		
2.30 P.M.	Liq. mag. cit. ʒ vi, p.m. s. o. s.	...	...	Coughs less frequently.		
5.30 P.M.	Enema p. 3 h. s. o. s. Soft diet. Allow back rest.	...	...	Abd. wd. dressed by Dr. Jameson. Irrigated i q. 3 dr. inserted. Dark-brown fluid result from enema. Considerable oozing from post chest wd.	30	29 2

Digitized by Google

Date.	Specific gravity.	Reaction.	Color.	Turbidity.	Precipitate.	Albumin.	Glucose.	Microscopic examination.
March 6 (A. O.)	1032	Acid.	Amber.	Clear.	Flocc.			
March 7 P. O.	1030	Acid.	Amber.	Turbid	Gran.	Trace.	0	White blood corpuscles and epithelium present in good number.
March 9 (Cath.)	1027	Acid.	Reddish.	"	Flocc.	Weaker trace.	0	Urates, many hyaline casts; urea 3.2%, no diacetic, acetone.
March 12 "	1026	Acid.	Amber.	"	Gran.	Trace.	0	Urates, few hyaline casts and white blood corpuscles; no diacetic; no acetone.
March 14	1016	Acid.	Amber.	"	Gran.	Trace.	0	Little pus. Bile present.
March 16	..	..	..	..	..	..	..	No pus. Bile present.
March 18	..	..	..	..	..	..	..	Bile present.
March 19	..	..	..	..	..	..	..	Bile present.
March 20	..	..	..	..	..	..	..	No bile.
April 4	..	..	..	..	..	..	..	No bile.

Digitized by Google

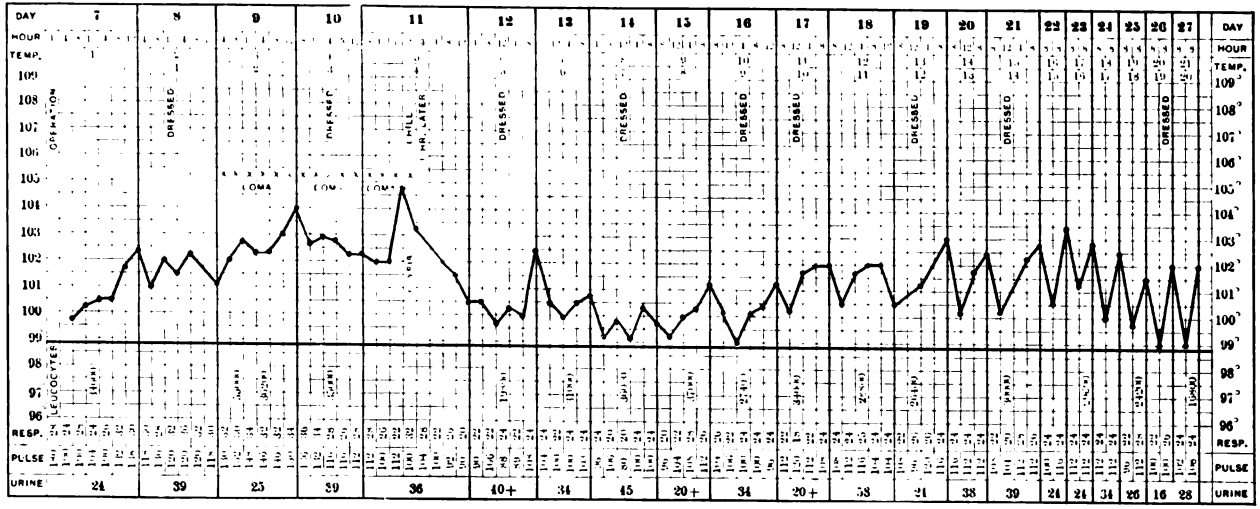

Laboratory Reports.

	Mar. 9.	Mar. 10.	Mar. 12.	Mar. 13.	Mar. 14.	Mar. 15.	Mar. 16.	Mar. 17.	Mar. 18.	Mar. 21.	Mar. 23.	Mar. 25.	Mar. 27
	%	%	%	%	%	%	%	%	%	%	%	%	%
Polymorphonuclear	90.4	89.6	78.8	73.0	70.0	73.0	70.0	72.5	72.5	75.5	72.0	67.5	65.0
Transitional	6.8	6.4	6.0	6.5	7.5	7.0	6.0	9.0	8.5	6.5	6.0	7.0	6.0
Large mononuclear	2.4	2.8	4.4	10.0	2.5	10.0	12.5	11.0	12 5	8 5	13.0	16.0	15.5
Lymphocytes	0.4	1.2	8.8	8.5	9.5	9 0	11.0	7.0	6.5	9.0	8.5	9 0	11.0
Basophiles	0.0	0.0	0.0	0 0	0 0	0.0	0.0	0.0	0.0	0.5	0.0	0.5	0.5
Eosinophiles	0 0	0.0	2.0	2 0	0.0	1.0	0.5	0.5	0 5	0.0	0.5	0 0	2.0
Blood plates	Inc.	Inc.	Inc.	Inc.	Inc.	Inc.	Inc.	Inc.	Inc.	Inc.	Inc.	Inc.	Inc.
Red blood corpuscles:													
Pallor	Consid.	Consid.	Consid.	Consid.	Consid.	Consid.	Consid.	Consid.	Consid.	Consid.	Consid.	Consid.	Consid.
Polychromatophilic	Mod.	Mod.	Mod.	Mod.	Mod.	Mod.	Mod.	Mod.	Mod.	Mod.	Mod.	Mod.	Consid.
Poikilocytes	Mod.	Mod.	Mod.	Mod.	Mod.	Mod.	Mod.	Mod.	Mod.	Mod.	Mod.	Mod.	Consid.
Basophiles, granular	0.0	0.0	0.0	0 0	0 0	0 0	0.0	0 0	0.0	0 0	Mod.	Consid.	Mod.
Normoblasts	0 0	1.0	0.0	0.0	0 0	1.0	0.0	0.0	0.0	0.0	0 0	1.0	0.0
Megaloblasts	0.0	0.0	0.0	0.0	0 0	0 0	0.0	0 0	0.0	0 0	0 0	0.0	0.0
Stimulating forms	0.0	0.0	2.0	0.0	4 0	2.0	0.0	3 0	0.0	0 0	1.0	1.0	0.0
Myelocytes	1.0	1.0	0.0	5.0	3.0	1.0	1 0	1.0	2 0	2.0	0.0	0.0	1.0

Differential counts: First four counts, 250 cells; later counts, 200 cells.

Digitized by Google

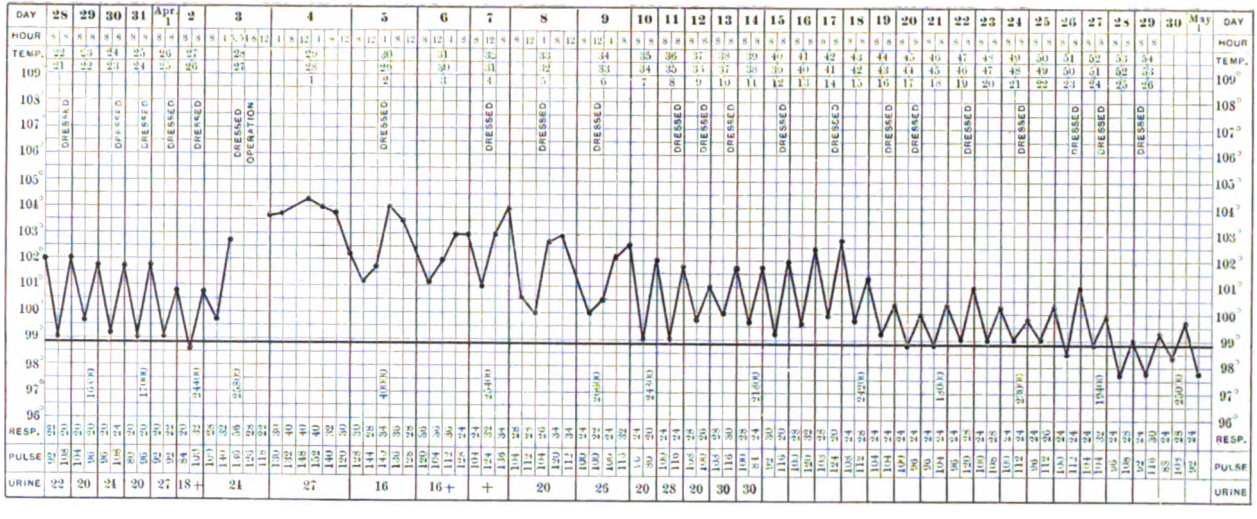

Laboratory Reports.

	Mar. 29.	Mar. 31.	April 2.	April 5.	April 7.	April 9.	April 12.	April 14.	April 18.	April 21.	April 24.
	%	%	%	%	%	%	%	%	%	%	%
Polymorphonuclear	61.0	60.0	55.0	77.5	71.0	73.5	65.5	76.5	66 0	62.5	63.5
Transitional	5.0	6.5	4.0	9 5	2 5	3 0	7.5	4.0	5.0	1.5	4 0
Large mononuclear	12.5	14.0	14.5	2.5	14.0	10.0	6.5	0.5	20.5	18.5	15.0
Lymphocytes	19.0	19.0	24.0	10.0	11.0	16 5	18.0	19.0	7.5	15.5	16.5
Basophiles	0.0	0.0	0 0	0.5	0.5	0 0	0.0	0.0	0.0	0.0	0.0
Eosinophiles	1.8	0.5	2.5	0 0	1.0	0.0	2.5	0.0	1.0	2.0	1.0
Blood plates	Inc.	Inc.	Inc.	Inc.	Inc.	Inc.	Inc.	Normal.	Inc.	Inc.	Inc.
Red blood corpuscles:											
Pallor	Marked.	Marked.	Marked.	Consid.	Marked.	Marked.	Marked.	Normal.	Marked.	Marked.	Marked.
Polychromatophilic	Consid.	Consid.	Consid.	Mod.	Consid.	Consid.	Consid.	Normal.	Consid.	Consid.	Consid.
Poikilocytes	Consid.	Consid.	Consid.	.....	Consid.	Consid.	Consid.	Normal.	Consid.	Consid.	Consid.
Basophiles, granular	Mod.	Mod.	Mod.	.....	Mod.	Mod.	Mod.	Normal.	Consid.	Consid.	Consid.
Normoblasts	0 0	0.0	0.0	0.0	0.0	0 0	0.0	0.0	0.0	0.0	0.0
Megaloblasts	0.0	0.0	0.0	0.0	0 0	0.0	0.0	0.0	0.0	0.0	0.0
Stimulating forms	0.0	0.1	0.3	0.0	0.0	0.0	1.0	1.0	1.0	1.0	0 0
Myelocytes	0.0	0.0	1.0	0.0	0 0	0.0	0.0	0.0	0.0	0.0	0 0

Digitized by Google

	Days.					
	18th.	20th.	22d.	24th.	26th.	29th.
Leukocytes	24,200 per ct.	16,800 per ct.	16,800 per ct.	17,000 per ct.	24,000 per ct.	25,800 per ct.
Polymorphonuclear	67.5	65.0	61.0	60.0	55.0	77.5
Transitional	7.0	6.0	5.0	6.5	4.0	9.5
Large mononuclear	16.0	15.5	12.5	14.0	14.5	2.5
Lymphocytes	9.0	11.0	19.0	19.0	4.0	10.0
Basophiles	0.5	0.5	..	..	..	0.5
Eosinophiles	..	2.0	1.8	0.5	2.5	..
Blood plates	Inc.	Inc.	Inc.	Inc.	Inc.	Inc.
Pallor	Inc.	Inc.	Inc.	Inc.	Inc.	Inc.
Polychromatophilic	Mod.	Mod.	Consid.	Inc.	Inc.	Inc.
Poikilocytes	Mod.	Mod.	Consid.	Inc.	Inc.	Inc.
Basophiles, granular	Consid.	Mod.	Mod.	Mod.	Mod.	Mod.
Normoblasts	1.0	..	..	..	..	..
Megaloblasts	..	..	..	..	..	..
Stimulating forms	..	..	..	..	..	..
Myelocytes	..	..	..	..	..	..

PATHOLOGICAL REPORTS.

March 7. Culture from abdominal cavity. No growth. (March 2.) Thacher.

March 7. "Gall-bladder." Somewhat thickened fibrous walls, deeply congested interior surface, split open; would contain about one and one-half ounces of fluid. One stone, faceted on two surfaces, about size of pigeon's egg; stone is dark brown externally, and somewhat lighter within.

Microscopic examination. Chronic suppurative inflammation of gall-bladder. Wall thickened; mucosa partly eroded.

March 13. Blood culture. No growth (March 16). Thacher.

March 7. Culture from gall-bladder. Contaminated. Thacher.

April 2. Culture fluid from right chest.

Microscopic examination. Rather thick bacilli which give all the reactions of Bacillus coli communis. Tuttle.

Digitized by Google

Bibliography.

Lamarchia. Cent. f. Chir., 1899, p. 43.
Pauchet. Bull. et mém. de la Soc. de chir., 1902, No. 41.
Auvray. Ibid., 1904, No. 33.
Roeser. Beit. f. Chir., Bruns, 1902, vol. xxxvi, p. 228.
Fontoynont. Bull. et mém. de la Soc. de chir., tome xxxi, p. 36.
Bardenheuer and Böger. Cent. f. Chir., 1905, p. 78.
Morison. Lancet, January 7 and 14, 1899.
Ballance. Trans. Clin. Soc., 1896, vol. xxix, p. 77.
Hörz. Beit. f. Chir., Bruns, vol. l, p. 188.
Hammer. Ibid., p. 684.
Berger. Archiv f. klin. Chir., 1902, Band lxviii.
Bessel-Hagen. Ibid., 1900, Band lxii.
Nöltzel. Beit. f. Chir., vol. xlviii, p. 309.
Carstens. New York and Philadelphia Med. Jour., 1905.
Von Beck. Münch. med. Woch., 1897, p. 1319.
Heaton. Brit. Med. Jour., 1899, vol. ii, 476.
Lewerenz. Cent. f. Chir., 1899, vol. xxvii, p. 654.

Digitized by Google

REPORT OF A CASE OF NON-PARASITIC CYST OF THE SPLEEN.

By THOMAS W. HUNTINGTON, M.D.,
SAN FRANCISCO.

BECAUSE of its rarity, an unusual interest attaches to the following case. In a paper read before this Association in 1905 by Powers, of Denver, 32 cases of non-parasitic cysts of the spleen were tabulated. While these probably do not represent all reported cases up to that time, it is nevertheless a fact that non-parasitic cysts of the spleen have been encountered by the surgeon infrequently, and, more rarely, has a definite diagnosis been made prior to exploratory incision.

On January 12 of the present year I was consulted by a woman, aged twenty-three years, and obtained the following history:

Family History. Parents both living, and well. Otherwise, family and personal history negative.

Past History. She was well up to the age of twenty-one years, and led an active life. Aside from slight digestive disturbances, has never consulted a physician until recently. Menstrual function normal. Was married fifteen months previously, and has never been pregnant. For a little less than one year previous to above date she had lived in Manila, where she enjoyed usual health, escaping all diseases of a tropical character. Has never had typhoid fever. Two years ago she noticed a slight enlargement in the left upper abdominal quadrant. As it occasioned no pain or discomfort she attached no special significance to it. Did not mention it to her relatives, and it was not until after her marriage that special attention was attracted to it. In its early history it seemed to be a rounded, smooth, rather resistant

Digitized by Google

mass about the size of a large orange. Careful inquiry failed to elicit any history of a traumatism.

Present Condition. The patient is a slightly built, rather delicate-looking person; features somewhat drawn, suggesting the later stages of pregnancy. Present weight, 106 pounds, which is for her the maximum. The skin rather tawny and apparently pigmented over irregular areas. On the whole, she seems fairly well nourished.

Physical Examination. Three weeks prior to operation. On inspection the abdomen below the navel line appears normal, presenting no abnormal or unusual features. Between the costal cartilage and above the navel the abdominal wall is forced markedly forward, as if by a spherical mass, which lies a little to the left of the median line. Percussion note over this area is absolutely flat. Dulness begins about two inches below the left nipple and extends to navel. Fluctuation was clearly manifest over the entire area. On manipulation the tumor seems slightly movable, but maintains its position fairly well, as above outlined. Over the convexity of the tumor, mobility is more apparent than in its upper portion, suggesting anchorage of its superior surface. Transverse colon was made out with tolerable accuracy at the transverse navel line. Gastric resonance not identified. At no stage of the examination and manipulation was pain or tenderness elicited. Circulatory apparatus normal. Urine normal. Hemoglobin, 85 per cent. Leukocytes normal. Red blood cells, 4,300,000.

Through force of circumstances it seemed necessary to defer an operative undertaking for about four weeks. Accordingly, final judgment as to the nature of the tumor was deferred, and the patient instructed to report at the end of two weeks.

Fourteen days later, on January 26, 1907, the following record was made: The tumor mass previously described has increased perceptibly in size during the past two weeks. The increased size is manifest in more marked elevation of the anterior abdominal wall, as well as in increased area of dulness. The tumor could easily be made out below the navel and entirely filled the space between the navel and the costal margins. The central point is

Digitized by Google

mobility of the spleen would have given additional facility to such an undertaking. But, despite the fact that Powers has collated a series of 10 cases treated by splenectomy without a fatality, I choose marsupialization because of the promise of a more satisfactory result.

There can be no question that an organ of so great functional importance as the spleen should be guarded jealously, and removed only when its retention becomes a positive menace, or its integrity destroyed. This position is emphasized by the following well-recognized facts, to which attention is called by Moynihan: "Both experimentally and clinically it has been determined that, following splenectomy, there is a diminution in the amount of hemoglobin; a reduction in the number of red corpuscles; an increase in the total number of white corpuscles." These changes attain their maximum in about a fortnight, and there is then a gradual return to the normal, which is reached in about four months. Mental disturbance is occasionally noted and frequently there is a general enlargement of lymphatic glands. In animals, absence of the spleen has been followed by marked changes in the bone-marrow, loss of weight, weakness, thirst, polyuria, rapidity of pulse, and enlargement of the thyroid. Furthermore, experimental work points strongly to the probability that absence of the spleen renders the subject more liable to septic infection.

In dealing with a spleen which has been disorganized and non-functionating for a protracted period prior to operation, immediate after-effects of splenectomy are less noticeable, owing to the fact that compensation has in a measure taken place during the preceding weeks, months, or years.

Digitized by Google

FOUR CASES OF RUPTURE OF THE KIDNEY, WITH REMARKS UPON CONSERVATIVE OPERATIVE TREATMENT.

By THOMAS R. NEILSON, M.D.,
PHILADELPHIA.

THE object of this contribution is to place upon record 4 cases of subparietal injury of the kidney which have been met with in the experience of the writer in his service at the Episcopal Hospital, Philadelphia, and which were treated surgically by conservative measures, and to consider the question of the employment of such means, rather than the radical one of nephrectomy, when possible, in the treatment of this class of injuries.

CASE I.—*Rupture of left kidney, with laceration of peritoneum and severe hemorrhage into abdominal cavity; fracture of tenth rib; laparotomy and lumbar incision; gauze packing; recovery.*

Jacob B., aged twenty-five years, a farm-hand, was admitted to hospital at 3.30 A.M. on April 14, 1901. Late in the afternoon of the preceding day he fell from and was run over by a heavy farm wagon which he was driving.

On admission, the patient complained chiefly of pain in the left chest, and stated that he had passed bloody urine. The abdomen was markedly distended and muscles rigid, especially in the lower part. Examination further disclosed a fracture of the tenth left rib near its angle. The only visible marks indicating that the man had been run over were a contusion in the left axilla and an abrasion of the left arm. The temperature was 99°, pulse 80, and respiration, 40. Later in the morning some fourteen ounces of bloody urine were obtained by catheter. It was found that the patient had a stricture of the urethra, the result of traumatism some years previously, and for several days after admission, until dilatation had partly relieved the condition, the catheter had to be relied upon entirely.

Digitized by Google

I first saw the man toward evening on the 14th, about twenty-four hours after the injury. The pulse had then become more frequent, the countenance pinched and anxious; there was abdominal pain and the distention had increased, and hematuria continued. I decided upon immediate operation.

Opening the abdomen by an incision through the outer border of the left rectus muscle, I found a great quantity of blood and clots in the peritoneal cavity, and on searching for its source quickly discovered a tear in the peritoneum over the left kidney, which was ruptured and bleeding. Placing a pad of gauze firmly over the kidney to temporarily control the hemorrhage, and finding no intra-abdominal organ injured, the abdominal incision was closed, after mopping out the blood and clots and inserting a glass drainage tube in the pelvis. The patient was then turned on his right side, and the left kidney exposed by an oblique lumbar incision. A large amount of blood and clots distended in the region about the kidney, and were removed, and the kidney was found to have been lacerated in several places, mostly in its lower half. Strips of iodoform gauze were firmly packed about it, controlling the hemorrhage, and the angles of the wound sutured.

While on the operating table the patient's condition became so bad that, in addition to free hypodermic stimulation, normal saline solution was given, both by intravenous transfusion and by hypodermoclysis.

After operation the pulse was 124 and the temperature 99.4°. During the night his condition twice became alarming from symptoms indicating edema of the lungs.

During the next two days the pulse varied from 130 to 144, and the temperature rose once to 101.6°. Thereafter both gradually fell, the chart showing nothing of special interest.

The urine, the day following operation, contained a large amount of flocculent sediment of the color of iron rust; there was a moderate trace of albumin, a considerable number of red corpuscles, and a few granular casts. On the 19th it was noted that it was slightly acid, contained a faint trace of albumin, a few clumps of pus cells, and numerous bacilli. On the 22d it was alkaline, contained

Digitized by Google

more pus cells, and very numerous bacilli. On the 23d a culture from the urine (still drawn by the catheter) was made, and the organisms were found to be streptococci and the Bacillus aërogenes. Shortly thereafter the number of bacteria became greatly reduced, salol having been given for a number of days. The urinary infection was more than likely produced by the catheter.

The general condition improved steadily from the third or fourth day, by which time abdominal distention had disappeared. The abdominal drainage tube was then removed, the incision healing without incident. From the lumbar incision there was rather profuse colorless discharge (urine) by the fifth day, which continued in quantity for several days. The gauze packing was entirely removed by the tenth day, and a wick of gauze was inserted to maintain drainage. The fistulous tract closed quite slowly, but finally healed soundly, the patient being discharged from the hospital on July 17.

CASE II.—*Rupture of right kidney, with laceration of peritoneum and hemorrhage into peritoneal cavity; laparotomy and lumbar incision; gauze packing; death from secondary hemorrhage.*

Paul F., aged sixteen years, was admitted to hospital in the evening of June 4, 1904. While playing ball in the street he ran in front of a trolley car, the fender of which struck him in the right hypochondriac region and on the head.

On admission there was found an ecchymosis of the upper right side of the abdomen and a contusion of the right side of the head and face. The boy was pale, his pupils dilated, but responding to light. The pulse was 100 and the temperature 100.4°. There was some abdominal pain and distention, but no muscular rigidity. Bloody urine was voided. Vomiting occurred during the night. Under stimulating treatment the condition improved.

By the next day the general condition was much improved, and the boy suffered less pain.

On June 9 the patient complained of great abdominal pain, and tenderness in the lumbar region had increased. In view of these, I operated, choosing the abdominal route.

Digitized by Google

The abdomen was opened through the right rectus muscle. No visceral injury was found, but there was a small quantity of blood in the peritoneal cavity, which had gained entrance from a tear of the peritoneum overlying the right kidney, the region about which was distended by a large hematoma. Closing the abdominal wound, I exposed the kidney by an oblique lumbar wound. The removal of blood and clots was followed by a great rush of blood, which was controlled by the introduction of iodoform gauze packs about the kidney. The organ had been nearly bisected by a transverse tear somewhat above its middle.

After operation the patient's condition was very bad, the pulse being 160. Reaction, however, took place, although slowly, and in forty-eight hours his condition was decidedly improved. Some bloody oozing into the dressings occurred. The temperature rose on the second day to 103°, but shortly afterward a gradual fall took place, the pulse also coming down at the same time. The patient did very well, although some urine escaped from the wound, until June 22.

On that day, in the forenoon, the balance of the gauze packs was entirely removed by the resident. At 12.30 P.M., on visiting the ward, I was struck by the pallor and restlessness of the boy, and going to the bedside and lifting the sheet, I found that he was bleeding badly from the wound, the dressing being saturated and a quantity of blood in the bed. The wound was quickly and firmly packed with gauze, controlling the hemorrhage; intravenous transfusion of normal saline solution was given, and free hypodermic stimulation employed. The patient's condition forbade any attempt at immediate operation, but I hoped that reaction might occur sufficiently to permit nephrectomy to be done. No improvement took place, however, and the boy died at 8.30 P.M.

CASE III.—*Rupture of the right kidney; fracture of tenth and eleventh ribs and of transverse processes of first and second lumbar vertebræ; lumbar incision; gauze packing; recovery.*

Barney McG., aged fifty years, a laborer, while at work at a coal wharf, was struck in the back by a heavy iron bucket. He was

Digitized by Google

brought immediately to hospital, where he was admitted in the afternoon of December 17, 1904.

Examination disclosed a large hematoma in the right lumbar region, which was exceedingly tender. The patient voided urine containing a large amount of blood. A diagnosis of ruptured kidney was made, and I operated immediately.

Making an oblique lumbar incision, the kidney was exposed and delivered. There were a number of lacerations of the convex border and of both the anterior and posterior surfaces as well as several contusions. The transverse processes of the first and second lumbar vertebræ and the last two ribs were fractured, and the hematoma was found to extend between the muscle planes of the loin.

While the pedicle of the kidney was firmly held, preventing hemorrhage, loose fragments of bone were removed, and the sharp bases of the fractured transverse processes of the lumbar vertebræ were cut off with bone forceps.

Iodoform gauze packs were then placed carefully about the kidney, which was returned, and the wound sutured in part. After operation the bladder was washed out, and there is no note of any recurrence of hematuria.

The highest temperature recorded after operation was 101°, on the second day, and the pulse rose no higher than 118, the first observation after operation. During the first seven days the smallest amount of urine voided was twenty-six ounces, on the third day, the largest, fifty-six ounces, on the seventh.

During the first forty-eight hours there was some bloody oozing into the dressing.

The progress of the case was satisfactory throughout, and the patient was discharged on February 11, 1905, with a small sinus remaining, but no urine escaped from it.

CASE IV.—*Rupture of left kidney; lumbar incision; gauze packing; recovery.*

James A., six years old, was admitted to hospital on May 4, 1905, having fallen from a pile of lumber upon which he was playing. He was brought at once by his mother to the dispensary of

Digitized by Google

the hospital, where his condition was found to be such that he was sent to the receiving ward.

On admission, his appearance indicated shock. His lips were pale, but the pulse was, however, only 96, and the temperature normal. There was no mark of injury to be seen, but the child complained of pain, and was tender to pressure in the left lumbar region. Bloody urine was obtained by catheter.

When I saw the boy, not long after his admission, I determined that his condition was due to hemorrhage from a rupture of the kidney, and operation was promptly done.

Opening the loin by an oblique lumbar incision, the kidney was exposed and delivered, and a quantity of blood and clots removed from the surrounding tissues. There were a number of small tears of the convexity and anterior surface of the organ, but it was most severely injured at its lower pole, from which quite a large piece was entirely detached. This was removed. Iodoform gauze packs were placed over the lacerations, the kidney replaced and held firmly by hammock strips of gauze at its poles. The wound was partly closed by silkworm-gut sutures.

The next day the patient's temperature rose to 101.8° and the pulse was 148. Bloody oozing saturated the dressings, and the child had two severe convulsions, the nature of which was not noted. Thereafter he did very well, both temperature and pulse gradually becoming normal.

The daily amount of urine voided during the first week varied from fifteen to twenty ounces.

On the ninth day the packing was removed from about the kidney, no bleeding occurring, and a small gauze drain was inserted.

Several days later it was noted that there was a slight discharge of urine from the wound, but this lasted only for a few days.

On June 24 the boy was discharged, the wound being completely healed.

In connection with these cases mention may be made of an instance in which a severe rupture of the liver was associated with rupture of the right kidney, hemorrhage from both organs being controlled by gauze tampons. This case occurred also in the

Digitized by Google

service of the writer at the Episcopal Hospital, and was reported to the Philadelphia Academy of Surgery in April, 1903.

The patient was a man, aged twenty-six years, who, while engaged in decorating a church, fell from a step-ladder a distance of ten feet, striking his right side upon the end of a pew. With assistance, he was able to walk home, where he remained until the morning of the third day after his injury, when he was admitted to the hospital. During the sixty hours preceding admission there had been pain over the lower right ribs, distress from accumulation of gas in the stomach, some general abdominal distention, hematuria, and twice hematemesis.

At the hospital the man's condition was found to be clearly indicative of hemorrhage, pallor of lips and conjunctivæ, pulse 120 and scarcely perceptible, temperature 97.5°. There was tenderness in the right upper quadrant of the abdomen, with rigidity of the rectus muscle; the liver dulness extended two and one-quarter inches below the costal margin; the patient once vomited a small quantity of blood and voided bloody urine. The leukocyte count was 12,000.

Stimulation by tincture of digitalis and strychnine was given hypodermically, and normal saline solution by hypodermoclysis before operation, which was done a few hours after admission.

While the hematuria pointed to renal lesion, the localized abdominal tenderness, with rigidity of the upper part of the right rectus muscle and the increase in the liver dulness indicated injury of the liver; and, accordingly, the abdomen was opened through the right rectus muscle.

A large amount of blood and clots were found in the abdominal cavity, the hemorrhage having occurred from a number of lacerations on the upper and lower surfaces and the posterior border of the liver, as well as from the upper pole of the right kidney, which was also ruptured and bleeding into the abdomen through a rent in the peritoneum overlying it. Hemorrhage from both organs was effectually controlled by iodoform gauze tampons, placed firmly against the lacerations. To afford thorough drainage, a second wound was made posteriorly between the eleventh and twelfth ribs,

Digitized by Google

and one end of each gauze pack was carried through it. Recovery without incident occurred, the patient being discharged from the hospital fifty-one days after operation.

The literature of the subject of renal injuries, since the publication, in 1878, by Maas,[2] of Freiburg, of a study of 71 collected cases, has grown, through the contributions of many writers, until it may be considered, in view of the infrequency of such cases in individual experience, to have reached fairly abundant proportions.

Before the American Surgical Association in 1896, Dr. W. W. Keen[3] read a paper with tables of 155 cases, not including those of Maas. In the same year Küster[4] published a study of 306 cases. In 1899, Tuffier[5] contributed an investigation into 198 cases. Delbet,[6] in 1901, went over the literature and analyzed 320 cases. In 1903, Dr. Francis S. Watson[7] wrote a most admirable, exhaustive, and analytical paper, based on 660 cases, including all published up to June of that year, 6 being cases of his own. In February of the present year, Dr. A. H. Barkley[8] published a "Tabulation of Cases and Bibliography of Ruptured Kidney," comprising 95 cases. Of these, however, all but 16 are included in the period covered by Watson's paper. In addition to these 16 cases, published since June, 1903, given in Barkley's table, the writer has been able to find in the literature, from that time to date, reports of 14 more, which, with the 4 here reported, make a total of 34 cases recorded since Watson's paper. The 14 cases alluded to have been reported by Mathieson,[9] Riddell,[10] C. A. Smith,[11] Cahen,[12] Mauclaire,[13] Chaput[14] (3 cases), Edington,[15] Michel,[16] Ninni,[17] Franklin,[18] C. B. Keetley,[19] and M. B. Miller.[20]

A study of these papers, tables, and case reports has been made with the object in view of ascertaining the results of surgical treatment of rupture of the kidney by packing, drainage, or suture of the renal wound, as compared with those of nephrectomy, and of determining the limitations within which conservative treatment may properly be employed. At the outset it is obvious that the comparison is not entirely a fair one, since it has to deal with the results of injuries which, in different cases, vary in extent, and which may or may not be associated with other and often grave injuries, as laceration of the peritoneum with hemorrhage into the abdominal cavity, injury

Digitized by Google

of the abdominal viscera, or injuries of other parts of the body, of themselves threatening life.

The highest mortality in subparietal injuries of the kidney is found in the cases not treated by surgical measures. Watson's analysis gives 270 cases, without complication, subjected to expectant treatment, with 81 deaths—mortality 27 per cent.; and in 56 with complications, and treated expectantly, there were 51 deaths—mortality 91 per cent. Keen, comparing the results of cases in which nephrectomy was done with those in which it was not, found a death rate in the former of 36.4 per cent., and in the latter 44.2 per cent.

As to the comparison between the results of treatment by conservative operation and those of nephrectomy, Watson's statistics favor the former procedures. Thus, he found that in 99 cases free from complication, treated by operations other than nephrectomy, there were but 7 deaths—mortality 7 per cent.; and that in 15 complicated cases so treated there were 7 deaths—a mortality of 46 per cent. In 115 cases not complicated and treated by nephrectomy, there were 25 deaths—mortality 21 per cent.; and in 45 cases having complications, 19 deaths, or a mortality of 42 per cent.

From the 34 cases, including those of the writer now reported, added to the literature since the publication of Watson's paper, the following statistics are obtained:

CASES WITHOUT COMPLICATIONS.

Treated by conservative operation:	*Cases.*	*Deaths.*
Lumbar incision, suture of renal wounds, with drainage	2	0
Lumbar incision, gauze packing, or drainage:		
Primary	5	2
Secondary	1	0
Nephrectomies:		
Lumbar, primary	6	2
Lumbar, secondary	5	2
Abdominal, primary	5	1
Abdominal, secondary	1	0

CASES WITH COMPLICATIONS.

Gauze packing and drainage, primary	2	0
Gauze packing and drainage, secondary	1	0
Nephrectomies:		
Lumbar, primary	2	0
Abdominal, primary	4	2

Digitized by Google

Of the 11 cases treated by gauze packing, suture of the kidney or drainage, 2 died—mortality 18.1 per cent. The causes of death were shock and collapse in 1 case; secondary hemorrhage in the other.

Of the 23 cases in which the kidney was removed, 7 died—a mortality of 30.4 per cent. The causes of death were: suppression of urine, 2; septicemia, 1; shock and hemorrhage, 2; peritonitis, 1; not stated, 1.

The showing in cases not dealt with by nephrectomy is so favorable, as compared with those in which the organ was removed, that it cannot fail to attract attention. It may be said that probably the difference is largely due to the fact that in the cases so treated the kidney was less severely injured than it was in those included in the other group. This, however, does not apply to many of the cases, for in some of them which the writer has studied the kidney had suffered greater traumatism than in some of those in which nephrectomy was done.

Surgical interference in rupture of the kidney is called for in the first place, for the control of the hemorrhage and the prevention of extravasation of blood or of urine into the tissues, or into the abdominal cavity, in case the peritoneum be torn; secondly, for the treatment of injuries of other organs which may have occurred in addition to that of the kidney; third, to place the injured kidney, whenever possible, under circumstances most favorable to repair; and, lastly, to provide means against the occurrence of infection.

When there are sufficient grounds for belief that hemorrhage is taking place, lumbar tumefaction, severe or persistent hematuria, evidence of fluid in the abdomen, with constitutional proofs of bleeding; or if in addition to indications of lesion of the kidney there be signs indicating the possibility of injury of the intestines or other abdominal organs, operation should be done without delay.

So-called expectant treatment is permissible only in cases in which the local symptoms are insignificant, constitutional symptoms absent, and slight hematuria alone directs attention to the

Digitized by Google

probability of renal injury. Of cases of this type there are not a few, and to their almost invariable recovery can be given the largest share of the credit due to non-surgical treatment.

When operation is to be done, the choice as to whether the abdomen should be opened, or the renal region alone exposed by lumbar incision, must be made after consideration of the symptoms presented in individual cases. Rigidity of the abdominal muscles, with general or localized tenderness, or dulness in the flanks on percussion, if present in addition to tumefaction and tenderness in the lumbar region, should make the decision in favor of laparotomy; while the absence of signs, except in the lumbar region, or the predominance of the latter, indicate lumbar incision as the proper course to pursue. Should abdominal section be done, the loin also should be opened, to provide for dependent drainage, whether the kidney be removed or not.

Should lumbar incision be chosen, the kidney having been exposed and brought out of the wound, blood and clots having been first removed from the surrounding region, hemorrhage temporarily controlled by pressure of the organ or its pedicle, and the extent of the injury ascertained, the question arises as to whether or not the organ may be spared. In those instances in which the violence has been so great as to pulpefy it completely, or for the most part, no more doubt as to the necessity of its removal can be entertained than could arise if the kidney be found entirely severed from its pedicle. Likewise, should nephrectomy be done, if one of the main vascular branches has been torn, fatally interfering with the circulation in a large portion of the organ. And, again, no other course of action should be considered, but the removal of a surgically diseased kidney, if ruptured.

But other cases will occur in which a single or even two clean tears nearly or quite divide the kidney; and others, more in number, having several or many more or less deep lacerations and contusions at other points, in which an effort to save the organ is justifiable. The ease and promptness with which repair of wounds of the kidney takes place is well recognized. It is relied upon in our operations of nephrotomy, whether done for the removal of stone

Digitized by Google

(in which cases more than one wound through the substance of the kidney are not seldom made), or for other causes.

It seems, therefore, to be entirely reasonable that every attempt should be made to save the ruptured kidney, if there seem to be fair grounds for thinking that its vitality is not threatened beyond reasonable hope, or that enough secreting tissue is likely to survive the injury to make preservation of the organ worth the while. Should a portion only of the kidney be badly mutilated, or even detached, it need not necessarily cause sacrifice of the whole of it. Partial is preferable to complete removal.

For the control of hemorrhage, the firm packing of gauze, either plain sterile or iodoform gauze, into or against the wounds, whether of the substance of the kidney or of its pelvis, is entirely reliable, and, more than that, can be quickly done, which is a point of value, and, in addition, it serves well for drainage. Loops of gauze passed beneath each pole of the kidney before it is replaced serve not only to hold it in position, but afford firm support to the packs, which can be introduced through the lumbar wound between the ends of the hammock strips. For the drainage of any dead spaces that may remain outside of the packed area, rubber tubes should be inserted.

Another, and, when applicable, perhaps a neater way of controlling hemorrhage, is approximation of the renal wound or wounds by means of mattress sutures of chromicized catgut. This measure does not seem to have met with general favor, however, or else the number of cases in which it could be employed is small, for Watson mentions but 8 instances, and the writer has found only 2 more in the cases since recorded, making in all 10 cases in 125 treated by conservative operation. Mathieson reports a case in which there were two large wounds transversely from the hilum, one of them almost bisecting the kidney. Catgut sutures controlled the bleeding effectually, and in three weeks recovery was complete. In a case reported by Chaput a single tear of the kidney was sutured. This patient also recovered, but bleeding from the wound continued for three weeks, and healing was not complete until three months had elapsed.

Digitized by Google

In Cheyne and Burghard's *Manual of Surgical Treatment*, suture of the kidney is spoken of as "much superior" to plugging, "and should be adopted whenever possible." It is suitable, however, in the writer's judgment only when the renal injury consists of one or more clean tears, and when the question of brevity of the operation does not have to be entertained; but when the wounds are lacerated and multiple, or when haste in operating is imperative, it is not available. If employed, drainage should be secured by a rubber tube.

Every recorded case in which the kidney wounds were sutured recovered, and in all but one of them the time of recovery was decidedly shorter than in the cases treated by gauze packing. But, while recovery from operation was prompt in all but 1 of the cases (Chaput's), the ultimate result in 2—1 recorded by Delbet and 1 by Watson—was not satisfactory. Secondary nephrectomy became necessary in Delbet's case, and was fatal; and in Watson's, a pseudohydronephrosis, with fistula, resulted.

In only 1 of the 5 cases which the writer has had could suturing have been done. In Case II, in which death from secondary hemorrhage took place, it may be that a different result would have been obtained if the single, clean, transverse tear had been closed by stitches. Should I meet with a similar case, and circumstances permit, I should suture the rent.

In spite of the advantage apparently offered by suturing, however, especially the shortening of the period of recovery, the number of cases to which it is adaptable must be small, and gauze packing, satisfactory both for hemostasis and drainage, must be relied upon in a larger number.

It must be admitted that there are some disadvantages attending the latter method, chief among which are the length of time required for healing of the wound, and the possible development of a fistula. Then there is the possibility of secondary hemorrhage, which has occurred in a few cases, and the chance—a small one—should infection of the damaged kidney or of the perirenal space occur, of its being conveyed by way of the bladder to the opposite kidney.

Digitized by Google

It is quite true that the time required for healing is much longer than it is when nephrectomy is done, and this is unavoidable. As to urinary fistula, it has, in the recorded cases, been persistent in but a very small number, and in the cases of the writer which recovered it healed without difficulty. Should it, however, resist all ordinary measures to induce healing, nephrectomy may ultimately be required. Secondary hemorrhage has occurred in but a very few of the cases treated conservatively, and can usually be controlled by packing, as in the first place, and a further attempt made to save the kidney. The conveyance of infection to the opposite kidney is, if proper attention be given to the bladder, practically a remote contingency, and should not be given undue weight.

The final question is whether the disadvantages of conservative treatment of the injured kidney are of greater moment to the patient than its loss would be, and whether the slight risks are not fully compensated for by the preservation of an organ of such vital importance.

A word as to the care of the bladder. It is of the utmost importance that it should be freed of blood and clots, whether by washing with boric-acid solution or normal saline solution, which will usually suffice, or by the evacuator tube, if so filled with clot that washing is not effectual; or, if that means fails, by suprapubic cystotomy, which may also be required should a tight urethral stricture prevent the use of a catheter. For some days after injury irrigation of the bladder should be done, and, in addition, as a further safeguard against infection of the bladder, urinary antiseptics may advantageously be given by the mouth.

REFERENCES.

1. T. R. Neilson. Annals of Surgery, 1903, xxxviii, 121.
2. H. Maas. Deutsche Zeitschr. f. Chir., 1878, 10, 126.
3. W. W. Keen. TRANS. AMER. SURG. ASSOC., 1896, xiv, 293.
4. Küster. Die Chirurg. Krank. der Nieren. Deutsche Chirurgie, Lief. 52 b., 196, Stuttgart, 1896.
5. Tuffier. Duplay et Reclus' Traité de Chirurgie, 1899, 2d ed., vol. vii, 164.
6. P. Delbet. Ann. des Mals. des Org. Genit.-Ur., 1901, xix, 669, 805.
7. F. S. Watson. Boston Med. and Surg. Jour., 1903, cxlix, 29.

Digitized by Google

8. A. H. Barkley. Louisville Monthly Jour. Med. and Surg., 1907, xiii, p. 307.
9. A. L. Mathieson. Quart. Med. Jour., Sheffield, 1902–3, xi, 134.
10. J. S. Riddell. Scot. Med. and Surg. Jour., Edinburgh, 1903, xiii, 54.
11. C. A. Smith. Northwest Med., Seattle, 1903, i, 385.
12. F. Cahen. München. med. Wochenschr., 1903, l, 2205.
13. Mauclaire, Cresson and Kuss. Bull. et Mém. Soc. Anat. de Paris, 1904, lxxix 332–336.
14. Chaput. Bull. et Mém. Soc. de Chir. de Paris, 1905, N. S., xxxi, 402.
15. G. H. Edington. Glasgow Med. Jour., 1905, lxiii, 136.
16. G. Michel. Rev. Méd. de l'Est., Nancy, 1905, xxxvii, 84.
17. G. Ninni. Gior. Internaz. d. Sc. Med., Napoli, 1905, N. S., xxvii, 635.
18. A. L. Franklin. Amer. Jour. Surg., 1906, xx, 309.
19. C. B. Keetley. West London Med. Jour., 1906, xi, 110.
20. M. B. Miller. Annals Surg., 1907, xlv, 306.
21. Cheyne and Burghard. Manual of Surgical Treatment, 1903, Part VI, Section II, Chap. xix, 191.

Digitized by Google

A CASE OF OIDIOMYCOSIS (BLASTOMYCOSIS) WITH RAPID GENERALIZATION, THE EARLY LESIONS SIMULATING GIANT-CELLED SARCOMA; DEATH IN SIX MONTHS.

By WILLIAM B. COLEY, M.D.,
NEW YORK,
AND
MARTHA TRACY, M.D.,
NEW YORK.

On January 21, 1907, I saw, in consultation with Dr. Geo. E. Reed, of Brooklyn, a patient whose history is as follows:

F. N., aged twenty-seven years, policeman by occupation, of unusual physical development, 6 feet 3 inches in height; weight, 270 pounds. The man's health had always been good; the only thing in the previous history that might possibly have some bearing upon the etiology was the fact that while bathing in the early part of August he cut his left foot with a clam shell. The foot swelled and was quite painful for the next few days, without, however, detaining him from his regular work. On about December 1st he was taken with a severe attack of pain in the lumbar region, which he regarded as lumbago, and which kept him confined to the house. Two to three days later he began to have severe pain in the dorsal region of the left foot, which became markedly swollen, the swelling apparently starting over the second or third metatarsal bone and quickly involving the entire dorsum of the foot. After a few days it showed signs of fluctuation, and at the end of ten days a small sinus appeared between the great and second toes, from which there exuded dirty, pus-like material; the skin, while tense and distended, was not reddened. About a week later a similar lesion

Digitized by Google

developed on the dorsum of the other foot, and on the outer aspect of the right thigh, just above the knee, two small flat papillary tumors appeared in the skin itself. These were irregularly circular in shape, depressed in the centre, with indurated edges, slightly elevated above the normal skin. They became quickly covered with crusts which, on removal, showed a small collection of pus-like material in the centre. The patient states that he often scratched and picked around these ulcers and later scratched his face. Whether as a result of auto-inoculation or not, about a week later similar small papillary tumors developed in the face, the number and character of which are well shown by the accompanying figure. The lesions upon the face were larger and more protuberant than those just described upon the thigh, projecting about one-quarter to one-third of an inch above the surrounding surface; they were reddened and indurated at the base, soft in the centre, and quickly covered by thick scabs or crusts. These could be easily picked off, and always showed underneath a few drops of yellowish pus. Almost simultaneously with the skin lesions described, there developed numerous subcutaneous tumors widely distributed over various parts of the body, but chiefly in the thighs and arms. These tumors varied from the size of a hazelnut to that of a small egg; they always began subcutaneously or in the deep layer of the skin, appearing first as smooth, spherical tumors of moderately firm consistence, scarcely raised above the level of the skin. As, after a few days, they increased rapidly in size, they became much more protuberant, the skin showed attachment in the centre; they soon showed signs of fluctuation, and, after a few days, the entire tumor seemed little more than an abscess cavity. If left to themselves they usually broke after a week or ten days, discharging a dirty, cream-colored material. Coincidently with the appearance of the first tumors, the patient began to have a dry, hacking cough, which is almost constant, and which has persisted steadily up to the present time, refusing to yield to any form of treatment. The patient's general health deteriorated very rapidly; within the first three weeks he lost sixty pounds in weight. Two weeks after the beginning of the symptoms one of the small subcutaneous tumors

Digitized by Google

was removed before it ruptured, and microscopic examination was made by Dr. Van Cott, of Brooklyn, who pronounced it giant-celled sarcoma.

The patient was admitted to my service at the General Memorial Hospital on January 23, seven weeks after the beginning of the disease and two days after I first saw him, at which time his condition was as I have just described. In addition to the two superficial papillary skin lesions on the right thigh, as mentioned, there were five or six similar lesions in the face and about twenty of the subcutaneous tumors in different parts of the body. The course of the disease, since his admission to the hospital, has been briefly as follows: Photographs and drawings were made three days after his admission, or at the end of the third week of the disease. On January 25, after carefully sterilizing the skin, and under all possible aseptic precautions, I opened several of the subcutaneous tumors, and Dr. S. P. Beebe, of the Huntington Cancer Research Fund, made cultures upon a large variety of media, and several dogs and guinea-pigs were inoculated with the material. As none of the culture tubes showed any growth at the end of four days, they were thrown away. A section of the wall of one of the tumors was examined by Dr. James Ewing, and although the general appearance was strikingly like that of a giant-celled sarcoma, one or two round bodies, characteristic of the blastomycosis organism, were found, and the diagnosis of blastomycosis was made. In the opinion of Dr. Ewing, the giant cells were more like foreign body giant cells than those seen in sarcoma. This organism is of much slower growth than pyogenic bacteria, seldom showing growth before the fourth day, which accounts for the fact that our previous cultures were considered sterile. I, thereupon, opened several other tumors, also the large swelling upon the right foot, from which about four ounces of material of the consistence of cream, but much darker in color than the fluid removed from the subcutaneous tumors, was evacuated. New cultures were made by Drs. Beebe and Tracy, and on about the fourth day they began to show pure cultures of the organism. The accompanying figures show its appearance at different stages before and after budding.

Digitized by Google

Animal inoculations were made with the pure cultures, with the result as shown by Dr. Tracy's report:

PATHOLOGICAL REPORT BY DR. MARTHA TRACY.

The tissue sent for examination was cut from the wall of a subcutaneous abscess. It was of a rather pale-pink color and medium firmness. Fixation was in Müller formol and staining with hematoxylin and eosin.

Microscopic examination shows tissue composed of rather loose stroma and abundant round cells. Very many of the cells are polynuclear leukocytes. Others, less numerous, are larger, more or less epithelioid in type, with large vesicular nuclei. Large giant cells are also present. These are particularly abundant in a section from the original abscess in the foot. The giant cells are of a characteristic type, containing six or more large nuclei, centrally placed. Many new-formed bloodvessels are present, and here and there collections of free red blood cells. The whole appearance is typical of an active inflammatory reaction.

Throughout the section, and often within giant cells, are seen the spherical forms of the oidiomyces. The bodies are granular and their nuclei take the hematoxylin stain. They contain refractile points, and the double refractile contour is conspicuous. Some of the giant cells contain four or more of the organisms of various sizes.

No endogenous cell division is observed, but occasional budding forms are seen.

Sections from lesions involving the skin show considerable dipping down into the corium of cords of epithelial cells. In sections of tissue from an experimental subcutaneous lesion in a dog the microscopic appearance is similar, save that the giant cells are less numerous. Rather sharply limited aggregations of leukocytes are noted about the periphery of which the spherical organisms are numerous. Here several budding forms are found.

Pus from the abscesses in moist show very many spherical and budding forms of the organisms. A hanging drop of the pus in

Digitized by Google

physiological salt solution showed mycelial growth in forty-eight hours. Smears from the pus of the original abscess in the foot and from the secondary lesions were made on glycerin-agar, glucose agar, and potato. Growth was evident in the potato tubes and in the agar tubes of alkalinity +8 (phenolphthalein) after four to five days. In tubes slightly more alkaline, three weeks elapsed before the colonies appeared. After the first appearance the growth was quite rapid at room temperature. The cultures on glucose agar are somewhat more luxuriant than those on glycerin agar.

The appearance of the growth is typical. White, pinpoint-raised colonies appear, which increase on the surface of the agar and extend down into it to a slight extent. The colonies are very brittle, and mycelial threads are thrown out on the free surface.

Subcultures grow more rapidly than did the original, and seemed but slightly retarded by low temperature, even that of the ice chest.

In broth, the growth formed a semi-opaque, mobile sphere of the size of a walnut, in a month.

Cultures from the patient's blood were negative.

Rabbits, guinea-pigs, white mice, and dogs were inoculated from the pus. Only two of the animals gave positive results. One mouse, inoculated peritoneally, died of generalized infection in a week. Lesions showing the organism in the sections were found on the peritoneum, in the liver and in kidney. Cultures from these organs failed to grow.

One dog developed subcutaneous abscesses resembling closely the secondary lesions in the patient. From the pus the organisms were successfully grown in the hanging drop and on the glucose-agar.

The mycelial formation which took place in all the cultures determines the position of the organism in the class of oidiomyces, as distinguished from the blastomyces or true yeasts, which multiply only by budding.

A more elaborate culture study of the organism has not yet been completed.

Dr. Beebe also made a number of blood cultures, but these were found uniformly sterile. During the first two weeks of the patient's

Digitized by Google

stay at the hospital, while the possibility of the condition being sarcoma was entertained, he was given ten injections with the mixed toxins of erysipelas and Bacillus prodigiosus; the highest dose was 6 minims. Only moderate reactions followed, his temperature never going higher than 103°. He had been running an irregular temperature ever since his trouble started, same ranging from 97° to 102°. After the diagnosis of blastomycosis was made, I put him upon large doses of iodide of potassium, the value of which in this disease has apparently been demonstrated by Bevan and Hyde in the group of cases observed in or about Chicago. The dose was increased steadily, until he was receiving 250 grains a day, but the treatment apparently had not the slightest effect in retarding the progress of the disease. The patient continued to lose weight steadily, new lesions constantly appeared, the cough persisted, and hemoglobin rapidly fell. Examination of the urine at the time of entrance showed a specific gravity of 1030; acid reaction; clear amber color; a trace of albumin. There have been no albumin nor casts since. The specific gravity has steadily fallen; the last examination, on April 7, showed 1008, straw color; no albumin; no casts. Frequent examinations of the blood have been made, as follows:

January 24. White blood cells, 18,000; red blood cells, 4,000,900; hemoglobin, 85 to 90 per cent.

27*th*. White blood cells, 18,200; polynuclear, 75 per cent.; small lymphocytes, 20 per cent.; large lymphocytes, 3 per cent.; eosinophiles, 1 per cent.; giant cells, 0.5 per cent.

Two other counts made the same day showed practically the same result.

February 4. White blood cells, 10,000; red blood cells, 3,000,840; hemoglobin, 75 per cent.

16*th*. White blood cells, 31,000; red blood cells, 3,480,000; hemoglobin, 50 to 55 per cent.; polymorphous, 76 per cent.; small lymphocytes, 21 per cent.; large lymphocytes, 3 per cent.

26*th*. Red blood cells, 3,000,160; hemoglobin, 55 per cent.; white blood cells, 21,800; lymphocytes, 9 per cent.; mast cells, 1 per cent.

Digitized by Google

March 23, 1907. There is a marked decrease in the number of red blood cells and hemoglobin, and a great increase in the polynuclear cells. Red blood cells, 2,000,250; hemoglobin, 30 to 35 per cent.; white blood cells, 30,000; polynuclear, 92 per cent.; small lymphocytes, 5 per cent.; large lymphocytes, 2 per cent.; mast cell, ½ per cent.

The temperature at this time ranged between 97.8° F. and 102.8° F. Some days, however, it would not rise above 99.5° F.

As the patient's condition had been steadily getting worse under the iodides, they were discontinued on April 1, and, purely as a matter of experiment, the toxins resumed, 1 minim being given on April 1, and the dose has been increased by 1 minim a day since.

April 3. The blood count shows red blood cells, 3,240,000; hemoglobin, 25 per cent.; white blood cells, 24,400; polymorphous, 88 per cent.; small lymphocytes, 7 per cent.; large lymphocytes, 2 per cent.; eosinophiles, 3 per cent; being a considerable improvement over the previous examination.

On April 8, he had 60 tumors or lesions distributed throughout the body, as follows: Face and neck, 15, 13 of which have been opened; abdomen, 7, 4 opened and curetted; legs and thighs, 24, of which 22 have been opened and curetted; arms, 11, 8 opened; chest, 2; back, 6, 2 of which have been opened. The largest one of all of these, excepting the lesion in the dorsal region of the foot, is one that has recently formed over the sternum, being about the size of a goose egg. It has already softened, and will be opened shortly. The lesions upon the face have nearly disappeared under the treatment with carbolic acid, three to four applications having been made in the following manner: A saturated solution of Schering's carbolic was applied by means of cotton to the face lesions, the acid being allowed to remain for one minute; then the effect was counteracted by alcohol. The skin lesions almost entirely disappeared, leaving, however, well-marked reddened scars. A few weeks later they returned and increased rapidly in size.

The site of the initial lesion in this case was, in the opinion of Dr. Welch, of Johns Hopkins Hospital, very probably the lungs,

Digitized by Google

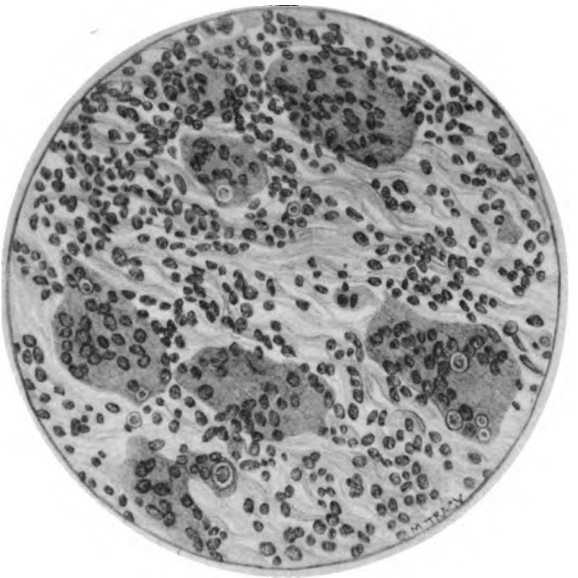

1

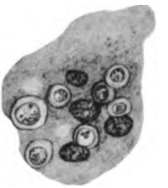

2

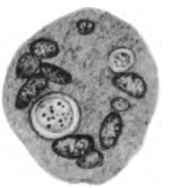

3

4

5

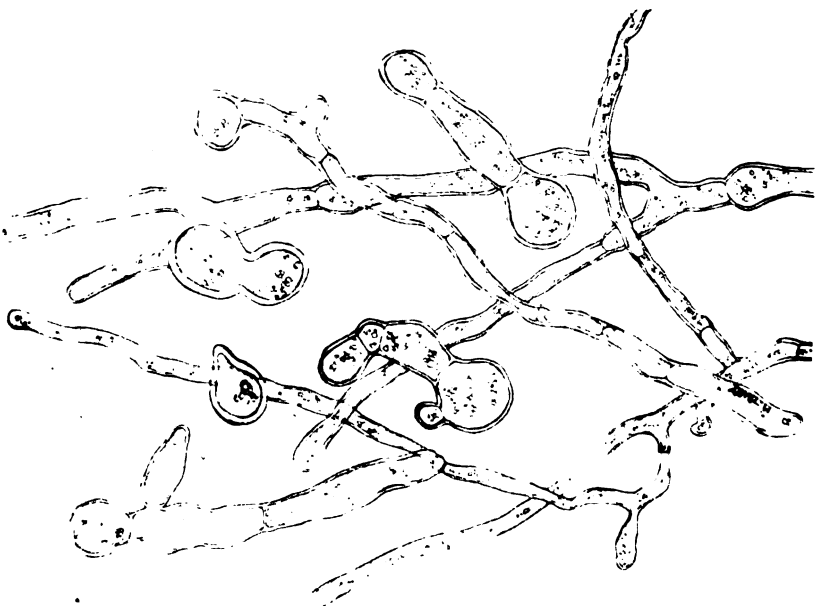

6

Digitized by Google

Digitized by Google

1

2

Digitized by Google

Digitized by Google

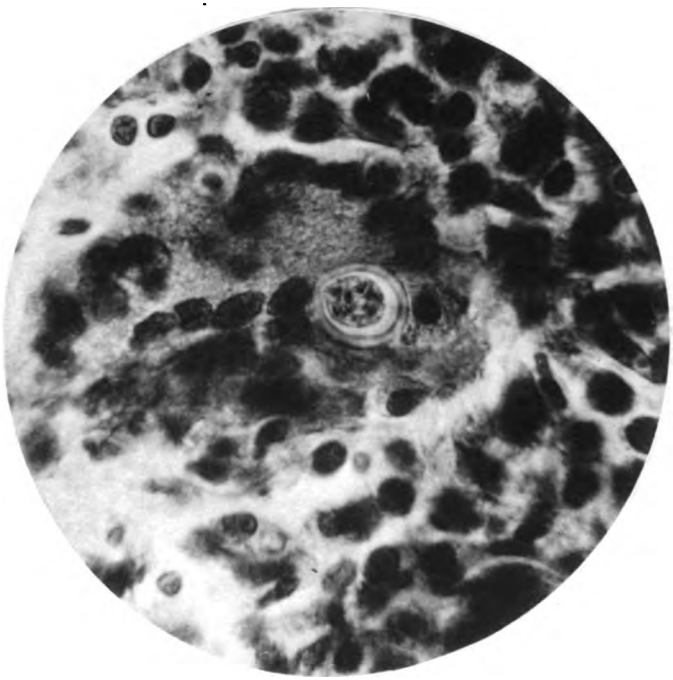

1

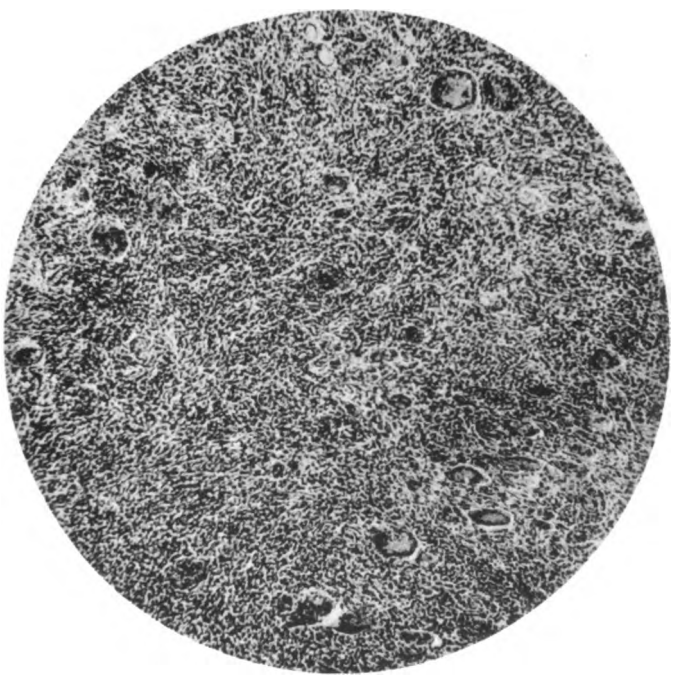

2

Coley and Tracy.

Digitized by Google

Digitized by Google

although there is a possibility of the infection having entered the blood current through the wound in the foot in August, starting a primary lesion in the lung, from which the general infection spread.

The experimental inoculations by Leopold (quoted by Busse) with blastomycosis in dogs, showed that the organism produced lesions which he regarded clinically and microscopically round-celled sarcoma. Although his investigations have not been confirmed by subsequent writers, the present case shows that in the early period of the disease the lesions so closely resembled round-celled sarcoma as to be easily mistaken for it; but as the disease progressed, subsequent lesions became less and less like sarcoma, and are more like pyemia.

I have had one case of round-celled sarcoma which, in many respects, closely resembled the present case in its early stages. In this case, Mrs. L. W., aged fifty-five years, with a primary large round-celled sarcoma in the parotid, recurring shortly after operation, a large number of metastatic tumors developed a few months after the local recurrence; they all occurred in the deep layers of the skin, varying in size from a hazelnut to a goose egg, firm in consistence in the beginning, but later becoming softened in the centre, and, on opening, showing material of creamy consistence, not unlike the substance found in the subcutaneous lesions of blastomycosis, except that it was white in color and a little thicker in consistence. Some of these lesions I removed under cocaine for microscopic examination, and they proved to be typical round-celled sarcoma.

A careful study of the cases of blastomycosis thus far reported, as well as those of coccidioidal granuloma, leads me to believe that clinically my own case belongs to the latter rather than to the blastomycosis group. The latest paper on this subject is that of Philip King Brown, of San Francisco (*Jour. of the Amer. Med. Assoc.*, March 2, 1907), containing a very complete report of 1 case of his own, 2 additional, 1 very complete, the other somewhat doubtful, together with a summary of 16 previously published cases. The clinical history and course of the disease in my own

Digitized by Google

is strikingly identical with that of the case so fully reported by Brown. In his, as in my own, the subcutaneous swellings were primary and the cutaneous lesions secondary and unimportant. In his there was a large swelling over the dorsum of the right hand, while in mine the dorsum of the foot was affected. In both cases there was absence of glandular swelling. There was no redness, or tenderness, or edema of the overlying skin. The cutaneous lesions were likewise identical, beginning with the papillæ, rapidly developing into papillary tumors, circular in shape, and covered with crusts. In Brown's case the range of temperature is practically the same as in my own—99° F. in the morning, often running to 102° F. in the evening. The blood examinations in his case likewise are similar to mine, being: Reds, 2,500,000; whites, 13,000; polymorphonuclears, 79 per cent.; small lymphocytes, 17 per cent.; large lymphocytes, 2 per cent.; eosinophiles, 2 per cent.; hemoglobin, 50 per cent.

In addition, Dr. Mary Halton, of San Francisco, who made the autopsy in Dr. Brown's case, and had an opportunity of studying the cultures, has just made a careful examination of our own slides and cultures and pronounced them identical with those of Brown's case.

Our cultures and slides were submitted to Dr. Welch, of Johns Hopkins Hospital, who is unwilling to state definitely whether the organism is of the coccidioidal or blastomycotic type. He says that the two modes of multiplication of the tissues is the chief distinguishing mark between the San Joaquin Valley parasite and that observed in other parts of this country (except Wolbach's case in Boston, which is coccidioidal). He adds that it would be interesting (and may be true) if both forms of the parasite produce identical lesions and symptoms, in certain cases, although he was under the impression that the coccidioidal disease was more like tuberculosis. In the specimens which he had seen of the coccidioidal disease, the internal lesions were astonishingly like tuberculosis.

Specimens of my case have recently been sent to Dr. William Ophüls, of San Francisco, as probably the highest authority on

Digitized by Google

the subject. Up to the present time I believe that no cases of coccidioidal granuloma have been described in people who had not been in California, except the very first case observed by Wernicke (*Centralbl. f. Bact.*, 1892) and the case of Wolbach, of Boston. The first case in California was described by Rixford (*Occidental Med. Times*, 1894, viii, 326). Another similar case, under the care of Drs. Thorne and Robinson (Thorne, *Occidental Med. Times*, viii, 703), was seen by him the same year.

Thus far there have been reported 42 cases of blastomycosis or blastomycotic dermatitis, of which 32 were local and 10 disseminated. Of coccidioidal granuloma or oidiomycosis there have been 18 cases reported.

As to the supposed distinguishing features between the two groups of cases, it may be said that coccidioidal granuloma is almost invariably progressive, with marked tendency to generalization by blood and lymph, the secondary skin lesions being due to emboli. Generalized infection is the rule. Only one patient is known positively to be alive. In this case the primary lesion was in the foot, which was promptly amputated. In these cases, iodide of potassium is practically of no benefit.

In cases of blastomycosis the disease is usually local, and progress is slow and the tendency to generalization slight. Thus far there has been observed only one case with generalization, which died, although iodide of potassium had been followed by improvement.

In the cases of coccidioidal granuloma, the site of the initial lesion was in the skin in 5, internal (chiefly lungs) in 12, unknown in 1.

As regards the residence of the 18 cases so far reported, 14 are positively known to have resided in the San Joaquin Valley; 1 negative; 3, the place of residence is not known.

Dr. James Ewing, Professor of Pathology at Cornell University, who has made a careful study of the organism as well as the section from the tumors from my case, expresses his opinion as to its nature as follows:[1]

[1] Thanks are due to Dr. William J. Elser and Dr. Frank M. Huntoon for the successful cultivation of the organism and for permission to report their results.

Digitized by Google

"It is impossible in our present state of knowledge to give the final classification of the organism in this case; it can only be done in a general way. The three groups among which it lies are blastomycetes, the oidia, and the hyphomycetes. The blastomycetes possess large cells with definite membranes. They multiply by budding, and never produce mycelia. Your organism has a definite membrane, but produces abundant mycelium, and hence is not a blastomyces. The hyphomycetes produce mycelia, and hyphæ and sporangia. Your organism has no sporangia, and hence it is not in this class. The oidia lie between these classes, as they multiply by budding and produce mycelia. Your organism multiplies by budding in the tissues, and produces abundant mycelium in cultures. Sporangia have not yet been observed in it. Some organisms of this group produce very little mycelium in cultures and that very slowly. There seems to be a great many species in the group, some in which budding is more prominent; others in which mycelium formation is more pronounced. Unfortunately, these characters are not stable; hence the difficulty of classification. Therefore, Ricketts makes three classes: (1) Blastomycetoid; (2) oidium-like; (3) hyphomycetoid.

"Wolbach's organism is peculiar in that it does not bud in tissues but multiplies by endogenous sporulation, producing large cysts with many spores. Nevertheless, it produces mycelia and sporangia in cultures. It is, therefore, hyphomycetoid. Your organism is quite different from Wolbach's, producing no endogenous spores, budding freely, but not, so far, producing sporangia. It may, therefore, be placed for the present in the intermediate group of true oidia. Much further study will be required before it can be finally classified."

Dr. Ophüls, to whom slides and culture were sent, reports as follows, under date of April 1, 1907:

"In the sections you sent me the organism is considerably smaller than the one which we find in California. As you say, they show budding and no endosporulation. The macroscopic appearance of the culture is exactly like that of the organism of the coccidioidal granuloma, but microscopically this also shows some differences.

Digitized by Google

The tryphæ show lateral budding in places which I have never observed in my cultures; there are many spherical and pear-shaped bodies which also do not occur in them, and there is complete absence of the peculiar angular spores. These latter, however, do not form in all cultures.

Condition about four weeks before death.

"On the whole, the organism is more like some of those described from Chicago. I believe, however, with Ricketts, that all these organisms belong to the same group. It may be preferable to classify them with the blastomycetes rather than with the oidia, as Ricketts does."

Digitized by Google

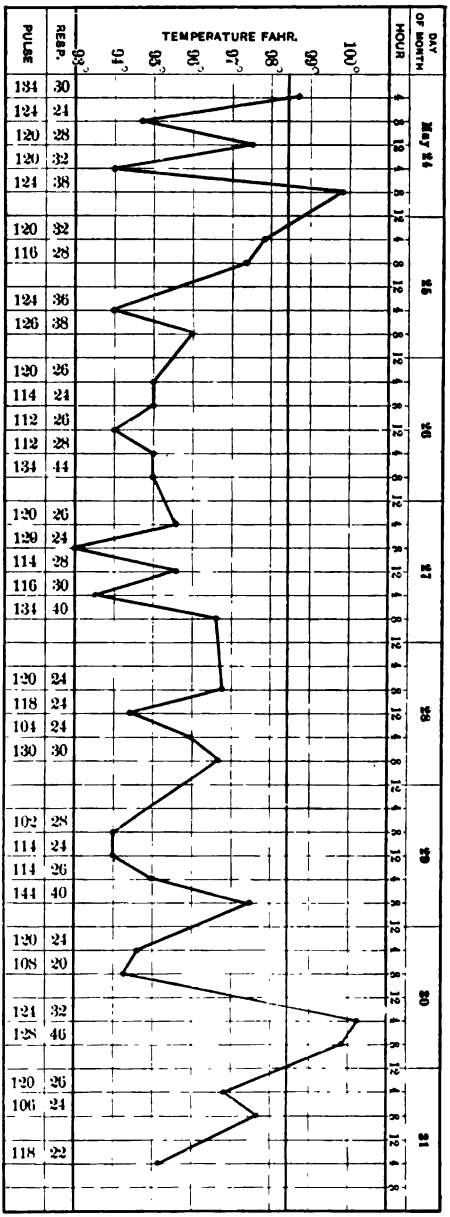

Digitized by Google

June 1, 1907, later history. A month ago it did not seem possible that the patient could live more than a very few days. During this last month his temperature has very frequently—at times, several mornings in succession—gone down to 94°; in some instances to 93.6°. His emaciation is extreme. New lesions have developed in almost every part of the body. Instead of being small and circumscribed, as in the early period of the disease, they are now so extensive that in some cases as much as a pint or a quart of pus is discharged in twenty-four hours. He is simply one mass of sores and abscesses from head to foot, which require about three hours for a single dressing. In spite of his condition, his appetite has been fairly good. The patient died June 10, 1907, a trifle more than five months from the beginning of the disease. An autopsy was made and showed the lungs extensively involved with the same process.

The accompanying chart shows the extreme range of temperature the last few weeks.

Digitized by Google

SOME CONSIDERATIONS IN REGARD TO BRAIN SURGERY.

By STEPHEN H. WEEKS, M.D.,
PORTLAND, MAINE.

THE fact that the brain may be exposed for the removal of diseased parts, in appropriate cases has made it necessary to ascertain the relation of its different fissures and convolutions to the cranial sutures, or to certain landmarks upon the surface of the head. The most important are the fissure of Rolando, fissure of Sylvius, and the parietoöccipital fissure.

The fissure of Rolando may be found in several ways, but the method I like the best, because I have made use of it for many years before my classes, is that of M. Lucas-Championnière. It is as follows: First find the bregma, that is, the spot where the coronal joins the sagittal suture, by carrying a line directly over the vertex from one external auditory meatus to the other. The upper end of the fissure of Rolando is situated about 2 inches behind the bregma. The lower end of the fissure corresponds to a spot $2\frac{3}{4}$ inches behind the external angular process, and about 1 inch above it. These two points are connected by a line drawn from the upper to the lower point. This line lies directly over the fissure of Rolando, and is about $3\frac{3}{4}$ inches long. To find the fissure of Sylvius, lay down a base line from the lower margin of the orbit to the external auditory meatus. Lay down a second line parallel to the base line from the external angular process of the frontal bone backward $1\frac{1}{4}$ inches, and then measure upward $\frac{1}{4}$ inch. This gives point one. Find the most prominent part of the parietal eminence, from it draw a line downward, perpendicular to the base line, and on this take a point $\frac{3}{4}$ inch below the eminence; this gives point two. Join these two points and the line will lie over the fissure of

Digitized by Google

Sylvius. The fissure of Sylvius is about 4 inches long. To find the parietoöccipital fissure, continue the line of the fissure of Sylvius to the median line. At this junction lies the fissure. Since all areas now open to surgical operation can be located with a definite relation to these three fissures, with the exception of the fissure of Bichat, described later, no further rules are necessary.

In order to get some data of value in regard to the motor area with relation to the fissure of Rolando, Drs. Mills and Frazier, of Philadelphia, made an analysis of the results of faradic application in 25 cases, these including, as nearly as they could determine, 138 applications. It is probable that the whole number of applications, made in the 25 cases, was somewhat larger than is given, but the results of the tabulation and analysis can be relied on as accurate in their teachings. It is evident that the data are overwhelmingly in favor of the views that the motor region is in front of the fissure of Rolando. These results correspond closely with those of Sir Victor Horsley. An interesting practical matter in connection with the question of centre movements of the head and eyes is that which is brought up by the fact which several observers have noted as the result of human cortical faradization, that movements of the head sometimes take place toward the side on which the application is made. A case of Jacksonian epilepsy was recently reported in which the spasm began in the upper extremity of one side, the head turning during the convulsive attack toward the other side. The problem involved in these apparently contradictory observations as to the movements of the head and eyes is one which must receive further careful consideration.

There are two essential preliminaries to any operation on the brain. The first is the diagnosis of the nature of the disease which is present, and the second is the diagnosis of its location.

A careful study of the various symptoms, of the order and manner of their development, and of the general history of the case, will usually lead to a diagnosis of the nature of the disease present. It should be constantly borne in mind that surgical interference is not warranted in any case unless the nature of the disease is well determined. The second essential preliminary to operation is a

Digitized by Google

knowledge of those facts regarding the localization of brain functions—so far as they are at present determined—which may lead to a correct diagnosis of the location of the disease. There are certain areas upon the cortex of the brain whose functions are accurately known. The areas are: (1) The sensorimotor area; (2) the speech areas; (3) the visual area; (4) the auditory area; (5) the area of sensation of smell and taste.

The sensorimotor area includes the cortex of the anterior and posterior central convolutions which border the fissure of Rolando, and the adjacent cortex in front (chiefly in front) and behind this fissure. Each hemisphere controls movements on the opposite side of the body, but as the right hand is more generally used, and is better trained than the left, this area is larger on the left hemisphere than on the right. The cortex of the posterior part of the second frontal convolution controls the movements of the eyes and head. Impulses starting from this point produce conjugate movements of these parts toward the opposite side.

The eye district is below; the head district above. The lower third of the anterior and posterior central convolutions governs the movements of the face, tongue, larynx, and pharynx. The eyebrows and cheeks are controlled by the upper and forward part of the area; the tongue and larynx by the lower and forward part; the mouth, pharynx, and platysma by the hinder part.

The middle third of the anterior and posterior central convolutions controls the motions of the upper extremity; the shoulder motions being controlled by the anterior and upper part of this area; the elbow motions by its middle part, and the hands and finger motion by its posterior and lower part. The upper third of the anterior and posterior central convolutions controls the motions of the lower extremity; the thigh, knee, foot, and toes being governed by various parts of this area, from before backward, in the order named. It will be noticed that the parts susceptible of the finest and most delicate movements, those directed by the most acute sensations, the lips, the fingers and toes, lie farthest back in the motor area, chiefly in the posterior central convolutions. Lesions in this convolution almost always cause some loss of tactile

Digitized by Google

sensation as well as paralysis, and hence this area is thought to be the seat of tactile sensations as well as of movements; while some cases point to the localization of muscular sensations in the area just behind that of motion.

There are no sharply defined sections of the motor area to be assigned to special motions. Each motion, each part of a limb, has a wide general representation over the cortex, and a special representation at a limited area. Sir Victor Horsley says that the areas of representation of different limbs merge into one another; thus in the representation of the thumb we find that there is a focus, but that the thumb is represented over a great deal of the upper limb region, and that this representation diminishes in intensity gradually as we pass the focus upward. This explains the fact that the excision of a small area does not totally paralyze the portion of the thumb represented chiefly on that area. The adjacent areas represent to some extent that limb, and hence can govern it if need be.

The speech areas are of four kinds and in four locations. They are limited to the left hemisphere in right-handed persons, and to the right hemisphere in left-handed persons. There is the motor-speech area in the posterior part of the third frontal convolution, in which the movements concerned in the act of speaking are controlled. The use of languages and the power of talking are affected when this region is destroyed. There is the auditory speech area in the first and second temporal convolutions, in which the memories of words are stored up. The understanding of language and the power of recollecting the names of objects are lost when this region is destroyed. There is the visual speech area in the lower parietal region in which the memories of printed words are stored up. The understanding of written language and the power to read are lost when this region is destroyed. The power of writing is a part of speech, and is usually lost when the motor speech area is destroyed, but its exact location is not fully determined, some cases pointing to the second frontal convolution, others to the lower parietal convolution near the hand centre, as its probable cortical position.

Digitized by Google

The area of sensation of sight is located in the occipital lobe of the brain, including the cuneus on the median surface, and the occipital convolutions on the convexity. The cortex lying in the calcarine fissure is the part primarily reached by the visual impulses, but the parts named are also concerned in vision. Each occipital lobe receives impressions from one-half of both eyes, hence a lesion in one lobe produces hemianopsia—a half blindness in both eyes, the blind field of vision being on the opposite side of the lesion.

The area of sensation of sound is located in the first and second temporal convolutions of the brain. Each ear is connected with both hemispheres, hence deafness from a unilateral lesion is only partial, and is not generally noticed. But if both temporal lobes are destroyed the patient becomes totally deaf.

The area of sensations of smell and taste is located at the tip of the temporal lobe on its under and inner surface, which rests on the sphenoid bone. Each lobe is related to sensory organs on both sides, and a unilateral lesion does not often produce noticeable symptoms.

There are large areas of the cortex of the brain whose function is undetermined. These are much more extensive on the right hemisphere than on the left. There are no definite symptoms produced, so far as we know, by lesion in these areas; but the negative fact is certain, that lesions in them do not cause disturbances of motion, of sensation, or of speech.

There appears to be a certain relation between the frontal lobes of the brain and the higher forms of intellectual activity—the power of fixing the attention, and of reasoning, and of self-control. But disease here does not cause a loss of any one mental faculty, and for the higher power of the mind a general integrity of the entire brain, not of any one part, is necessary.

The cortex of the hemispheres upon the base of the brain, lying on the orbital plate, on the sphenoid and temporal bones, and on the tentorium cerebelli, has as yet no assignable functions, and lesions in these regions do not produce recognizable symptoms. As to the functions of the centrum ovale, it is known that through this region the great brain tracts pass in various directions. Many

Digitized by Google

of these connect the various areas of the cortex with their respective sensory or motor mechanisms in the base of the brain and spinal cord. Others join the different areas of the cortex with each other, thus bringing about a combination of sensory impressions into a single mental image. Others, again, unite the two hemispheres of the brain with one another, it being certain that symmetrical areas must act in unison on the two sides. The basal ganglia, the corpora striata, and the optic thalami, lying deep within the hemispheres, are masses of gray matter whose function is undetermined.

Lesions in them frequently affect the various tracts which pass between them in the internal capsule, thus cutting off afferent or efferent impulses to and from the cortex, and causing sensory and motor symptoms of the nature of hemianesthesia, hemianopsia, and hemiplegia.

But if disease in the ganglia does not invade the internal capsule, it cannot be detected during life. The crura cerebri, pons, and medulla contain the centres of the various cranial-nerve nuclei, and hence cranial-nerve palsies are caused by disease in them. They transmit motor and sensory impressions to the spinal cord, hence numerous symptoms appear when they are injured. The cerebellum, lying in the posterior cranial fossæ, beneath the tentorium cerebelli, controls the equilibrium of the body; hence disturbances of the nature of staggering and vertigo are produced by lesions affecting it, especially if its median lobe is involved.

These local symptoms of brain disease must form the chief guides to the physician in his diagnosis, and to the surgeon in operations. When they are present they point to a particular area of the organ which must be involved; when they are absent, both neurologist and surgeon are as helpless as they were before any of these facts of localization were determined.

Digitized by Google

CASES OPEN TO OPERATION.

There are many cases in which it is evident that brain disease is present, but in which it cannot be located, because the necessary symptoms to determine its location are absent.

There are other cases in which it is evident that the disease is located deep within the hemispheres, or on the base of the brain, entirely beyond the reach of the surgeon. It is, therefore, evident that in only a limited number of cases of brain disease can operative interference be considered with favor. Operations may be performed for the relief of Jacksonian epilepsy, for the cure of imbecility, for the removal of clots, for the opening of abscesses, for the excision of tumors, for the relief of intracranial pressure, with or without drainage of the lateral ventricles, and for the cure of traumatic insanity.

It has always been recognized, and always will be recognized, that the majority of cerebral tumors are both impossible to find and impossible to cure. All these observations may be true when applied to tumors of the brain, but a much better prognosis may be given in cases of cysts of the brain. After drainage or removal of these cysts the epileptic and other symptoms, local and general, and paralysis, are not infrequently recovered from.

The following is a case in point:

Mr. E. A. H., aged fifty-nine years, gives the following history. His spasmodic trouble began some time in November, 1892. He was standing in a grassy place when his right foot became numb; in a moment the muscles of the leg began to twitch, then those of the thigh, then those of the groin; while the spasm lasted the whole leg danced, and he could not hold it still. This twitching of the muscles was attended with very severe lancinating pains. When the spasm stopped he fell to the ground, faint from pain. It was difficult to estimate the time, but he thinks it lasted two or three minutes, more or less.

In about twenty minutes there was a recurrence, but far less severe. From this time on until the operation in May, 1898,

Digitized by Google

these spasms continued about every ten days with a recurrence, usually the next day, with the exception of some six weeks, when he first came under my treatment, in 1892. Large doses of bromide of potassium seemed to have some controlling influence for a few weeks. In June, 1894, the attacks became more violent, and are thus described by his wife: He became unconscious and remained so for some time, should say an hour or more, throwing himself from the couch to the floor, moaning and frothing at the mouth, his whole body twitching and writhing as if in great agony, his face and hands purple to blackness, his teeth set, eyes rolled into his head; at the last he fell into a quiet sleep which lasted only for a short time; awoke conscious, and epileptic symptoms disappeared. From this time on there was a gradual decrease in the pain and in the twitching of the muscles and a steady loss of their control.

He could not tell when he first noticed the extension of the spasms to the hands, probably early in 1897, possibly earlier. Soon it affected the lips and eyes. For a long time before the operation he could not read, neither could he write, because he could not control his hand. He had so lost control of his leg that he could not tell where it was unless he was looking for it. He was also sensible that his mind was affected and could not trust himself to do any business; in fact, he became so helpless that his wife was obliged to dress him. He was, indeed, in a helpless, and to all appearances a hopeless, condition.

Operation. On May 27, 1898, I operated on Mr. H. at the Maine General Hospital. An opening was made with the trephine over the leg area on left side in front of the fissures of Rolando; this was enlarged upward, downward, and forward, with the rongeur forceps, until a large surface of the brain was exposed. The dura was much thickened and firmly adherent to the inner surface of the skull. There was no pulsation of the brain. The dura was opened and beneath it was a large cyst filled with a thin fluid. The fluid was evacuated, and a gauze drain placed in the cavity; no attempt was made to suture the dura. The scalp wound was closed, leaving room for drainage. The patient made rapid and uninterrupted recovery from the operation. After leaving the hos-

Digitized by Google

pital he continued to improve, and in November, 1901, I received from him the following letter:

LITCHFIELD CORNER, ME., Nov. 6, 1901.

MY DEAR DR. WEEKS: I have had in mind for a long time to send you some word as to my condition, for I am fully persuaded of my great obligation to your skill and kindness, and I know that you have a very great interest in my case. In general there has been a gradual, steady improvement since the operation. Spasms have become irregular and lighter, nearly painless. Have steadily become normal in use of right hand and leg. The same is true as to mind and language. A year ago last spring I began the canvass of Windham for the Bible Society. Began by working every other day, and rode. I grew stronger and began to walk, and so continued from town to town until January. I was then invited to preach in this place for two weeks, and have been here ever since.

There is a slight dragging of the right foot, so that I limp a little ordinarily in walking. But have no discomfort in walking off three or four miles, or even twice that, without stopping. And the exercise seems good for me. What I call "the spasms" are irregular, from one to six weeks apart. If I am lying down or sitting, I do not usually notice it until the hand is affected. If walking or standing, I am aware of a defect in the control of the leg. When it reaches the hand, there is a numbness in the fingers, and a slight sense of the drawing of the cords. This sometimes passes off quickly, sometimes comes and goes for perhaps fifteen minutes. Rarely, nowadays, the lips on one side are affected for a few moments, and the eyes. All symptoms occurred last Sunday morning while I was delivering the sermon. It has not occurred before since I came here, and I was able to continue the service as usual. This kind of spasm is followed by a peculiar headache, not severe, but extremely depressing, which continues until after a night's sleep. It is proper for me to say that I am very happy in this work here, in spite of an assurance that my ability to continue it is extremely uncertain. Once more I wish to thank you with all my heart for giving me, under God, this new lease of service.

Cordially yours, E. A. H.

Digitized by Google

Since November 6, 1901, I have continued my work as a pastor. I continue to be subject to the spasms occasionally, sometimes two or three in a week, sometimes free from them for twelve weeks. My hand and leg are not normal, but they serve me very well, and the spasmodic action seems to harm my mind or ability to work but very little. My general health is very good for one in his seventy-second year.

In October, 1906, Mr. H. came to see me, and I found his condition good. He is able to continue his preaching.

The question of anesthesia during operation on the brain is a very important one. In all of my operations on the brain I have used ether as an anesthetic. I have never made use of intraspinal injection of cocaine. My experience has been confined to general anesthesia. Intraspinal anesthesia is of too limited applicability, because control of the intensity of narcosis is lost. While in London last year I found Sir Victor Horsley using chloroform only. He claims that ether causes, besides a rise of blood pressure, a notable increase of blood venosity, and therefore much additional and troublesome hemorrhage. In its later effects, that is, on recovery, it causes excitement, as well as in many cases notably headache, and, of course, vomiting.

Chloroform, on the contrary, causes a fall of blood pressure, with relatively less blood venosity, although this is by no means absent. It therefore does not aggravate the bleeding nor embarrass the respiration by causing bronchorrhea. By its more essentially paralyzing action on nerve centres it causes practically no after-excitement, but moderate headache. Chloroform is more dangerous, although the danger is much less when administered according to the plan made use of at the National Hospital, Queen's Square, London.

At the National Hospital Sir Victor Horsley uses almost wholly Mr. Vernon Harcourt's apparatus, by which chloroform can be used in known quantities. It has been found that less than 2 per cent. of chloroform vapor in the atmosphere breathed by a patient is enough to produce deep narcosis, and that a much smaller dose is required to maintain unconsciousness to pain.

Digitized by Google

If the mouth of the inhaler be made to fit by wet aseptic towels, the amount of the dose given will be under complete control. With a dose commencing at 0.5 per cent., and rising in one or two minutes to 2 per cent., the patient ought to be ready for operation after five or eight minutes. As a rule, the amount of 2 per cent. is given for about five minutes before the incision of the skin and reflection of the flap, which constitutes the maximal pain period of the operation. This completed, the dose can be lowered, by pushing the tap back, and the bone removed at 1 per cent. As the dura is a sensitive membrane, supplied by the fifth cranial nerve, the dose should be somewhat raised just previous to its incision to prevent reflex starts or movements on the part of the patient. As soon as the dura is opened the encephalon can be dealt with without causing much, if any, pain. Consequently all this part of the operation is done under less than 0.5 per cent. of chloroform in the air respired, an amount which, of course, is far below that required in the first stage of the operation. After the brain lesion is dealt with the percentage should be raised to about 0.7 or even to 1 per cent. during the insertion of the sutures in the skin. This percentage is continued to the commencement of the dressing to prevent vomiting.

In all operations on the brain it is important to prevent, as far as possible, the loss of blood. To this end it is necessary that every bleeding artery should be secured by ligature, and on this point we cannot too strongly emphasize the advice of von Bergmann, that it is very unsafe to trust to tampon pressure. It is remarkably easy to arrest capillary oozing and arteriole oozing from the brain by the simple means of hot irrigation. To quote the words of Dr. Milne Murry, who, from his experiments, came to the following conclusion: "It is certain that water from 70° to 103° or 105° F. will invariably dilate bloodvessels and promote the flow from open ones; but it is equally certain that water of a temperature from 110° to 120° F. will have just the opposite effect. The temperature of the fluid should not exceed 115° F., and should not fall below 110° F. If a large irrigator be used, it is an easy thing to keep the fluid at the desired temperature on account of its mass, and it is gratifying

Digitized by Google

to see the oozing gradually cease during the steady flow from the irrigator 'hose' pipe."

It is, I think, to Sir Victor Horsley that we are indebted for the idea of using oxygen, in connection with chloroform, to control venous and capillary oozing. During the administration of chloroform there is gradually induced a moderate degree of asphyxia, which has the effect of raising the venous pressure. The fact is plain, and consequently all that is to be done to lower the venous pressure and stop the oozing is to get rid of the asphyxial condition. Says Sir Victor Horsley: "Although it is impossible to improve promptly the action of the respiratory centre itself directly, or the respiratory movements of the patient, and so lower the venous pressure, it is easy to raise the percentage of oxygen in the anesthetic atmosphere breathed, by directing a stream of gas through the air inlet of the Harcourt regulator, and so quickly abolish any asphyxia. It is interesting to see how rapidly the bleeding stops as the color of the oozing blood changes from dark purple to a bright scarlet." This arrangement is in use at the National Hospital, Queen's Square, London, for anesthetization and oxygenation of the patient. The Vernon Harcourt regulator is fixed in the conical stand, the chloroform bottle being in a water-bath. The oxygen supply from the horizontal cylinder is readily regulated by the anesthetist. Professor Theodor Kocher, of Berne, stands at the right of the photograph. (See illustration.)

An important question arises, namely, When should medical treatment be given up and surgical treatment substituted? The same question was raised again and again, and warmly discussed in connection with appendicitis, until now the profession is pretty well agreed that appendicitis is surgical from the first. When our powers of diagnosis become more perfected, surgical treatment of the various diseases of the brain will not be considered a "last resort." At the International Medical Congress, held in Berlin in 1890, Sir Victor Horsley proposed that in cases of Jacksonian epilepsy and other syndromata which suggested the existence of grosser organic disease of the brain, a definite probationary period of medical treatment should be agreed upon, and that in an ele-

Digitized by Google



Digitized by Google

mentary case, where no urgent symptoms like optic neuritis existed, surgical treatment should be employed after thorough drug medication had been energetically applied for about six or eight weeks and cure had not appreciably resulted.

Dr. Allen Starr, in his well-known work on *Brain Surgery*, formulated the conclusion that the surgeon should be invited to consultation in the case after about three months' medical treatment had been unsuccessful. Such a course is, in general, the practice at the National Hospital, Queen's Square, London. In 1906, Sir Victor Horsley was asked to operate on a patient with lateral tumor of the cerebellum who had been known to have optic neuritis for nine years, and did operate on such a patient who had been known to have optic neuritis for thirteen years.

Intracranial disease is liable to produce optic neuritis, which usually ends in total blindness. It is now well settled that optic neuritis is due to the intracranial tension, and is amenable to surgical treatment. In no case of optic neuritis should the process be allowed to continue after it has once been diagnosticated, and if blindness results therefrom the responsibility is very heavy on anyone who fails to advise such a simple proceeding as opening the dura mater.

Touching the subject of the neuritis, I quote from a paper by Sir Victor Horsley, read at the meeting of the British Medical Association, held in Toronto, August 21 to 25, 1906. "The gravity of this responsibility does not seem to be generally recognized, and it is owing to this, as well as the backward state of neurological diagnosis, that melancholy cases such as the following occur: A. B., lady, married, developed symptoms of cerebral tumor with acute optic neuritis, and was told by a neurologist that nothing could be done surgically. Subsequently, after some treatment with iodides, the neuritis subsided into complete atrophy and blindness, while the cerebral lesion gradually retrogressed. When the patient came under my observation in the spring of this year, her physical condition was apparently perfectly normal except the permanent loss of sight. This calamity would have been wholly avoided by operating to relieve the optic neuritis, even if nothing further had been attempted to deal with the lesion itself."

Digitized by Google

To sum up, then. During the past twenty years we have learned that although the old procedure of de Vicker, of incising the swollen sheath of the optic nerve in the orbit, is of no avail, we can with certainty avert blindness by opening the subdural space early, in cases of intracranial disease; preferably in the basal temporal region of the right side, that is, assuming that no attempt is made to attack the disease itself. One other fissure should be mentioned, the fissure of Bichat, pointed out by Broca. This fissure is between the cerebrum and the cerebellum, and corresponds to a line drawn from the external occipital protuberance to the external auditory meatus, and marks the position and direction of the lateral sinus. In operations on the cerebellum, the opening must be made below this line. Tumors of the brain, collected by Starr and various other authors, show that in order of frequency they stand about as follows: Tuberculous gumma, glioma, cysts, carcinoma, syphilitic gumma, with a small proportion of fibroma. In all probability gummas, either of tuberculous or syphilitic nature, are much more frequent than all the other varieties put together.

Until within a few years tumors within the cranium were regarded as having great pathological interest, as affording opportunity for brilliant diagnosis, but as so essentially hopeless that but little attention has been given to this feature of the therapeutics or operative relief. Interest in the subject was increased by discoveries in the field of cerebral localization, and as the result of greater exactness in diagnosis and greater experience in experimental surgery upon the lower animals, and by more experience in operative surgery upon the human subject, it has been found that a certain proportion of them are amenable to surgical treatment, with a reasonable degree of success and safety. The brain is no longer a terra incognita, nor is it now a sanctum which none may enter or explore.

There is good reason to believe that with greater accuracy of anatomical and physiological knowledge, which shall permit more accurate localization of lesions, we may go farther with success than we have yet dared to go. In all operations on the brain

Digitized by Google

every precaution should be taken to protect the patients against shock. Shock and sepsis are practically the only causes of death which can be provided against during surgical operations. In 1893, at the discussion in the Surgical Section of the British Medical Association at Newcastle, Sir Victor Horsley pointed out that the early statistics of intracranial operations showed that the majority of deaths occurred from a severe degree of shock, which could be, in great part, avoided by dividing the operation into two stages, the interval between them being about five days. The first stage consisted of the opening of the skull; the second, of opening the dura mater and the removal of the lesion. On the same occasion he also called attention to the fact that although at the second stage the dura mater was opened, the removal of the tumor was often attended by relatively little shock. Subsequent experience has fully confirmed these statements, and shown that it is in fact the opening of the skull which causes most general depression of nerve energy and greatest alteration of the circulation.

Sepsis is another cause of death which should be guarded against during and after surgical operation on the brain. It has always been recognized, and long before Lord Lister's immortal discovery of antiseptics explained why, that the cavities of the body presented special risk to septic infection. Nowadays, when many surgeons can show an unbroken record of successful operations for the radical cure of hernia, or for appendicitis in the quiescent stage, I believe it is not fully realized how very different should be our estimate of the susceptibility of the central nervous system to invasion by septic microörganisms, and of the extremely feeble degree of its resisting powers. With these important facts in view, the surgeon should use every possible precaution to protect his patient from this danger. In all operations requiring drainage it should be remembered that so long as the cerebrospinal fluid continues to escape, the most vigorous disinfection of the skin and frequent changing of the dressing must be carried out, for not only so long as the cerebrospinal fluid is flowing is there great danger of septic invasion, but the difficulty of closing a drainage is increased the longer the cerebrospinal fluid passes through it. Says Sir Victor Horsley: "I feel inclined to reassert the view, expressed in

Digitized by Google

1906, that the less drainage is employed the better, and consequently that every effort should be made to close the skin wound as early as possible."

CONCLUSIONS.

1. There are two essential preliminaries to any operation on the brain: the first is the diagnosis of the nature of the disease which is present, and the second is the diagnosis of its location.

2. The most important landmarks upon the surface of the head, by which certain motor and sensory areas are determined, are the fissure of Rolando, fissure of Sylvius, the parietoöccipital fissure, and the fissure of Bichat.

3. It has been determined by recent experiments and observations that the motor area is largely in front of the fissure of Rolando, and the sensory area is largely behind this fissure.

4. Each hemisphere controls movements on the opposite side of the body, but as the right hand is more generally used and is better trained than the left, this area is larger on the left hemisphere than on the right. The speech areas are limited to the left hemisphere in right-handed persons, and to the right hemisphere in left-handed persons. The speech areas are of four kinds: the motor speech area, the auditory speech area, the visual speech area, and the power of writing, which is a part of speech, and is usually lost when the motor speech area is destroyed; but its exact location is not fully determined.

5. Operations may be performed for the relief of Jacksonian epilepsy, for the cure of imbecility, for the removal of clots, for the opening of abscesses, for the excision of tumors, for the relief of intracranial pressure, with or without drainage of the lateral ventricles, and for the cure of traumatic insanity.

6. Tumors of the brain, collected by Starr and other authors, show that in order of frequency they stand about as follows: tuberculous gumma; glioma; cysts; carcinoma; syphilitic gumma, with a small proportion of fibroma. In all probability gummas, either of tuberculous or syphilitic nature, are much more frequent than all the other varieties put together.

Digitized by Google

7. The question of anesthesia in brain operation is a very important one. My experience has been limited to general anesthesia. I have never made use of intraspinal injection of cocaine. Sir Victor Horsley uses chloroform altogether. He claims that ether causes, besides a rise of blood pressure, a notable increase of blood venosity, and, therefore, much additional and troublesome hemorrhage. Chloroform, on the contrary, causes a fall of blood pressure, with less blood venosity. Sir Victor uses Mr. Vernon Harcourt's apparatus, by which the chloroform can be used in known quantities. The dose can be regulated by the movement of a hand or tap. During the administration of chloroform there is generally induced a moderate degree of asphyxia, which has the effect of raising the venous pressure, with an increase of oozing of blood. To relieve the asphyxia which causes the oozing, a stream of oxygen gas is directed through the air inlet of the Harcourt regulator, which quickly relieves the asphyxia. The oozing of blood quickly stops as the color changes from dark purple to a bright scarlet.

8. Intracranial disease is liable to produce optic neuritis, which usually ends in total blindness. The optic neuritis is due to intracranial tension, and is amenable to surgical treatment. In no case of optic neuritis should the process be allowed to continue after it has been diagnosticated. Blindness can be averted by opening the subdural space early in cases of intracranial disease. This operation can be best done in the basal temporal region of the right side, assuming that no attempt is made to attack the disease itself.

9. Shock may be in great part avoided by dividing the operation into two stages, the interval between them being about five days.

10. To avoid the danger of septic invasion, which is greater in operations on the brain and spinal cord than in operations involving the abdominal cavity, the less drainage is employed the better, and consequently every effort should be made to close the skin wound as early as possible.

BIBLIOGRAPHY.

Starr's Brain Surgery.

Sir Victor Horsley's Address before the British Medical Association, Toronto, August, 1907.

Digitized by Google

A CASE OF MULTIPLE CARCINOMATA FOLLOWING CHRONIC X-RAY DERMATITIS.

By C. A. PORTER, M.D.,
BOSTON,
AND
C. J. WHITE, M.D.,
BOSTON.

THE recent death of Professor Fuchs, of Chicago, from metastatic *x*-ray carcinoma, leads me to report in detail the history and present condition of another case of multiple epithelial carcinomata which has been under my care since 1897.

In delaying this report until the present time I have been greatly influenced by my personal regard for the patient; but the above case, the fourth fatal one in the United States, and a slowly increasing list of undoubted instances of *x*-ray carcinoma, here and abroad, make it imperative that the attention of dermatologists and surgeons should be thoroughly aroused to the great *danger of all persistent x-ray ulcerations*, and especially to those which have followed, with a few years' interval, the chronic skin lesions of the earliest operators.

The first published account of the injurious effects of the *x*-rays with which I am familiar was a paper by Marcuse, "Dermatitis und Alopecie nach Durchleuchtung mit Röntgenstrahlen," in the *Deutsche med. Wochenschrift*, 1896, Nr. 30.

From 1897 the literature of this subject has grown each year. The earlier articles dealt with the immediate effects of the *x*-rays, dermatitis and burns; then it soon became recognized that these lesions were most excruciatingly painful and extremely slow to heal; further experience showed that some lesions closed with

Digitized by Google

great difficulty, only to break down again and again, and finally formed chronic ulcers; then came the first report of cancer developing in a chronic ulcer, and, finally, the first death from metastatic carcinoma.

In an excellent article written by Dr. Richard Mühsam, and published in the *Archiv f. Klinische Chirurgie*, 1904, Nr. 74, "Ueber Dermatitis der Hand nach Röntgenstrahlung," may be found a full bibliography of the literature up to that time and a brief resumé of the histology of the characteristic lesions with which we are, unfortunately, too familiar.

CASES OF X-RAY CANCER.

I and II.—In 1903, Sick reported two cases, both in *x*-ray operators. The first, after years of severe changes in the skin of the arms, neck, and face, finally developed an ulcer upon the back of the hand, which soon took on the typical appearance of a carcinoma, and required amputation at the shoulder-joint.

The second, with similar skin lesions of six years' duration, also developed a chronic ulcer on the hand which was excised, and showed, upon microscopic examination, the typical picture of a skin cancroid, with cancer nodules in the cutis; the material from these cases was examined by Unna.

III.—Dr. Blacker, of England (mentioned in the *New York Medical Record*, October 22, 1904), for a long time suffered from an *x*-ray burn of the hand, which was neglected, until the cancer which had developed had extended up the arm and involved the axillary glands, when it was too late for operation.

IV.—Clarence Daly, Edison's assistant (personal communication from Dr. Samuel Lloyd, of New York, and Dr. W. B. Graves, of East Orange, N. J.). This patient was very seriously burned on both hands years before, in working with *x*-ray tubes. He was treated at many different hospitals. Skin-grafting was tried without result, until, finally, epithelioma developed on the right hand and on the base of the little finger of the left hand. At the time of Dr. Lloyd's first examination the right hand was infiltrated

Digitized by Google

with carcinoma and the axillary glands were involved. On August 8, 1902, the arm was amputated at the shoulder-joint and the glands above and below the clavicle removed. Amputation of the left hand was advised, but refused. The ulceration on the left hand gradually increased in size and depth, and the left arm was amputated by Dr. Graves on March 16, 1904. Death followed from mediastinal recurrence in October, 1904.

V.—Epithelioma of finger in hand of *x*-ray machine manufacturer (communication from Dr. Lloyd).

VI.—(Personal communication from Dr. W. B. Coley, surgeon, of Rochester, N. Y.). For five years had been using *x*-rays continuously. Ulcerations present for six months on the backs of both hands, specimens from which were examined by Dr. Welch, and found to be undoubted epithelioma. Amputation of right hand above wrist and thorough excision of ulceration on left hand, October 10, 1904. Subsequent recurrence in axilla and death.

VII.—Bertha F., San Francisco, Cal., death. Quotation from *New York Sun*, April 24, 1907.

VIII.—Foulerton's case (*Lancet*, May 6, 1905). At a meeting of the Pathological Society of London, Foulerton reported the case of a surgeon who began systematic work with the *x*-rays in 1897. In May, 1903, had a severe attack of dermatitis, blistering of the skin on back of index and middle finger of left hand, ulcers resulting healed in about four months. New skin was thin and tender and showed nevoid-looking petechiæ. The nails fell out and new ones were hard and brittle. In December a second attack of dermatitis again caused ulcers on the first and second fingers. Ulcers on index finger remained open, and in April, 1904, began to assume a malignant character. In September of that year the finger was amputated at the metacarpophalangeal joint. Sections of index finger showed typical squamous-celled cancer.

IX.—(Personal communication from Dr. L. L. McArthur, of Chicago, dated April 26, 1907.) Professor Fuchs was the first photographer to develop *x*-ray plates in America. "He early developed the chapped and fissured hands which go with the

Digitized by Google

exposure to the ray, *especially* in those who combined the development of their plates with their *x*-ray work. For the last three years he has been having, from time to time, minor surgical procedures in the way of removal of a phalanx now and then, until three fingers of the right hand and two on the left had been sacrificed.

After various plans of local treatment and a trip to Europe in search of remedial agents, he came to me for the first time with an enormous axillary involvement. This was indubitably squamous-celled carcinoma. The radical operation with removal of portions of the pectorales and a dissection of the axilla en bloc failed to effect an arrest of the trouble. Recurrence took place very promptly, and within three months again filled the axilla and involved the supraclavicular glands. Deeming it hopeless to subject him to further surgical interference, trypsin injections were given, with a resulting liquefaction of the axillary mass to a non-purulent, serosanguinolent fluid, containing immense masses of epithelial cellular detritus, as was shown on opening and draining the same. After lingering for six weeks he finally succumbed to a multiple metastasis on April 23, 1907.

"The second case was that of a physician who combined his electrical therapuetics from his static machine with the taking of pictures of his surgical cases. He, too, developed his own plates, and constantly had his hands stained with the photographing solutions. He had the usual history of a chronic dermatitis with ulcerative processes that refused to heal, and required removal of the terminal phalanges on his left index and middle fingers. When he came to me it was with a typical epithelioma on the remains of the left index finger, and numerous senile keratoses on the back of both hands. I amputated the finger, which microscopic section demonstrated to be carcinomatous. I removed, by a deep, shaving-like cut, the senile keratoses and grafted the same. I secured primary union in the grafts, had a mild infection along the stitch line in the amputation, and an aseptic result in the axilla, which I cleaned out radically, although no glands were distinctly palpable at the time of the operation. No metastases were found in those

Digitized by Google

lymph glands removed from the axilla which were examined. At present he is in good health."

From a careful search through the literature and some personal inquiry these 10 cases of undoubted *x*-ray cancer are all which I have been able to find. I have purposely excluded a few recorded cases of carcinoma developing in lupus tissue after Röntgen treatment and one or two cases of epithelioma, following burns, for I wish to limit the question under discussion to cancer resulting in the *x*-ray operators who for years have followed their work in spite of previous inflammations of the skin and persistent lesions.

If my case be included, there are 11 cases, of which 5 have proved fatal, and as 1 of Sick's, reported in 1903, had to submit to a shoulder-joint amputation, it is probable that this result was also a fatality. The prognosis in *x*-ray cancer would, therefore, appear appalling if it were not for the very great likelihood that all fatal cases have been published, while no record has been made of the much larger number of sufferers who, after excisions or minor amputations, have as yet shown no evidence of recurrence. Although it is obvious that surgeons will very naturally hesitate, in the case of a brother physician, to add publicity to misfortune, there are so many unfortunates throughout the country suffering from chronic lesions of all grades of severity, that it is now a duty, I think, for all who have charge of these cases to publish their experiences, in order that our knowledge of this difficult subject may be increased.

The case which I have to report is that of an *x*-ray operator, who, as a *young man*, first began *x*-ray work with a large static machine in March, 1896; after October of the same year a powerful twelve-inch coil was used. Exposure lasted for several hours each day, at a very *short distance* from a *low vacuum* tube. About the middle of November hands became red and dry, and in a few days very painful and greatly swollen. Under "black wash," the dermatitis subsided, but the finger nails first became dry and striated, then softened, and finally sloughed off (the patient felt convinced that this condition of the nails was greatly aggravated by the use of chromic acid in development of the *x*-ray plates). In spite of the

Digitized by Google

fact that 1 per cent. iodoform ointment had to be used almost continuously to relieve the intense pain, work was continued until April 1, 1897, when the onset of another very severe dermatitis, with the formation of enormous blisters, and pain "beyond de-

FIG. 1.—Ring finger with cancerous ulceration removed July 17, 1902.

scription," necessitated ward treatment for a month. "White wash" gave considerable relief. All forms of treatment by ointments, powders, and washes, which Professor J. C. White could

FIG. 2.—Section of same finger under a low power.

suggest, proved useless; the chronic ulceration, which now involved most of the backs of the fingers of both hands, refused to heal. Orthoform ceased to relieve the pain. At the suggestion of the patient, Riverdin grafts were applied on July 10, 1897, to the

Digitized by Google

tip of the left forefinger, which presented the appearance of a sluggish ulcer, with rather exuberant granulations and unhealthy looking edges. These pinpoint grafts "took" and grew. Accordingly, on August 13, 1897, under ether, all the ulcerated areas were cleaned up, shaved down to an apparently normal base, and Thiersch grafted, fourteen different grafts being applied. Contrary to all expectations, the great majority of these grafts adhered,

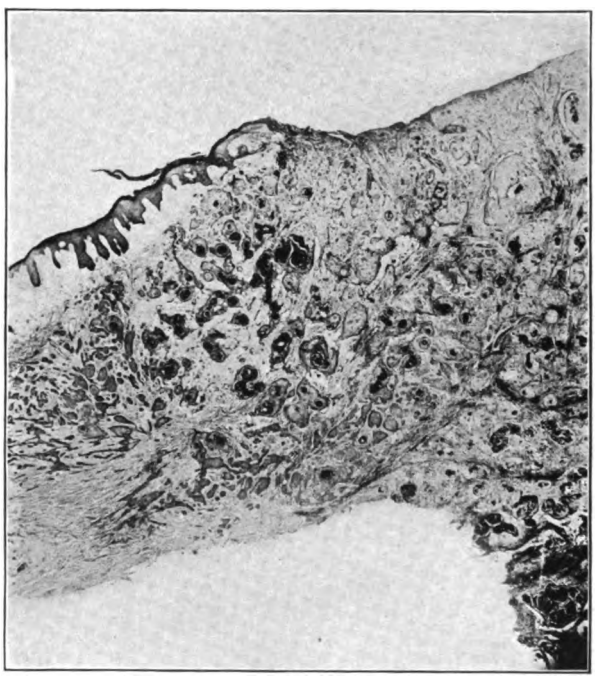

FIG. 3.—Section of same under high power, July 17, 1902.

and "*have never broken down since*, nor do they show the eczematous condition which now exists on the areas not grafted." "Pain ceased absolutely from the time of operation, and areas then grafted are in good condition today." "Epithelioma has *never* developed in any graft which *completely took* at this time." (I quote from a letter which the patient wrote me in 1905.)

Though all *x*-ray work was stopped for a year, ulcers developed

Digitized by Google

upon the fingers; and again, in spite of all treatment, refused to heal until excision, with skin-grafting, was carried out. After several operations all the chronic lesions were successfully grafted or healed spontaneously, except some very persistent ulcers on the ends of the ring fingers of both hands, and the little finger of

FIG. 4.—Condition of hands June, 1905.

the right hand, which, in spite of six or seven operations, refused to heal.

In July, 1902, the persistent ulcerations at the tip of the ring fingers were again excised and grafted. The grafts did not take. The specimens sent to the pathologist were misplaced and not until October, 1902, was the report received that both ulcerations showed

Digitized by Google

unmistakable evidence of carcinoma. In the meantime these finger tips had become excessively sensitive and painful and showed an angry looking ulcer with somewhat raised and indurated edges. On or near October 31, 1902, both of the ring fingers were amputated at the knuckles.

FIG. 5.—Condition of hands June, 1905.

1. The ulcer on a ring finger is shown in Fig. 1.
2. The gross appearance under a low power in Fig. 2.
3. The microscopic picture in Fig. 3.

During the period from October, 1902, until June, 1905, a dozen or more operations under ether were performed: amputation of the middle finger of the left hand, removal of the tips of the second and

Digitized by Google

third fingers of the right hand, and numerous excisions of keratotic areas or chronic ulcerations on the dorsum of the remaining fingers or backs of the hands.

Figs. 4 and 5 show the condition of the hands. In June, 1905—for the first time in eight years—the patient was free from pain, and no dressings had to be worn. Both hands could be placed in his trouser pockets. The left hand was soundly healed; the right showed one superficial ulceration at the base of the third finger, with considerable thickening of the skin about it and numerous other keratotic areas. Unfortunately, during the summer this favorable condition did not endure; but steadily, although slowly, several places on both hands began to break down. Under date of November 8, 1905, the following notes were made: For three months, following a slight bruise, and subsequent infection, there has been a great deal of pain in the tip of the stump of the little finger on the right hand, gradually an ulcer has formed about the size of an old-fashioned three-cent piece, which looks very angry and resembles those found at the ends of the fingers in 1902. Figs. 6 and 7 show the condition.

At operation the end of the little finger was removed and a suspicious ulceration at the base of the third finger thoroughly excised. The back of the forefinger over the second phalanx showed a superficial, unhealthy looking ulceration, which involved the old graft; on the ulnar side of this finger were several macerated warts, which had been excessively sensitive and painful. On the radial side were numerous cracks and fissures, with some keratoses, but nothing suggesting anything malignant. All these lesions were excised, as were seven other places on the back of the hands, and Thiersch grafts were applied. All of these grafts took except those on the back of the forefinger, which sloughed and left exposed the white and glistening, but not necrotic, aponeurosis of the extensor tendon. Dr. Wright's examination showed that the ulcer on the end of the little finger was not malignant, but that the specimen removed from the base of the third finger was a typical epithelioma. One or two others suggested beginning cancerous degeneration.

Digitized by Google

During the winter and spring of 1906 these areas broke down farther, and the middle joint of the first finger, from sloughing of the extensor tendon, became flexed and discharged synovial fluid. For a time there was some infection, but this soon passed away.

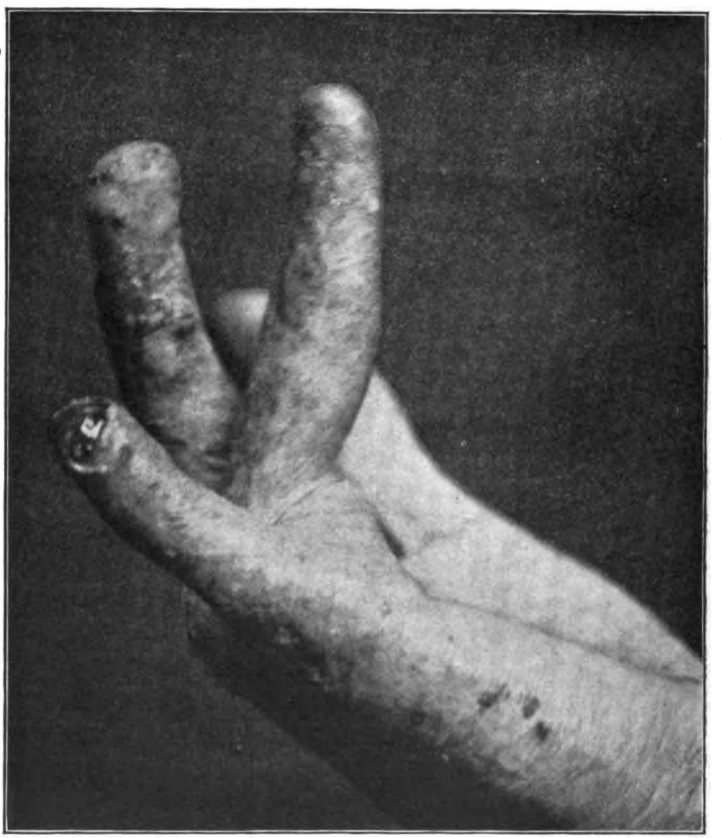

FIG. 6.—Note ulcer on little finger, which proved non-malignant, November 5, 1905.

During the summer the patient suffered much from this persistent ulceration. The back of the middle finger also began to break down.

On November 4, 1906, the ulceration and unhealthy granulations on the back of the first finger were again excised. Examina-

Digitized by Google

tion by Dr. Wright of frozen sections showed epithelioma, or at all events invading epithelium—accordingly the excision was extended into apparently sound tissue at the margins, and the base was removed down to the bone. The dorsum of the third finger was thoroughly scraped with the knife; the tip of the little finger of the left hand removed for persistent ulceration, and several suspicious areas excised. All open surfaces were grafted successfully except the backs of the second and third fingers. A subsequent report from Dr. Wright confirmed his diagnosis of superficial

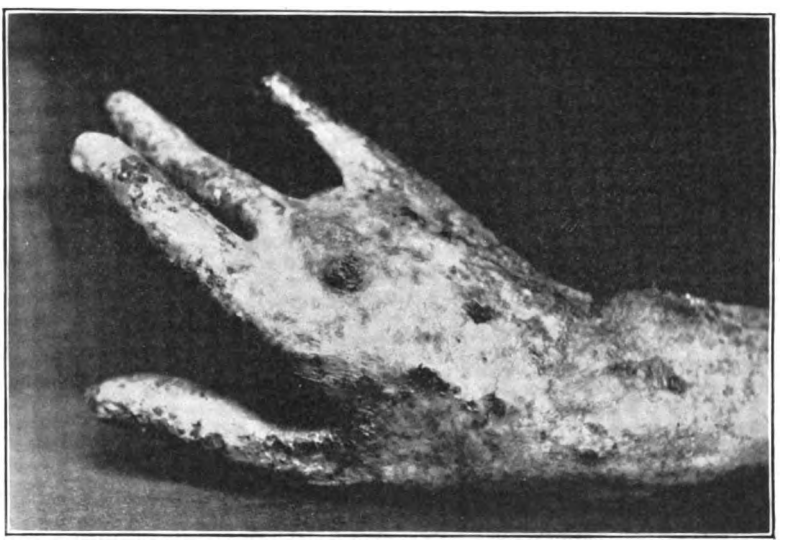

FIG. 7.—Ulcer on little finger and epithelioma on back of hand, November 5, 1905.

epithelioma in the tissue removed from the back of the forefinger; the ulceration of the third finger was negative.

By January 1, 1907, there was some evidence of healing from the edges, in both ulcerations. The patient wished very much to delay radical treatment of the first finger, for, as the third finger was stiff, amputation meant almost total disability of the right hand.

The condition of the hands on April 25, 1907, is shown in Figs. 8 and 9—*the result of ten years of treatment and twenty-five operations under ether.*

Digitized by Google

On the left hand the thumb is sound and serviceable. The forefinger is stiff, but shows no lesions. The third and fourth fingers have been amputated. The little finger lacks a terminal phalanx. On the back of the hand there are a few keratoses, but no ulcerations. *On the right hand* the thumb is useful, but at its

FIG. 8.—Condition of hand April 25, 1907. Grafted areas are outlined.

base is a small ulceration, and the whole ulnar side is covered with thickened epithelium. The forefinger is flexed and presents an ulceration over its middle which is undoubtedly malignant. (This finger will be amputated before June.) The middle finger is stiff. There are a few sluggish granulating areas on the dorsum, but these are healing in. The fourth finger is lacking, as is also the

Digitized by Google

end of the fifth. There are numerous keratoses, but no other ulcerations on the back of the hand.

The palmar surface of both hands is normal. The skin grafts, which are outlined in black, are soft, movable, and some of the thicker ones have almost the appearance of normal skin.

FIG. 9.—Condition of hand April 25, 1907. Grafted areas are outlined. Note epithelioma on forefinger.

The axillary glands have been somewhat enlarged for many years, but show no evidence of increasing size.

From the first demonstration of epithelial cancer in 1902 on the tips of the fourth fingers, undoubted malignant degeneration has been found in eight other areas, so that we have the extraordinary development of ten different epitheliomas in one case in five years.

Digitized by Google

As the report by Dr. White will show, from such a condition there are all grades of what might be termed precancerous changes, down to simple ulceration or benign keratosis. In this, as in the other reported cases, persistent ulceration has for a time—from three to six months—always preceded cancer.

FIG. 10.—Showing condition of hand of J. G. ten days after operation, May, 1906. Note absence of lesions at base of third finger, where ring was worn during early exposures.

In addition, I will report a second case of chronic but much less severe dermatitis, to show the advantage of skin-grafting for recurring fissures, and the report of Dr. Mallory upon the recurrent growth which may prove to be a sarcoma.

Mr. J. G., *x*-ray operator, has suffered for many years with the

Digitized by Google

milder varieties of *x*-ray lesions, such as atrophy of the sweat glands, more or less persistent eczema, marked atrophy and longitudinal ribbing of the finger nails, with the characteristic *x*-ray telangiectasis and keratosis. During the winter most painful fissures occurred over the extensor surfaces of the joints. It is of interest to note that none of these lesions are present over the proximal phalanx of the ring finger, which was protected from all early exposures by a broad gold ring.

In May, 1906, the keratoses and fissures on the back of the right hand were excised and grafted. Fig. 10 shows conditions ten days after the operation. All of the grafts took. These were prominent and raised above the surface for a month, but at the end of that time were level with the surrounding skin, and remained solid until September 15, when a spot on the terminal phalanx of the ring finger became ulcerated. Under gas and ether, on October 18, this ulceration was freely excised and the radial fourth of the nail, with its matrix, extirpated. The skin at the margin of the nail was approximated with plaster and another graft applied. In ten days the wound was completely healed and free from pain. This finger remained painless and healed until the middle of March, 1907, when the distal part of the graft on the radial side began to increase in size and show well-marked vascularity. After two weeks there was a slight discharge near the edge of the nail.

Examination by Dr. Wright of this specimen led him to make a diagnosis of spindle-celled sarcoma; although by some the growth was thought to be a granuloma.

By April 23, 1907, the growth had become decidedly larger, and was apparently extending backward into the proximal graft. (See Fig. 11.) After careful consideration of the possibility of the return of the growth excised in October, but chiefly influenced by the anatomical conditions, which could not, in all probability, be rectified by removal of the nail and grafting, the terminal joint was amputated under gas and ether. The wound was completely healed in a week. The report of Dr. Mallory on this specimen is as follows:

"Tissue from finger of J. G., following exposure to *x*-rays.

Digitized by Google

"The section shows an oval, cellular mass of tissue partially surrounded by more or less normal, fibrous tissue. The cellular mass at its outer end is ulcerated and covered with fibrin, cells, and dried necrotic tissue. The more normal tissue is covered with epidermis. The oval, cellular mass of tissue is quite sharply defined and is

FIG. 11.—Recurrent growth for which amputation was done, April 23, 1907.

limited by a layer of dense, fibrous tissue. It is composed of rapidly growing connective-tissue cells and of a small number of thin-walled bloodvessels. The connective-tissue cells are typical, that is, they have flat, oval nuclei and contain one to three coarse chromatin masses. The cytoplasm is made out with difficulty. In places the cells are bordered by very delicate fibroglia fibrils.

Digitized by Google

Everywhere the cells are separated from each other by a relatively large amount of ordinary collagenous fibrils. The cells and their fibrils tend to form small bundles, which run in all directions. Mitotic figures are numerous, one to three showing in nearly every oil-immersion field. While the cellular mass of tissue at its base is sharply defined, on both sides, it gradually blends with the adjoining connective tissue.

"The adjoining tissue of the finger shows infiltration with numerous groups of lymphocytes. Otherwise there appears to be no change in it. It is difficult to give a positive diagnosis in this case. The rapidly growing mass of connective tissue may be either an unusual form of reparative action, on the part of connective tissue, or it may be a connective tissue new-growth, namely, a rather slow-growing, spindle-celled sarcoma. Personally, I favor the former view, owing to the lack of any definite evidence as yet of invasion.

"F. B. MALLORY."

The microscopic appearances under the low and high power are shown in Figs. 12 and 13. Note the beginning of the epithelial infiltration at the extreme right of the photograph.

During my long experience with the first case I have learned many things about skin-grafting, and now have no hesitation in recommending it as the best treatment for all chronic *x*-ray lesions. Early in the history of this case the tissues were remarkably vascular. There frequently occurred little hemorrhages in the skin, which were often the starting-point of subsequent ulceration; there appeared to be an almost complete vasomotor paralysis. Owing to the chronic eczema no adequate disinfection was possible, so that most of the early operations were somewhat influenced by sepsis; yet, in spite of this, the grafts often took surprisingly well. Hemorrhage proved to be most troublesome, not only at the time of operation, but subsequently, when blebs would form under the grafts, and unless speedily snipped with scissors, would detach them. Hemorrhagic infiltration of the grafts was often noticed on the second or third day, doubling their thickness.

As a rule, I applied a finger tourniquet before excising, as much

Digitized by Google

of the work had to be done with great care, especially when dealing with a suspicious ulceration over an aponeurosis or tendon sheath. Fortunately, no deep infiltrations have yet occurred. After excision, firm pressure by gauze was applied to the raw surfaces for ten minutes, and the hands were then exposed to the air and held aloft. No grafts should be applied until all bleeding has ceased. So far as possible an attempt should be made to bevel the edges of the wound. After shaving off granulations, in order to get a smooth surface, the base of the wound is next examined for vascularity, in order to

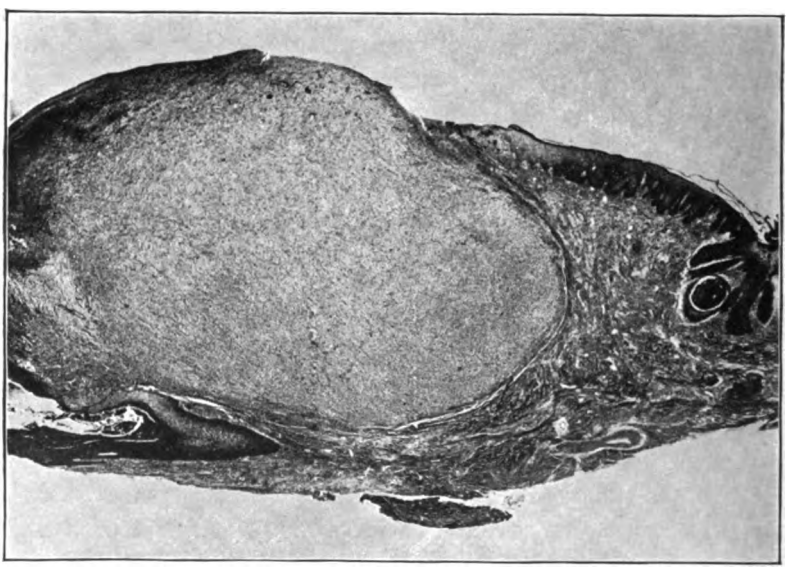

FIG. 12.—Section of growth seen in figure under low power.

determine the thickness of the graft, which should be used. While the ultimate result, if successful, which a thick graft gives, is most desirable, I feel sure that I have occasionally jeopardized healing by attempting to place a thick graft upon a very small spot, or upon such bloodless tissues as the backs of the fingers. I now use thinner grafts. If these fail, another operation should be done when the surface has become covered with granulations. A very small spot upon the fingers is most difficult to graft. I have had the best results by cutting a special graft for each place, thickest in the

Digitized by Google

middle and gradually thinning toward the periphery, in order that it may fit evenly into the concavity of the wound. When possible, the whole forearm is firmly fixed with adhesive plaster to a well-padded palmar splint before any of the grafts are applied. More than once, from a sudden movement of the patient or an assistant, many of the grafts have been brushed off. The patient should be kept under full surgical anesthesia until the dressing is completed. After having tried all the methods of dressing the grafts with

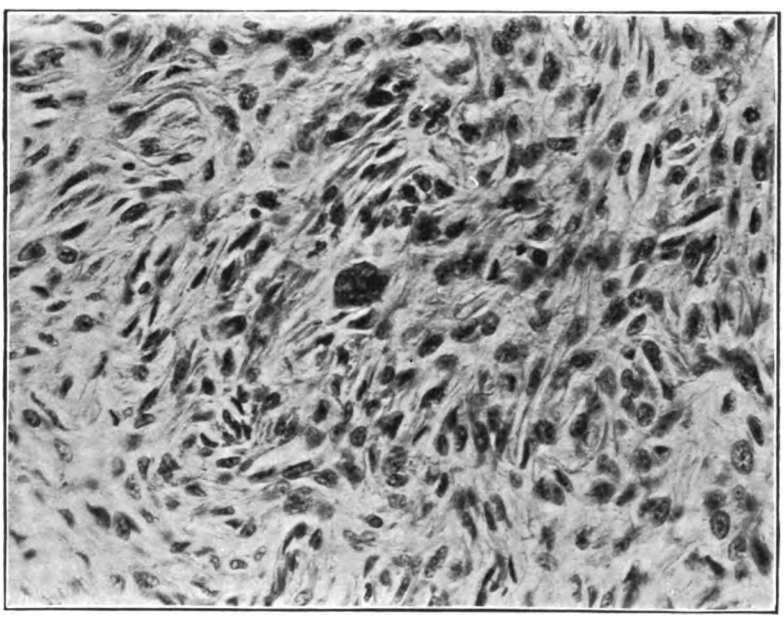

FIG. 13.—Same as Fig. 12, under a high power.

which I am familiar, I have adopted the following technique and after-treatment: The grafts are so cut and arranged that they *do not overlap* either the edges of the wound or each other. If on the back of the hand, they are covered with a piece of rubber protective tissue, which extends not more than one-eighth of an inch beyond their edge; if on the fingers, narrow strips of protective, arranged in an imbricated fashion, encircle two-thirds of the finger, and are stuck in position with blood, which soon coagulates. A

Digitized by Google

small absorbent gauze pad is then placed over the protective, and then *direct downward* pressure is applied by a piece of gauze or bandage, which is tied with a surgeon's knot on the palmar side of the splint. I was forced to resort to this maneuver by the discovery that the smaller grafts now and then were carried from left to right by the ordinary application of the bandage. Owing to the amount of exudation which occurs immediately after the operation, I have found it unwise to adopt immediate exposure to the air, as is now customary in *normal* skin-grafting. After twenty-four hours, with the hand continuously elevated, the protective is carefully removed. Longer delay in this case has almost always been followed by maceration of the grafts.

At the first dressing, blebs, if present, are snipped with the scissors and their contents gently expressed. Any lateral movement of the graft must be avoided. All the *edges* of the individual grafts are then greased with lanolin, or with the following ointment, which was found to be less macerating:

Benzoinated lard	175.00
Lanolin	25.00
Ichthyol	4.00
Silver citrate	1.00

The grafts were then covered with a cage and allowed to dry, exposed to the air, and so treated for the next week whenever possible. Sometimes the sensitiveness and pain after one-half hour's exposure were so great that the whole surface had to be covered with the ointment.

Almost without exception the pain in these ulcerated areas, as well as in the *x*-ray burns which I have excised, has ceased from the time of operation. It is interesting to note that in one instance thick grafts grew even on the base of an epitheliomatous ulcer, but within three weeks became excessively hypertrophic. After subsequent amputation of the finger, sections showed carcinoma invading the bottom of the edematous graft.

Although future events may prove that my treatment of this patient has been too conservative, his present condition would seem to justify it.

Digitized by Google

In order that the abundance of material, which has resulted from all these operations, may prove of value to dermatologists interested in the study of the pathological conditions induced by the *x*-rays, Dr. C. J. White has kindly made a careful examination of all the specimens which have been preserved, and his exhaustive report forms a most valuable addition to my paper.

The clinical appearances of the chronic *x*-ray dermatoses suggest a precocious and extreme senility of the skin; microscopic examination also shows the most extraordinary changes, always of a degenerative character, unequalled in their severity and chronicity by the effects of any other agent.

In view of these facts, and the histories of the 11 cases reported, I think the following conclusions are justified:

1. For the atrophic condition of the skin and the telangiectases, nothing can be done.

2. Hypertrophic changes, keratoses, and warts may with safety be treated in the usual manner. If such treatment fails, excision with or without skin-grafting will probably relieve the pain and result in a cure.

3. Excision and grafting will prove to be the best treatment for recurrent fissures.

4. All ulcerations which, under ordinary treatment, remain open after three months should be thoroughly excised and very carefully examined. The subsequent treatment, to be determined by the result of the microscopic examination, should be skin-grafting, further excision and grafting, or amputation.

5. As the history of almost all of these cases of severe and chronic dermatitis dates back to early exposures, with the protection which our present knowledge demands, it is to be hoped that the number of victims of too enthusiastic work in an untried field will steadily diminish.

6. In the meantime, I have no hesitation in recommending the *early excision of all persistent x-ray ulcerations*, in order that any subsequent malignant degeneration may be prevented.

Digitized by Google

PATHOLOGICAL REPORT, BY CHARLES J. WHITE, M.D.

The pathological report which follows is based upon the study of forty-three microscopic slides presented by Dr. Porter. The sections were already stained, for the most part by the hematoxylin-eosin, iron-hematoxylin, and methylene-blue-eosin methods. It is to be regretted that no fresh material was at hand for the special staining of connective-tissue and elastic fibrils.

The first sections date from July 17, 1902, and were as follows:

Finger of Right Hand. Keratosis moderate. Rete somewhat hypertrophic and shows an increased tendency toward downward proliferation. Corium normal and presents no marked signs of inflammation. The deeper horizontal vessels, however, exhibit serious changes. In places veins appear displaying extraordinary mural thickening. No interior alterations are present beyond a slight enlargement of the cells, but the outer coats are greatly hypertrophied. Here and there arteries are totally obliterated by endothelial overgrowth.

An Ulcerated Area. The rete, where existent, is totally abnormal. The stratum corneum consists of a few lamellæ of non-nucleated cells. The stratum granulosum is absent. The stratum spinosum is made up of greatly dilated cells, the extranuclear protoplasm being much rarefied and the nuclei shrunken, murally placed, or entirely gone. The palisade layer, however, shows comparatively normal elements. Here and there are masses of red blood cells, suggesting golden pigment granules and filling the whole depth of the rete.

As the ulcer is approached the spinous cells show more distinct configuration, but are horizontally elongated and interspersed with erythrocytes.

Corium. Below this abnormal epidermis there are occasional masses of plasma cells, accompanied by a rare mast cell. The papillary and subpapillary vessels are dilated and many are clogged with red cells. Larger, deeper vessels are choked with endarterial masses of nucleated cells. This condition is extraor-

Digitized by Google

dinarily abundant, the lumen of some vessels of great size being entirely obliterated.

Invading the entire corium are polymorphous masses of epithelial cells ranging from small strings to great clumps, with many smaller, epithelial pearls. The epitheliomatous masses are outlined by a limiting band of deeply staining cells. Within these peripheral bands the cells are often oval and greatly enlarged, with correspondingly hypertrophic nuclei containing one or two nucleoli. Some of the cells are really enormous (fusion?), while around them appear epithelial cells whose limiting membranes are indistinct, and whose nuclei have disappeared. The epithelial pearls are large, some of them consisting of a nucleated centre surrounded by fifteen to twenty concentric hyaline rings.

Mitoses are rare, and between these epithelial masses are numerous cells.

From a Finger. For the most part the epidermis is normal, although the rete is somewhat hyperplastic. In one place, *per contra*, the spinous layer has receded to three or four layers of somewhat amorphous cells, illy defined from the underlying corium, and exhibiting deeper proliferation, suggestive of epithelioma, while above a nucleated crust appears.

The corium shows in the middle and lower layers a few highly dilated lymph spaces and some moderately enlarged bloodvessels surrounded by dense plasmomata with an occasional mast cell; while still deeper are seen bloodvessels presenting an obliterating endothelial change, and again others with persistent but distorted lumen and thickened walls surrounded by dense envelopes of connective tissue.

From a Finger. Within the lobules of epithelioma are many large, oval and round, swollen, pale-staining cells—some of great size. The progressive steps toward the formation of pearls can be demonstrated easily. Again, mitoses are rare.

A Finger of the Left Hand (Fig. 3). *Rete.* Where the epidermis is intact there is a marked parakeratosis and acanthosis. The horny layer is decidedly thickened and nuclei persist; the stratum granulosum is absent; the upper layers of spinous cells are flat-

Digitized by Google

tened and elongated and more or less devoid of nuclei, and the whole rete somewhat hyperplastic. In several places the epidermic origin of the epithelioma is plainly manifest and broad masses of tumor cells are seen in direct continuation with the overlying rete.

Throughout the depth of the corium are seen lobules and whorls of epitheliomatous cells, between which the collagenous bundles form a delicate network, in which are lodged masses of mononuclear cells—for the most part plasma cells—and very numerous, small, dilated vessels. Before any degenerative alterations have developed the cells of the outer layers of the lobules retain their prickles undiminished. With the onset of degeneration, however, we note a disappearance of these spongioplastic prolongations and a concentric arrangement of the cells. Within these onion-like lamellæ the cells assume a roundish configuration, with occasional great perinuclear halos, while in the centre of the mass appears a basic-staining substance reminiscent of keratin. These conditions well illustrate the epidermic derivation of the tumor masses by their analogy to the progressive cornification of the normal epidermis.

In other parts of the section the epidermis shows less keratosis, while the rete produces long, finger-like projections into the corium. Finally, in still other areas, there is ulceration. The lowermost layers of the rete alone persist as round or oval, swollen cells; while, again, all signs of the epidermis are wanting and the surface is formed by a highly cellular corium.

The vessels are everywhere dilated. The papillary and subpapillary channels are delicately widened and the interlobular passages show the same condition, while in the non-epitheliomatous parts of the section the deep vessels are very conspicuous, and here and there form great reservoirs, like those seen in cavernous angiomas. These veins do not exhibit dilatation simply, for their walls are manifestly hypertrophic.

Curiously enough, pigmentation, which we associate so strongly clinically with *x*-ray dermatoses, seems to play no role throughout all these sections, and hematin or melanin granules are conspicuously absent.

Digitized by Google

Ulcer—Tip of Third Finger of the Right Hand. This area presents a central ulceration with comparatively normal epidermis on each side. The floor of the ulcer is composed of string-like, serpentine masses of epithelioid cells, groups of erythrocytes, polynuclear leukocytes, and rather inconspicuous bundles of collagen. Lower down the field becomes less troubled. The pus cells and red corpuscles disappear. The epithelioid masses grow less numerous, while mononuclear elements and connective-tissue cells replace them. The epithelioid elements for the most part form worm-like processes; but in places this configuration is lost, branches develop, or irregular masses are produced. These figures are composed of cells exhibiting large, oval or round nuclei, which contain many nucleoli, and are surrounded by meagre protoplasm, with no retaining envelope. Here and there are especially large cells, which seem to be pushing their way through lymph spaces.

From a Finger. Here the epitheliomatous process is young. The epidermis shows a loss of the stratum corneum. The granular layer is practically wanting, save for an occasional attenuated cell with but few granules. The upper layers of the rete are elongated and more or less devoid of nuclei. The germinate cells, on the other hand, are conspicuously numerous, absorb the stains deeply, but show an irregular demarcation from the subjacent corium and exhibit occasional downward buds.

The corium presents dilated subpapillary vessels with hypertrophied endothelial cells, while the deep veins are enormously enlarged with frequent great thickening of their several coats. In the subpapillary layer there are striking masses of plasma cells with infrequent mast cells, especially above the vessels. Here, again, can be seen delicate, spring-like masses of epithelioid cells, which wind through the lymph spaces. Where these masses widen out their component cells display large, swollen nuclei. Evidences of chromatophores, or of free pigment granules, are once more wanting.

Where epitheliomatous changes are absent the connective-tissue nuclei are appreciably elongated and enlarged.

Digitized by Google

Thus far these sections date from the operations of July 17, 1902.

Back of the Right Wrist. December 23, 1903 (Fig. 14). The epidermic structures are normal, with the exception of a slight tendency toward irregularity, where the palisade layer and corium meet, and here certain nuclei are surrounded by clear spaces, while others have dropped out and are replaced by inflammatory cells. The papillary vessels are dilated with hypertrophied endothelium.

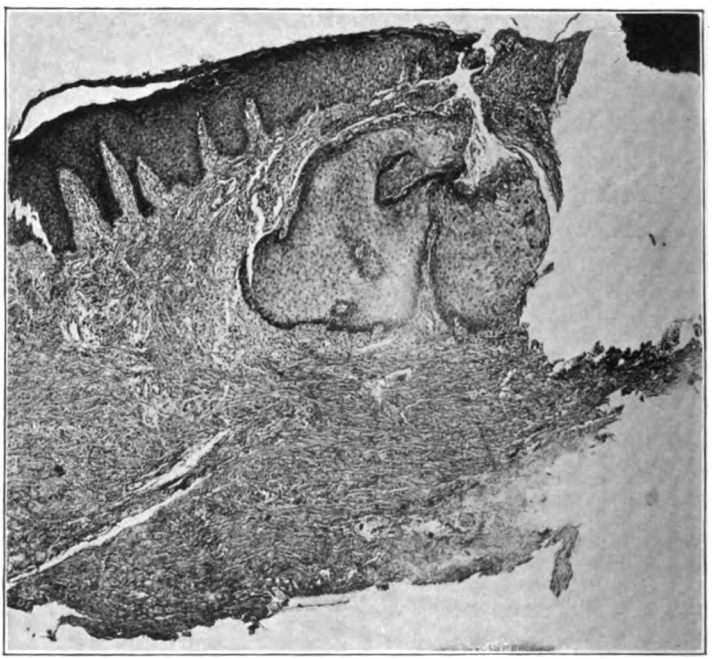

FIG. 14.—December 23, 1903.

The corium is very dense and is filled with mononuclear cells not particularly grouped, but generally distributed.

At the periphery of the section, however, where the section ends abruptly through ulceration (?), there are two lobules of epithelial cells. One suggests the epidermis irregularly cut (cross-section?); the other contains edematous cells, some without nuclei, others swollen with large vesicular nuclei, others containing granules of

Digitized by Google

keratohyalin; in fact, the whole picture is strongly reminiscent of the epidermic changes seen in molluscum contagiosum. The whole structure is surrounded by inflammatory tissue.

Back of Right Wrist. December 23, 1903 (Fig. 15). To one side of the ulcerated area shown in the photograph the epidermis is greatly modified. The palisade layer forms a straight but broken line, owing to the disappearance of the papillæ. The cell nuclei are round or oval rather than elongated, show one or more sharply staining nuclei, and are filled with chromatin granules. The inter-

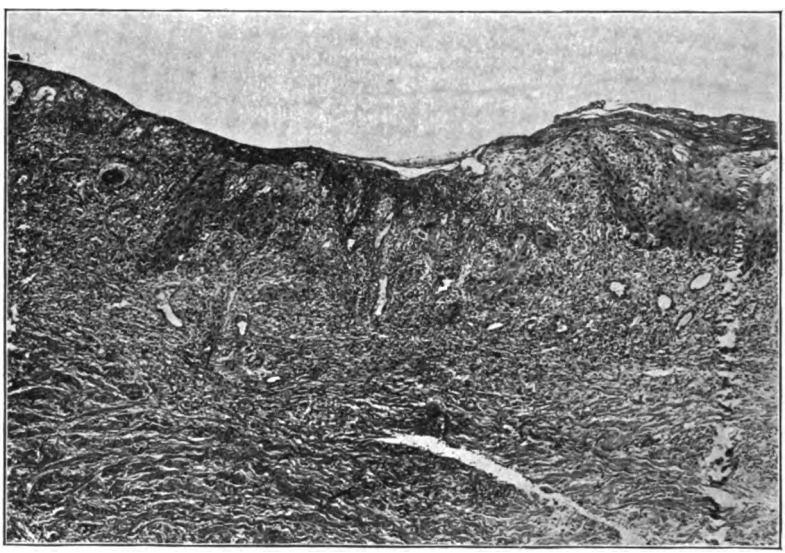

FIG. 15.—December 23, 1903

cellular spaces are irregular and often enlarged. The overlying layers of the rete are thickened and present swollen, edematous, loosely opposed cells, mostly free of nuclei and spines. The granular layer is represented by free keratohyaline granules only, all other evidences of granular cells having disappeared. Lastly, the stratum corneum is composed of many dense lamellæ, with numerous persistent nuclei. Thus the whole epidermis presents acanthosis and parakeratosis of pure type.

In the corium the absence of papillæ has already been alluded

Digitized by Google

to, while the subpapillary vessels are widely dilated and exhibit hypertrophic endothelial cells. Below, the collagen is comparatively normal, save for occasional swollen bundles. Moderately numerous plasma cells and rare mast cells are present, sometimes grouped about a distended vessel. Finally, deep down in the corium appear prominent veins, now endothelially, now totally thickened.

The ulcerated portion (Fig. 15) presents a complex picture of masses of polynuclear leukocytes and red cells lying in a medium coarse reticulation, with interspersed large dilated vessels filled with erythrocytes and coagulated fibrin, and with occasional processes of epithelial cells, with grossly vesicular nuclei growing in



FIG. 16.—December 23, 1903.

from the sides or persisting as remnants. Below these abnormal elements lies a floor of thickened, rather anuclear collagenous bundles.

Base of First Finger of Right Hand. December 23, 1903 (Fig. 16). This represents a scar tissue of considerable thinness. The epidermis consists, for the most part, of parallel bands of dense nucleated corneous lamellæ, with occasional layers of rather amorphous, homogeneous, quasi-rete cells, containing infrequent round or oval nuclei, surrounded by empty spaces. The germinate layer is represented by horizontally lying cells with flattened nuclei.

Even here the epidermis shows an effort toward downward proliferation, foretelling future epitheliomatous growth.

Digitized by Google

The corium shows an absence of papillæ. The subpapillary layer is not as compact as one would suppose, and its meshes are strewn with plasma cells, as seen in Fig. 16. There are frequent epitheliomatous cell nests, some solid and normal, others presenting varying degrees of central degeneration. In one (lying nearly centrally in the illustration) there is an outer ring of fair-sized, numerous, darkly staining nuclei, separated by a clear zone (artefact?) from the inner, lamellated, flatly nucleated layers



FIG. 17.—December 23, 1903.

which, in their turn, envelop an almost homogeneously degenerated centre containing an occasional giant nucleus and scattered nuclear debris and two large cysts partly filled with granulated protoplasm and mononuclear leukocytes.

The base is composed of practically normal fibrous tissue and the deep vessels, when present, exhibit no marked mural changes.

Middle Finger of Left Hand. December 23, 1903. The tissue here is composed of a dense mass of fibrous elements devoid of all

Digitized by Google

epithelial structures and free from vessels. It consists of practically structureless collagen on which lie small, round, solid-staining nuclei, the exact nature of which it is difficult to discern. In the deeper portion of the section the fibrous bundles form a reticulated mesh devoid of nuclei. The whole picture presents an extraordinarily blank mass.

Base of Third Finger of Right Hand. December 23, 1903. Fig. 17 illustrates well the conditions present.

To one side, an ulcerated surface of thickened collagenous material, supporting numerous, many-sized, mononucleated cells and small and large interstices containing erythrocytes, with occasional whorls of edematous and degenerated epithelial cells.

Where the epidermic covering is present, the various layers are much altered. The rete shows an irregular base with marked tendency toward downward proliferation. The upper strata are emphatically hypertrophied, while their component cells have lost their prickles and tend to coalesce, so that cell boundaries are gone; nuclei are swollen or absent and protoplasm is cloudy. The granular layer is represented for the most part by free keratohyaline granules. The stratum corneum is hyperplastic and nucleated. Again, a marked picture of acanthosis and parakeratosis. Pigment is conspicuous by its absence.

The corium exhibits only occasional papillæ, which are filled with highly dilated vessels. The skeleton of the skin is composed of dense, rather anuclear bundles. Deeper vessels, when present, show considerable thickening of their walls and constriction of their lumen and are surrounded by plasma and other mononuclear cells.

Base of Little Finger of Left Hand. December 23, 1903 (Fig 18). The process represented here is one of hyperkeratosis. The corium is dense. Vessels are slightly dilated and encompassed by extravasated mononucleated cells. Papillæ are insignificant. The rete is somewhat thickened for this part of the body, but otherwise normal. The granular layer is manifestly hyperplastic, and consists of five to six rows of large, swollen cells with somewhat blunted ends and filled with masses of keratohyaline granules. The stratum lucidum is suggested, but shows no traces of eleidin. The

Digitized by Google

stratum corneum is conspicuously thickened and composed of layer upon layer of waving, horny cells.

Tip of Middle Finger. September 19, 1904. A very complex and irregular picture. The epidermis is mostly gone, the few surviving vestiges being quite atypical. The corium is totally abnormal, and it is difficult to orientate one's self. The upper layers are filled with dense masses of plasma cells and with sparsely scattered lymphocytes. Small dilated vessels with extraordinarily vesicular nuclei

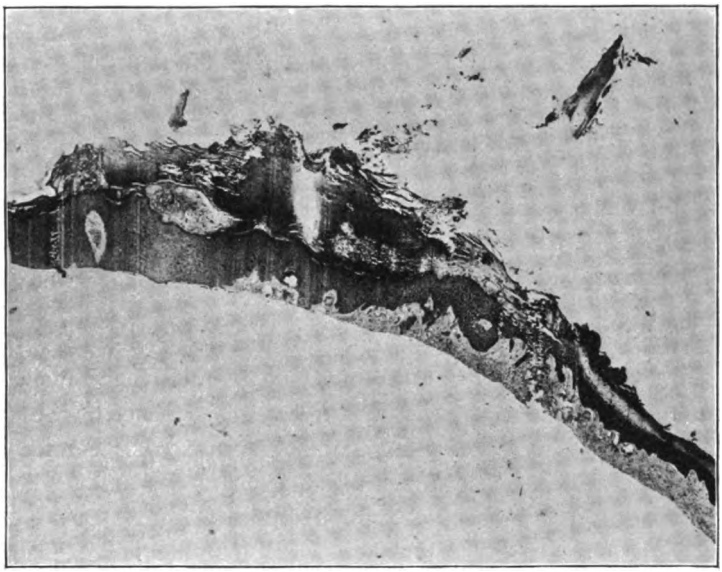

FIG. 18.—December 23, 1903.

abound, choked with red cells and occasional lymphocytes. The supporting fibrous tissue is in places dense, in others delicately reticulated, the intensity of the plasmomata corresponding directly with the density of the collagen. Here and there are small lobules of epithelial cells, occasionally whorls, and, more rarely, branching tubules. All three forms exhibit absence of prickles and presence of highly vesicular cells containing one or two nucleoli and dense chromatin granules. The whorls and the tubules show a tendency toward central hyaline degeneration. When visible, through com-

Digitized by Google

parative freedom from inflammatory invasions, the fibrous tissue shows a moderate proliferation of its nuclei.

Base of Middle Finger. September 19, 1904. Great hyperplasia of the rete is the distinguishing feature here. For the most part the change is purely one of overgrowth in the depth of the layer. The cells are normal, although somewhat edematous, and there is marked intercellular invasion of leukocytes. Here and there, however, the cellular elements show loss of prickles, vacuolization, and tendency toward homogeneity. The stratum granulosum is represented mostly by free-lying keratohyaline granules, with occasional areas of partly developed granular cells. The horny layer is compact, but otherwise normal.

The dividing line between epidermis and corium is so indefinite, owing to the great overgrowth of the rete and the irregularity of the cut, that it is difficult to ascertain the presence or absence of papillæ. There are numerous foci of snared-off epithelial clusters. The corium is dense and interspersed with numerous plasma cells, especially in the subpapillary layer.

Keratosis from the Dorsal Base of the Middle Finger of the Right Hand. This region presents an epidermic picture somewhat similar to the last, but here one finds the additional presence of a hyperplastic horny layer containing some nuclear cells. Again, the demarcation between corium and epidermis is well marked, and the palisade layer more normal. Papillæ are present and hold dilated vessels—in one instance the whole papillary space is occupied by a vessel whose wide lumen is partially filled with lymphocytes, polynuclear leukocytes, erythrocytes, and granular or reticulated fibrin. The corium presents the condition so frequently described in these sections, *i. e.*, dense collagen with dilated vessels and extravasated mononuclear cells.

Tip of the Little Finger. September 19, 1904. Another picture of parakeratosis and acanthosis, with absence of papillæ and dense infiltrated corium.

Ulcer on Back of Left Hand. October 16, 1904. A complicated structure. The epidermis is entirely gone and the corium contains many polymorphous epithelial lobules and whorls, super-

Digitized by Google

ficial dilated vessels blocked with red and white cells, and innumerable endothelial and mononuclear and polynuclear elements. The epithelial whorls and lobules consist, in the majority of instances, of spine-bearing cells, and present all stages of degeneration, even to cystic spaces containing chromatin granules and reticulated or granular protoplasmatic debris.

The underlying corium is composed of dense fibers with elongated and enlarged nuclei, and the deeper vessels are murally thickened.

Keratosis of the Right Wrist. October 16, 1904. Once more conditions now so familiar in this series of sections. Here one finds a hyperplastic rete whose upper layers are edematous and degenerated, a total absence of granular cells and even independent granules, and an enormously overgrown horny layer bearing nucleated scales and leukocytic crusts.

Papillæ are insignificant. Subpapillary vessels slightly dilated. Collagen delicate in structure and supporting some mononuclear extravasated cells.

Sections from five other excised portions of this same date show pictures presenting the various characteristics, which have marked those previously described and need not be detailed again.

Graft upon Middle Finger of Left Hand. October 16, 1904. The artificial epidermic covering is, to all intents and purposes, normal, but in one portion of the section the insidious process has redeveloped, and below the rete one finds the now familiar epithelial lobules with central hyaline degeneration.

Keratosis from Forehead. December 27, 1904. A newly invaded field. The section illustrates almost perfectly the epidermic characteristics of the sole of the normal foot. The rete is somewhat thickened, the cells of the upper transitional layers more or less vesicular and thrown up into jagged summits and depressions into which dovetail layer upon layer of normal horny cells. The corium, however, shows evidences of considerable inflammation. Vessels are dilated and plasmomata are frequent. Sweat and sebaceous glands, hitherto not observed in these sections, are present in great abundance, and exhibit no marked deviation from the normal.

Digitized by Google

Forehead. April 20, 1905. The intervening five months have wrought a great change. In the present section ulceration has occurred and at the epithelial edge the cells of the upper layers of the rete are flattened and contain perinuclear halos or empty nuclear spaces; all semblance of granular cells has vanished, and a thin, parakeratotic horny layer is present. The lower layers of the rete are running riot. They have overcome the normal resistance of the corium and are proliferating enormously into the subjacent structures. Individual cells are often of enormous size and have become amorphous, anuclear, swollen masses of protoplasm. In other areas large vesicular nuclei are present, with but scant surrounding protoplasm. Cellular invasion is absent.

Farther down in the corium, hugely swollen, anuclear bundles of collagen and some veins of extraordinary thickness and jagged, slit-like lumen appear. These unusual collagenous fibers would suggest an incipient colloid degeneration. The sweat glands remain strangely unaffected in the midst of these contiguous pathological structures.

Hand. November 8, 1905. These sections are cut largely in so horizontal a plane that it would be injudicious to judge of the epithelial changes. There is, nevertheless, marked hyperplasia of the rete, with occasional loss of nuclei, especially in the germinate zone, general cloudiness of the cells, and some intercellular leukocytic invasion. In places all vestiges of normal metamorphosis from rete to horn cells have gone and the free surface of the skin forms a chaotic mass.

The subpapillary layers, which alone are present, show fine reticulation, supporting normal vessels and a general plasmomatic infiltration.

Keratosis from the Hand. November 8, 1905. Here one has an ideal representation of a papillary and verrucous nevus. The rete is cast in individually rounded lobes formed by the wide and finely separated ascending papillæ, and in places these lobes strongly suggest the lower rete conformation of molluscum contagiosum. In these lobes the rete is hyperplastic and fairly normal, although perinuclear halos are common. The granular cells also exist in

Digitized by Google

great numbers, and one can count ten to twelve perfectly developed layers, while above, before keratinization has been completed, as many more layers, half granular, half keratinous, appear. Above these increased strata lie row upon row of typical horn cells. Thus far the description has related to the interpapillary lobes, but, as is the rule in nevous pictures, the rete and granular layers surmounting the papillæ do not present these hyperplasias, but appear in comparatively normal amounts.

The papillæ are proportionately narrow, but project far into the epidermis, in some instances to extraordinary distances. As is customary in this class of nevi, the papillary and subpapillary vessels are slightly dilated and accompanied by a moderate number of mononucleated cells, which lie between and under the epidermic lobes. The rete is practically normal.

Ulnar Side of the Forefinger. November 8, 1905. A mild degree of the preceding process, partly purely keratotic and partly slightly papillomatous.

Ulceration of Finger. November 8, 1905. An intensely interesting picture of multiform and generalized degeneration which has affected practically all the various structures of the skin.

The epidermis is represented by remnants of previous downshoots from the rete, which persist as barely recognizable, swollen, amorphous, acid-staining protoplasm, with occasional vesicular nuclei.

The papillæ of the corium are gone and the subpapillary layer holds numerous moderately dilated vessels with infrequent, cloudy vesicular endothelial cells, and with swollen lymphocytes, a few pus cells and reticulated fibrin in their channels. Collagen appears as straight, edematous bundles, between which extend chains of oblong plasma cells and more irregularly distributed lymphocytes. These plasma cells are histologically noteworthy, for one seldom sees such well-defined examples with their eccentrically placed, round nuclei bearing symmetrically arranged, peripheral nucleoli.

These rows of alternating plasma cells and swollen collagen are interrupted by frequent vessels whose walls are cloudy and whose nuclei are vesicular and often of great size. Below there are iso-

*

Digitized by Google

lated or grouped masses of wavy or serpentine basic-staining elastic fibers (elacin), which lie between the fibrous bundles or form large, solid areas free from collagen.

Outer Side of Forefinger. November 8, 1905. Another ulcerated surface, disclosing many of the attributes of the previous section but not containing so many interesting histological features.

Back of Right Hand. March 16, 1906. In this section there are stretches of epidermis and of ulceration. Where the former is present there is some tendency toward hyperplasia of the rete, while the stratum granulosum is absent and the stratum corneum is represented by a thin, homogeneous mass. Underneath, the corium is normal except for universally dilated vessels surrounded by plasmomata.

Where the epidermis is gone the corium is filled with circular or polymorphous lobules of epithelial cells, which show no tendency toward degeneration. Multiple dilated vessels with lumens choked with red cells lie between these epitheliomatous masses and scattered universally throughout the depth of the derma are many mononucleated or polynucleated inflammatory cells.

First Finger of Left Hand. March 16, 1906. A pathological condition similar to the last, but here the epidermis is intact, exhibiting hyperplasia of the rete and of the horny layer, both of which are infiltrated with many leukocytes, usually of the pustular type. Here, also, evidences of downward proliferation of the rete are visible. Finally, there is abundant hemorrhage everywhere.

Tip of Third Finger. March 16, 1906. This piece of skin is free from epitheliomatous changes. For long stretches the upper layers of the epidermis are wanting, while the corium exhibits in all parts many dilated vessels and multitudinous plasma cells.

Excision November 4, 1906. This section, the last in this long series, exhibits undiminished evidences of epithelioma.

The horny layer is practically non-existent; the granular layer is normal. The rete is, in places, thickened, and displays numerous infiltrating leukocytes, and at its germinate layer evinces signs of downward-penetrating proclivities. Papillæ are present and bear

Digitized by Google

slightly dilated vessels. The subpapillary layer is delicately reticulated and holds frequent plasmomata and distended vessels containing fibrous meshes and occasional polynuclear leukocytes. Just below this level lies another series of plasma-cell masses whose characteristics are strikingly visible, and immediately subjacent are extensive areas of epithelial whorls and lobules, surrounded by still further plasma cells.

The outer lamellations of these whorls show well-differentiated prickle-bearing cells; but within lie degenerated, puffed cells, free from prickles, and, at times, from cell boundaries, containing frequently giant nuclei or no nuclei at all and more mitotic figures than in the previous pathological history of the case. Finally, in the very centre of some of the whorls are found large cysts partially filled with coagulated fibrin, giant nuclei, and abundant chromatic remains. Where these cysts appear the epithelial masses are more "pearly" than elsewhere.

This, then, is the detailed description of the pathological side of this discouraging history, and it is distressing to find at the end of this long series a slide exhibiting the most active phases of the disease.

One who has read the histological minutiæ of the case will be struck, presumably, by the manifold varieties of the pathological structures. Almost every known phase of epidermic deviation has been encountered and the cellular, vascular, and protoplasmic alterations and degenerations have been most varied and interesting. The one striking omission in the case has been the unexpected absence of all pigmentary signs, especially when one remembers how prominent a clinical feature pigmentation is in *x*-ray dermatitis and its epitheliomatous sequelæ.

Digitized by Google

Digitized by Google

INDEX.

ADDRESS of the President, 1
Allen, Dudley P., teaching of surgery, 1
Allis, Oscar H., congenital dislocation of hips, 311
Andrews, E. Wyllys, clinical experience with the law of accelerating risk in cancer, 196
Anesthesia, spinal, 15
Augustana Hospital, final results in one hundred and sixty-four cases of carcinoma of breast in, 152

BARNEY, J. DELLINGER, results of operations for cancer of breast at the Massachusetts General Hospital, 80
Blastomycosis, 386
Brain surgery, some considerations in regard to, 400
Breast, cancer of, 61, 80, 103, 112, 116, 126, 133, 138, 152, 166, 174, 180 187
Brewer, George Emerson, etiology of certain cases of left-sided intra-abdominal suppuration (acute diverticulitis), 258, 274
  spinal anesthesia, 31
Bristow, A. T., cancer of head and neck, 236
  spinal anesthesia, 29
Burrell, Herbert L., cancer of breast, 212
  ischemic paralysis, 291

CABOT, ARTHUR TRACY, carcinoma of breast. 103
Cancer of breast, 61, 80, 103, 112,116, 126, 133, 138, 152, 166, 174, 180, 187
  radical operations for cure of, 61
  of head and neck, surgical treatment of, 231
Carcinomata, multiple, following chronic *x*-ray dermatitis, 418
Carson, N. B., cancer of breast, 211
Carwalt, W. H., cancer of breast, 210
Clinical experience with the law of accelerating risk in cancer, 196
Coley, William B., cancer of breast, 205
  case of oidiomycosis with rapid generalization, the early lesions simulating giant-celled sarcoma, 386
Congenital dislocation of hips, 311
Continuous passive hyperemia in delayed union of fractures and in hastening the consolidation of fractures, 33
Crile, George W., further consideration of the surgical treatment of cancer of head and neck, 231

Digitized by Google

Curtis, B. Farquhar, cancer of breast, 210
ischemic paralysis, 291
Cushing, Harvey, acquired diverticulitis of large intestine, 272
surgical treatment of facial paralysis and of trigeminal neuralgia, 275, 282
Cyst of spleen, non-parasitic, 366

Dennis, Frederic S., report of end results, following operations for cancer of breast, 116
Diverticulitis, acute, 258
Diverticulum ilei as a cause of complete intestinal obstruction, 255

Eliot, Ellsworth, Jr., acquired diverticulitis of large intestine, 270
cancer of breast, 208
subcutaneous rupture of spleen, 336
End results following operations for carcinoma of breast, 116, 126, 133, 138, 166, 174, 180, 187
Estes, W. L., acquired diverticulitis of large intestine, 271

Facial paralysis, surgical treatment of, 275
Ferguson, Alexander H., cancer of breast, 204
Fibroid tumor of nasopharynx, 293
Finney, J. M. T., new method of rhinoplasty by means of one of the fingers, 44
Fitz, Reginald H., acquired diverticulitis of large intestine, 271
Freeman, Leonard, desirability of early operations upon the nerves in ischemic paralysis, 284, 292

Gerrish, Frederic Henry, diverticulum ilei as a cause of complete intestinal obstruction in a manner hitherto undescribed, 255, 273
Giant-celled sarcoma, 386
Gibson, C. L., prostatectomy, 229
Giffin, H. Z., acquired diverticulitis of the large intestine, 237
Gigantism and asymmetry, 40
Greenough, Robert B., results of operations for cancer of breast at the Massachusetts General Hospital, 80

Halsted, William Stewart, results of radical operation for cure of cancer of the breast, 61
treatment of posterior capsule of thyroid gland, 60
Head, cancer of, surgical treatment of, 231
Hips, congenital dislocation of, 311
Huntington, Thomas W., cancer of breast, 204
report of a case of non-parasitic cyst of spleen, 366
spinal anesthesia, 28

Ischemic paralysis, early operations upon nerves in, 284

Jacobson, Nathan, end results following operations for carcinoma of breast, 166
Johnson, Robert W., resection of the sound femur in gigantism and asymmetry, 40
Jonas, A. F., end results in operation for cancer of breast, 180
Jones, Robert, delayed union of fractures, 39

Digitized by Google

KAMMERER, FREDERICK. fibroid tumor of the nasopharynx removed by temporary resection of both superior maxillæ, 293
Kidney, rupture of, 371
Küster, Professor, cancer of breast, 201
spinal anesthesia, 15, 32

LEFT-SIDED intra-abdominal suppuration, etiology of certain cases of, 255

MACDONALD, WILLIS G., spinal anesthesia, 31
MacLaren, Archibald, prostatectomy, 222
Massachusetts General Hospital, results of operations for cancer of breast at, 80
Mayo, C. H., treatment of the posterior capsule of the gland in thyroidectomy, 52
Mayo, William J., acquired diverticulitis of the large intestine, 237, 273
ischemic paralysis, 291
Meyer, Willy, end results following operations for carcinoma of breast, 126
spinal anesthesia, 30
Mixter, S. J., acquired diverticulitis of large intestine, 270
cancer of breast, 212
facial paralysis, 281
Moore, James E., cancer of breast, 202
Multiple carcinomata following chronic *x*-ray dermatitis, 418
Munro, John C., prostatectomy, 229
report of one hundred cases of carcinoma of breast, 112

DE NANCRÈDE, C. B. G., acquired diverticulitis of large intestine, 272
cancer of breast, 203
Nasopharynx, fibroid tumor of, 293
Neck, cancer of, surgical treatment of, 231
Neilson, Thomas R., rupture of kidney, 371
Neuralgia, trigeminal surgical treatment of, 275
Non-parasitic cyst of spleen, 366

OCHSNER, A. J., final results in one hundred and sixty-four cases of carcinoma of breast at the Augustana Hospital, 152
Oidiomycosis with rapid generalization, 386
Oliver, John Chadwick, end results in operations for carcinoma of breast, 174

PARALYSIS, facial, surgical treatment of, 275
ischemic, early operations upon nerves in, 284
Pilcher, Lewis Stephen, end results following operations for carcinoma of breast, 133
Porter, C. A., case of multiple carcinomata following chronic *x*-ray dermatitis, 418
Posterior capsule of the glands, treatment of, in thyroidectomy, 52
Powers, Charles A., cancer of breast, 212
primary sarcoma of prostate, 213
rhinoplasty, 51
Prostate, primary sarcoma of, 213
Prostatectomy, 222

Digitized by Google

RANSOHOFF, JOSEPH, very late recurrences after operation for carcinoma of breast, 187
Resection of the sound femur in gigantism and asymmetry, 40
Rhinoplasty by means of one of the fingers, 44
Roberts, John B., cancer of breast, 203
continuous passive hyperemia in delayed union of fractures and in hastening the consolidation of fractures, 33
gigantism and asymmetry, 43
Rodman, William L., cancer of breast, 206
Rupture of kidney, 371
of spleen, 336

SARCOMA, giant-celled, 386
primary, of prostate, 213
Schmieden, Dr., spinal anesthesia, 29
Simmons, Channing C., results of operations for cancer of breast at the Massachusetts General Hospital, 80
Spinal anesthesia, 15
Spleen, cyst of, 366
rupture of, 336
Starr, Allen, facial paralysis, 281
Subcutaneous rupture of spleen, 336
Surgery, brain, some considerations in regard to, 400
teaching of, 1

TEACHING of surgery, 1
Thyroid gland, treatment of posterior capsule of, 52
Tracy, Martha, case of oidiomycosis with rapid generalization, the early lesions simulating giant-celled sarcoma, 386
Trigeminal neuralgia, surgical treatment of, 275

VANDER VEER, ALBERT, cancer of head and neck, 236
end results in operation for carcinoma of breast, 138
Varix, aneurysmal, 300
Vaughan, George Tully, acquired diverticulitis of large intestine, 272
aneurysmal varix, 300

WEEKS STEPHEN H., cancer of breast, 207
facial paralysis, 282
some considerations in regard to brain surgery, 400
White, C. J., case of multiple carcinomata following chronic *x*-ray dermatitis, 418
Wilson, Louis B, acquired diverticulitis of the large intestine 237, 273

X-RAY dermatitis, chronic, 418

Digitized by Google

Digitized by Google

Digitized by Google

Digitized by Google

Digitized by Google

Digitized by Google

3 2044 102 959 848

Digitized by Google